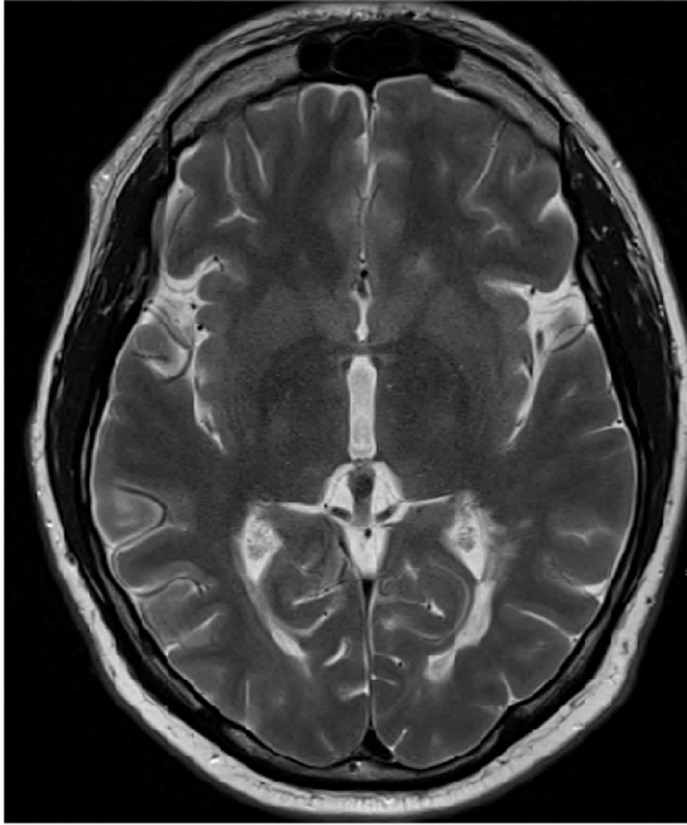


## Appendix 1: Supplemental figure



Axial  $T_2$ -weighted image at the level of the third ventricle showing normal appearance of the inferior aspect of the basal ganglia in a baseline magnetic resonance image.