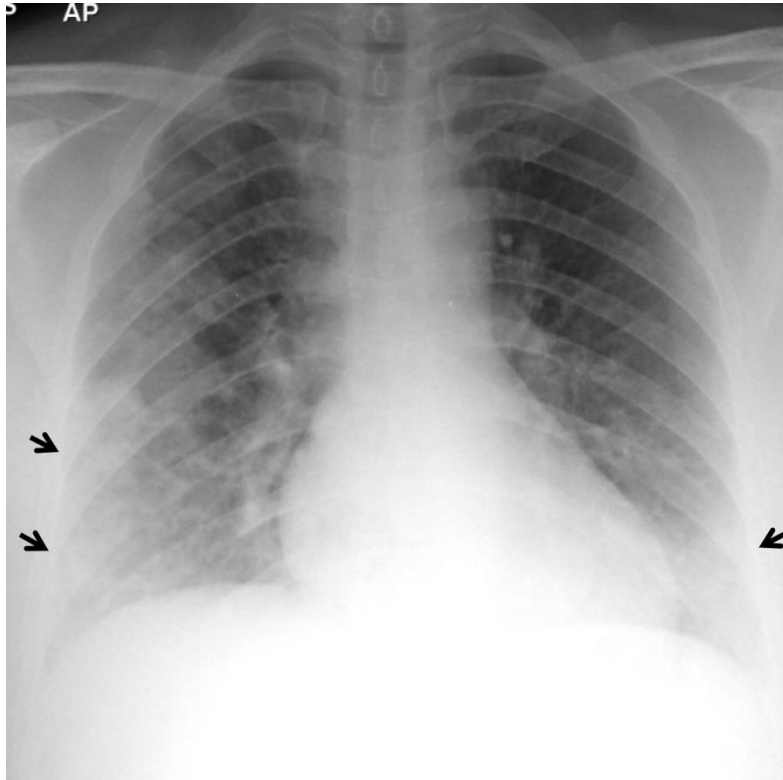


## Appendix 1 (as supplied by authors)



Chest radiograph of a 49-year-old woman with coronavirus disease 2019 (COVID-19) showing bilateral patchy airspace opacities (arrows) in a predominantly basal and peripheral distribution.