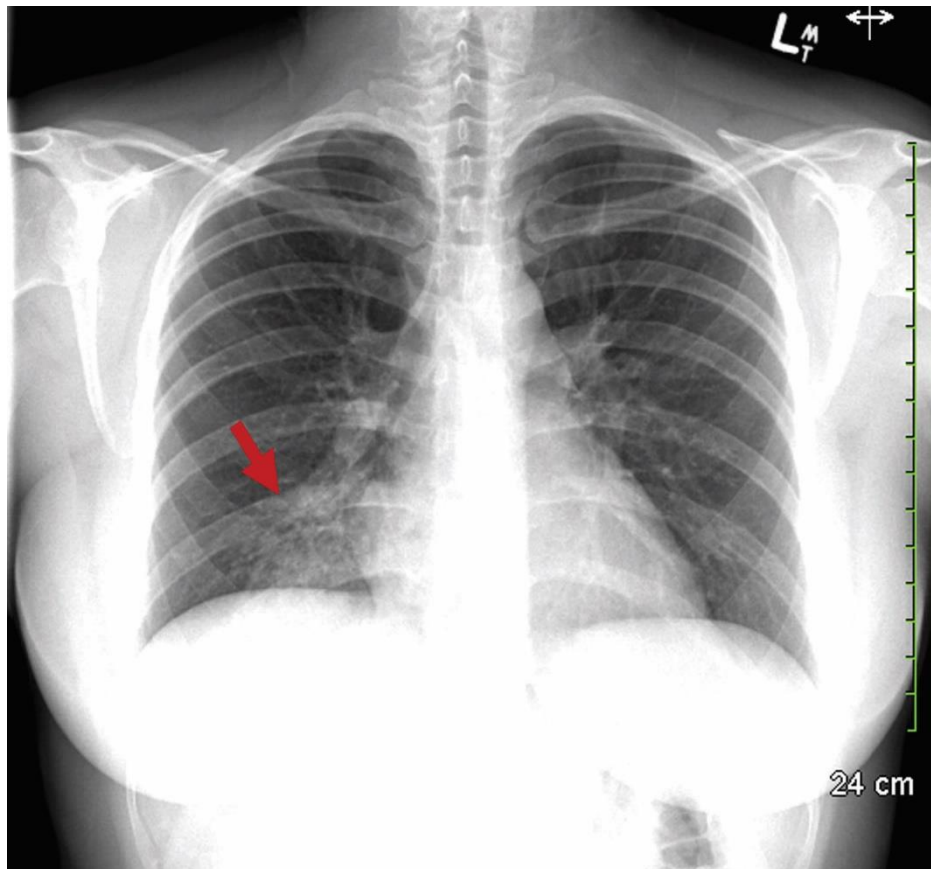


Appendix 1 (as supplied by the authors): Posteroanterior chest radiograph of a 34-year-old woman at the time of initial presentation with cough and generalized malaise. A right lower lobe infiltrate is present (red arrow), which was later determined to be secondary to *Mycoplasma pneumoniae* infection following a positive result of polymerase chain reaction testing of a nasopharyngeal swab.



Appendix to: Bau JT, Cooper CL. Erythema multiforme major associated with *Mycoplasma pneumoniae* infection. *CMAJ* 2019. doi: 10.1503/cmaj.190850.

Copyright © 2019 The Author(s) or their employer(s).

To receive this resource in an accessible format, please contact us at cmajgroup@cmaj.ca.