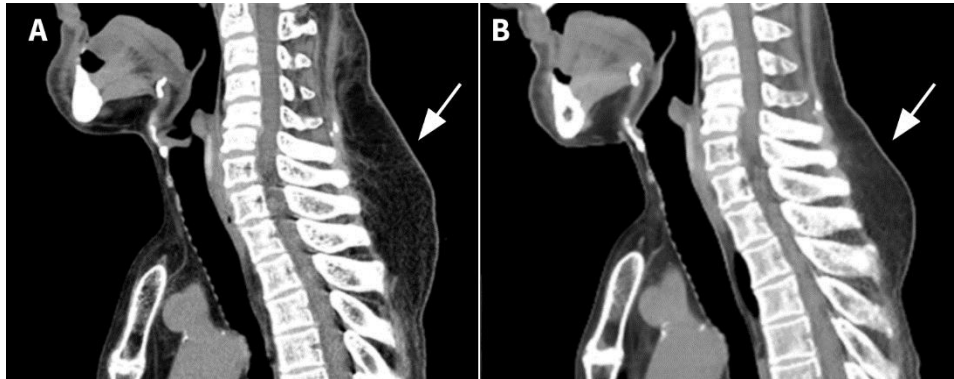


Appendix 1



Computed tomography scans of a patient with Madelung disease (sagittal view). The arrows show the size of the fat mass at A) the patient's initial visit and B) reduced 6 months after moderation of alcohol intake.