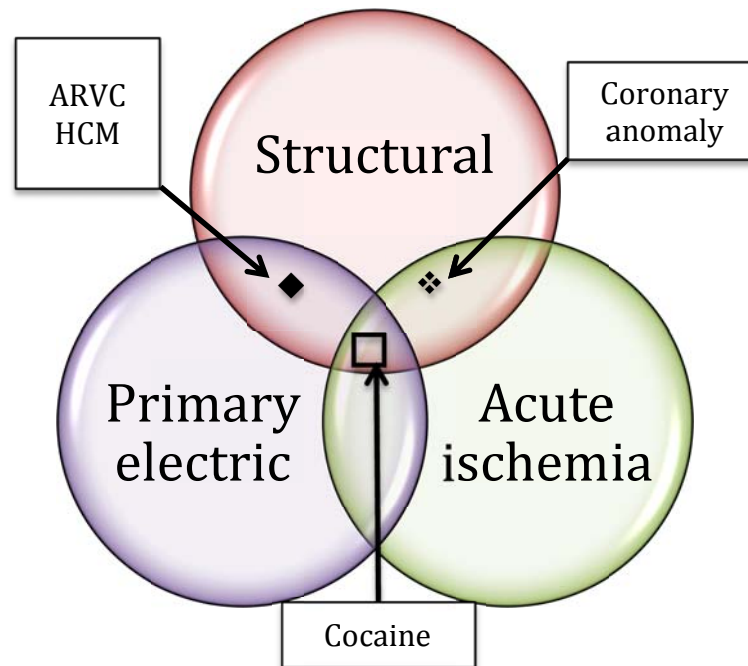


**Appendix 1 (as supplied by the authors):** Interplay among various causes of sudden cardiac death. ARVC = arrhythmogenic right ventricular cardiomyopathy, HCM = hypertrophic cardiomyopathy.



Appendix to: Moayed Y, Kumareswaran R, Dorian P. A 26-year-old competitive soccer player with syncope. *CMAJ* 2015. DOI: 10.1503/cmaj.141140.