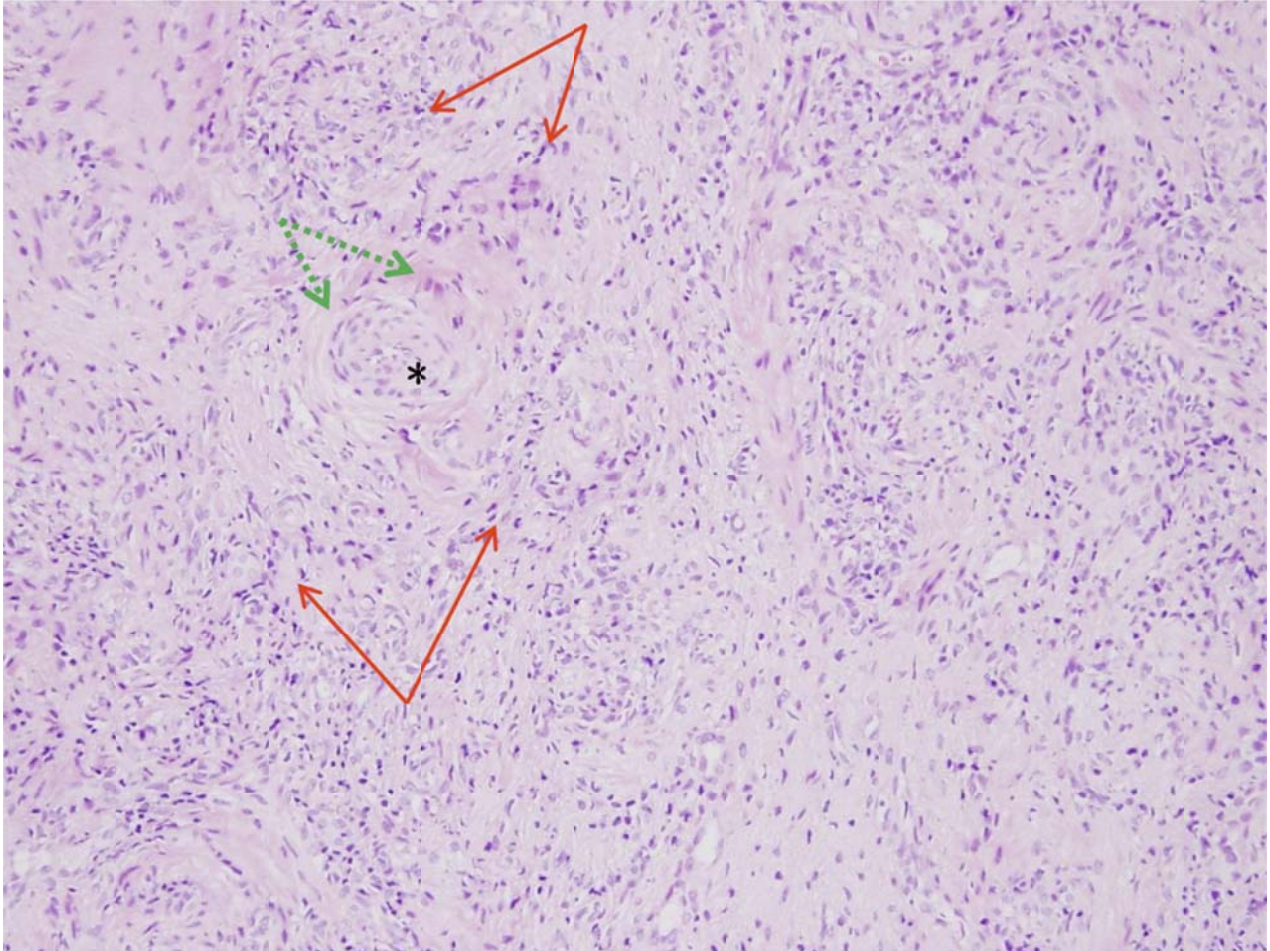


Appendix 1: A microphotograph of a biopsy sample of the sinonasal mucosa of a 63-year-old woman showing fibrinoid vasculitis (green arrows) and histiocytic proliferation surrounding the vessels (red arrows), with inflammatory cell infiltration in the vascular wall (*). These findings are compatible with a diagnosis of Wegener granulomatosis. Hematoxylin and eosin stain (original magnification x 400).



Appendix to: Kuo C.-Y., Wang C.-H. Wegener granulomatosis: changes in the sinonasal mucosa. *CMAJ* 2014. DOI: 10.1503/cmaj.131881.