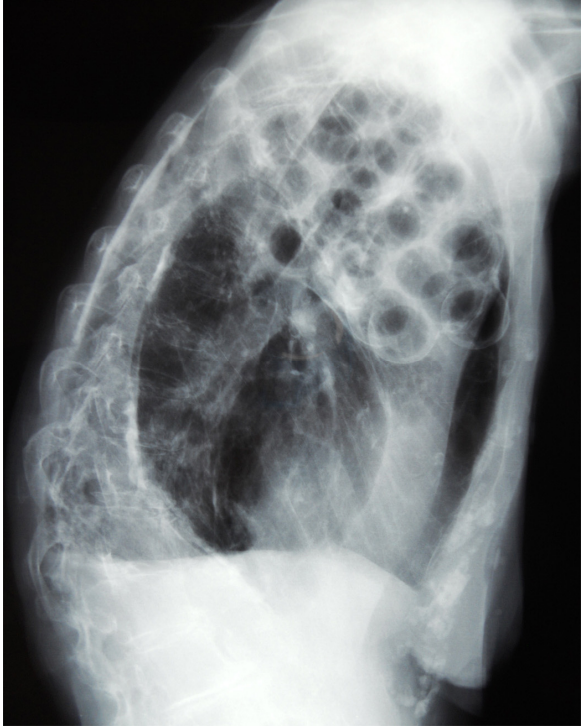


Appendix 1: Radiographic images of the chest of an 84-year-old woman who, in 1951, had undergone plombage for pulmonary tuberculosis. (A) Lateral radiograph showing radiotransparent balls at the left apex, compressing the left upper lobe, and calcified pleural fibrosis at the left base. (B) Computed tomographic scan showing a calcified shell at the periphery of the radiotransparent balls.

A



B

