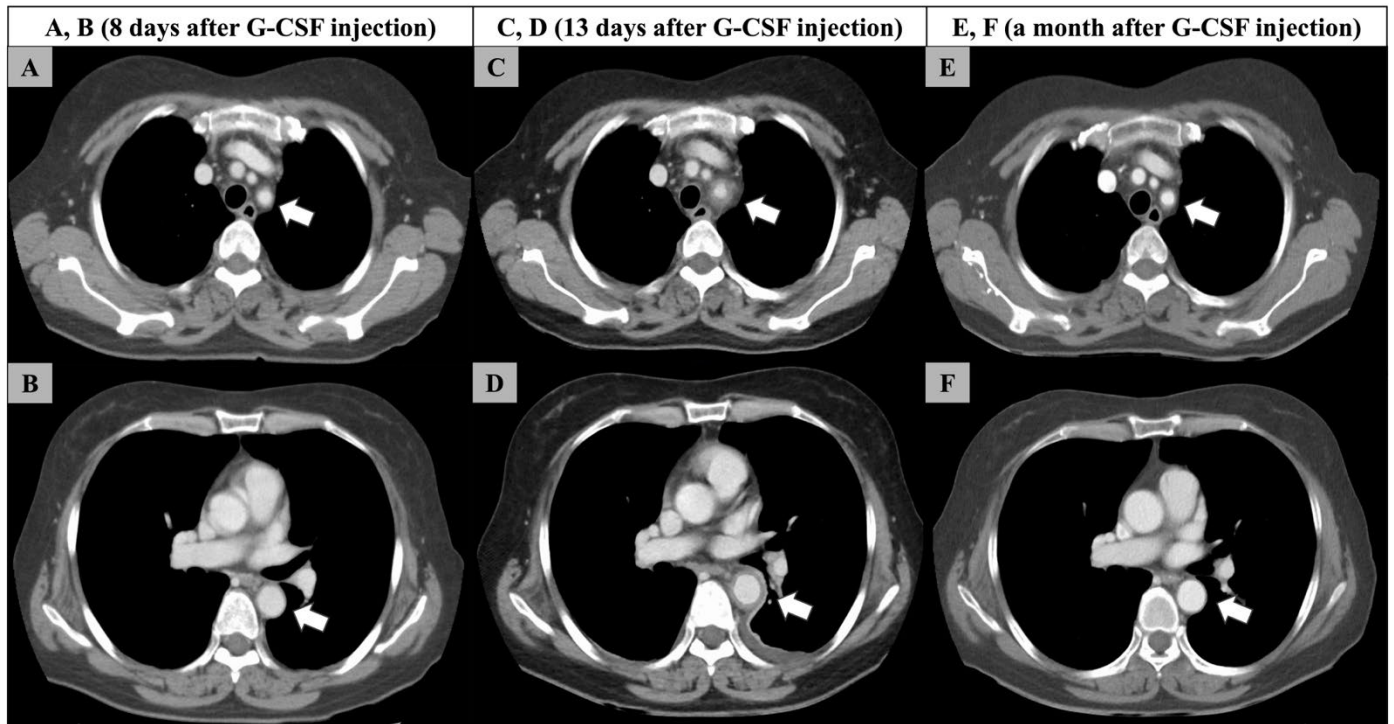


1 **Appendix 1**



2

3 **Appendix Figure Caption**

4 (A, B) The aortic wall was within normal limits on a contrast-enhanced computed tomography scan performed on day
5 8 after granulocyte colony-stimulating factor administration. (C, D) There was marked circumferential wall thickness
6 in the left subclavian artery and descending thoracic aorta on a contrast-enhanced computed tomography scan 5 days
7 later. There was left-sided pleural effusion probably due to aortic inflammation. (E, F) The wall thickness of the vessels
8 had returned to normal a month later.