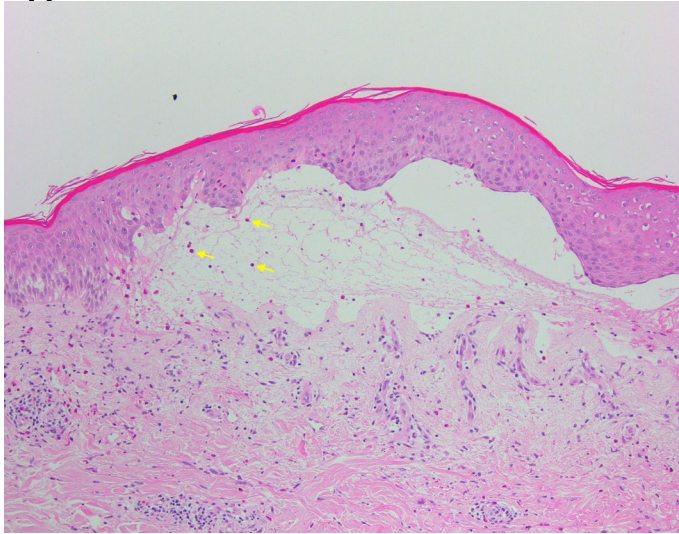


## Appendix 1



**Appendix 1.** Skin biopsy showing subepidermal blister formation with eosinophils (arrows) within cleft.