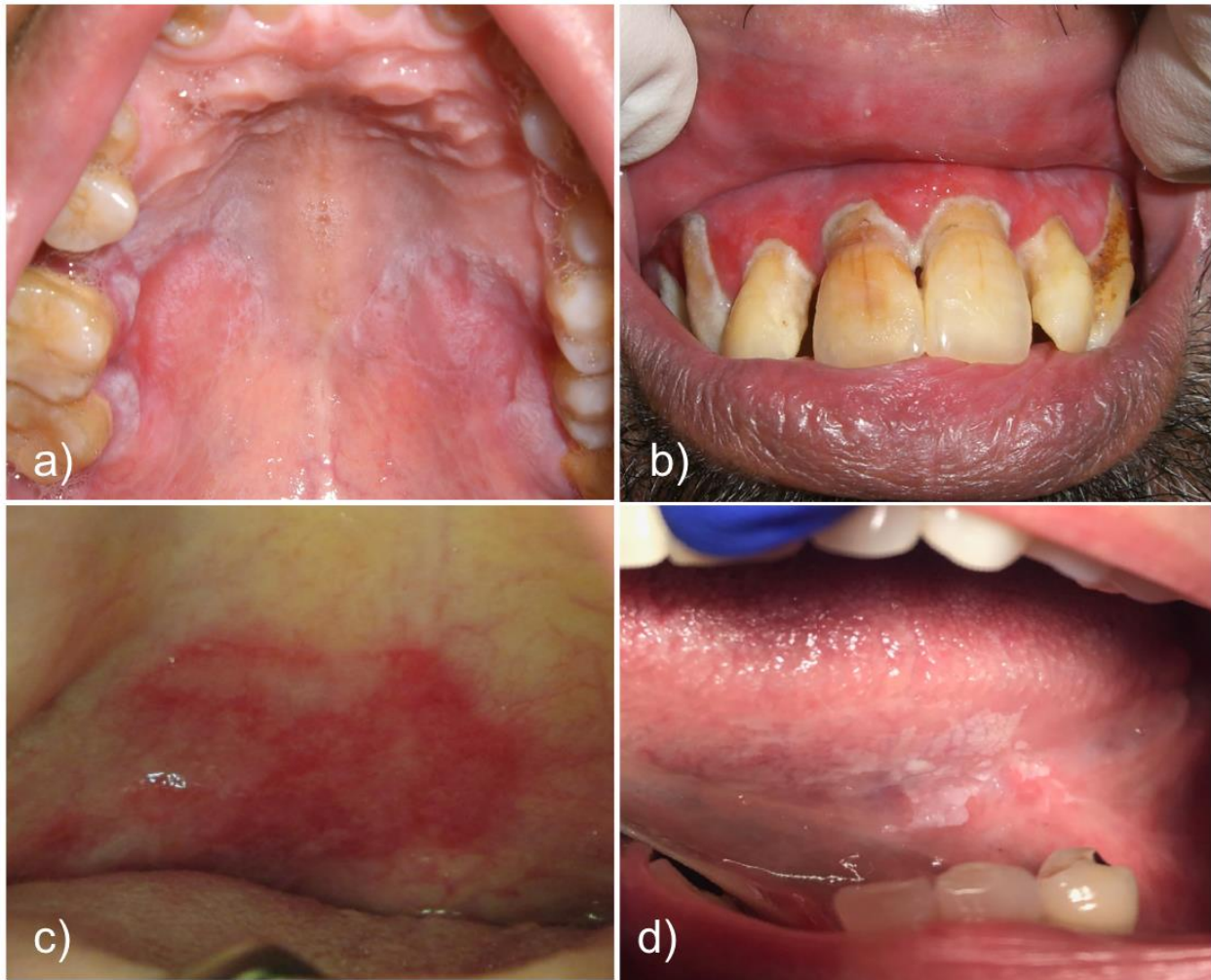


Appendix 1 (as supplied by the authors)



Appendix. a) Palatal reticular oral lichen planus demonstrating bilateral nature and characteristic lacy striae. b) Gingival atrophic lichen planus complicated by poor oral hygiene. Erythema extends beyond the teeth, differentiating this from plaque-related gingivitis. c) Erythroplakia on the palate. d) Leukoplakic lesion on the left lateral tongue.

*Photographs provided by Dr. Hagen Klieb

Written patient consent obtained for all photographs.