
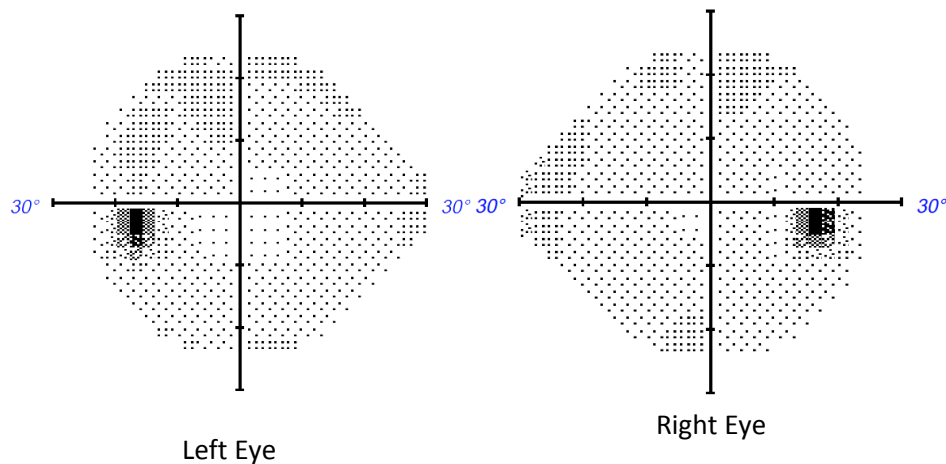


Appendix 1 (as submitted by the authors): Supplementary Figure



Supplementary Figure 1: Automated Humphrey visual field test in a 48-year-old woman with relative afferent pupillary defect showing diffuse vision loss in her left eye (left) and superotemporal defect in her right eye (right). These grey scale plots are a graphical representation of regions of visual field loss. Regions of decreased sensitivity are depicted by darker shades. The right eye visual field also shows the physiologic blind spot.



Supplementary Figure 2. The above images are examples of normal automated Humphrey visual field tests of each eye. The darker shaded areas in each visual field represent the normal physiologic blind spots.