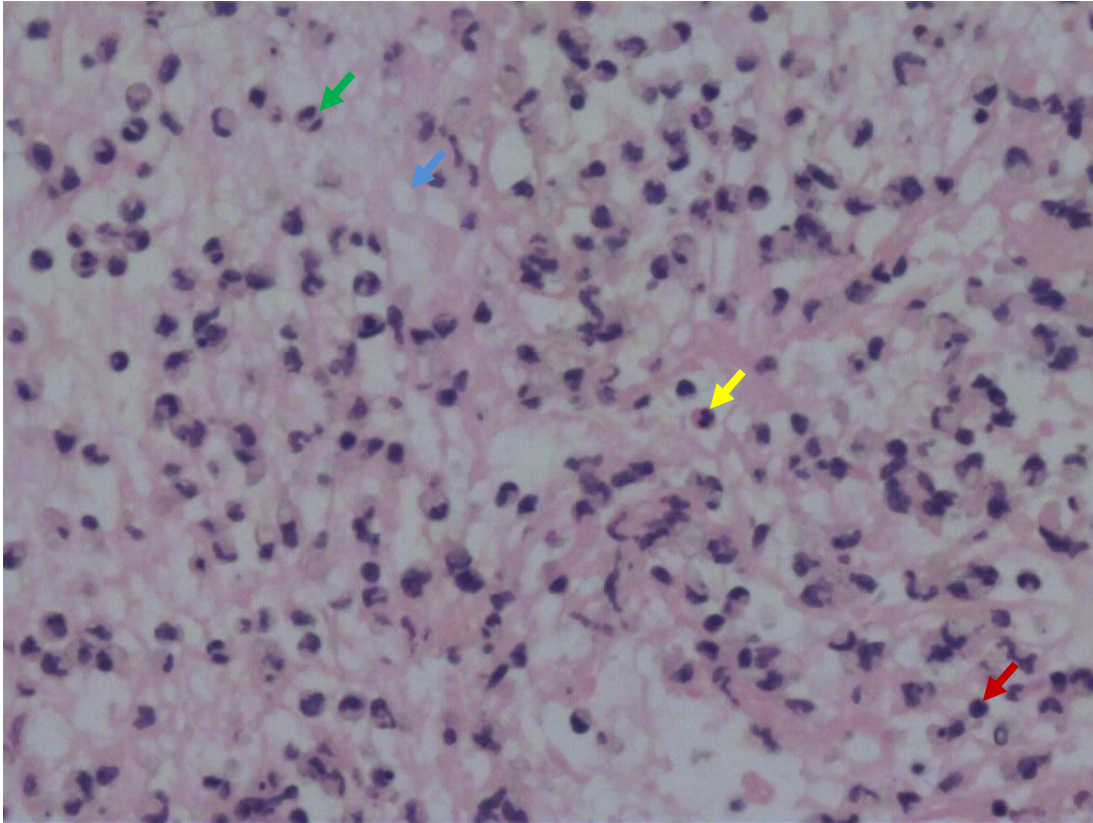


## Appendix 1



Histopathologic examination showed that the cast specimen was composed of fibrinous exudates (blue arrow) and entrapped inflammatory cells, mainly neutrophils (green arrow), macrophages (yellow arrow) and lymphocytes (red arrow) (hematoxylin and eosin stain,  $\times 200$ ).