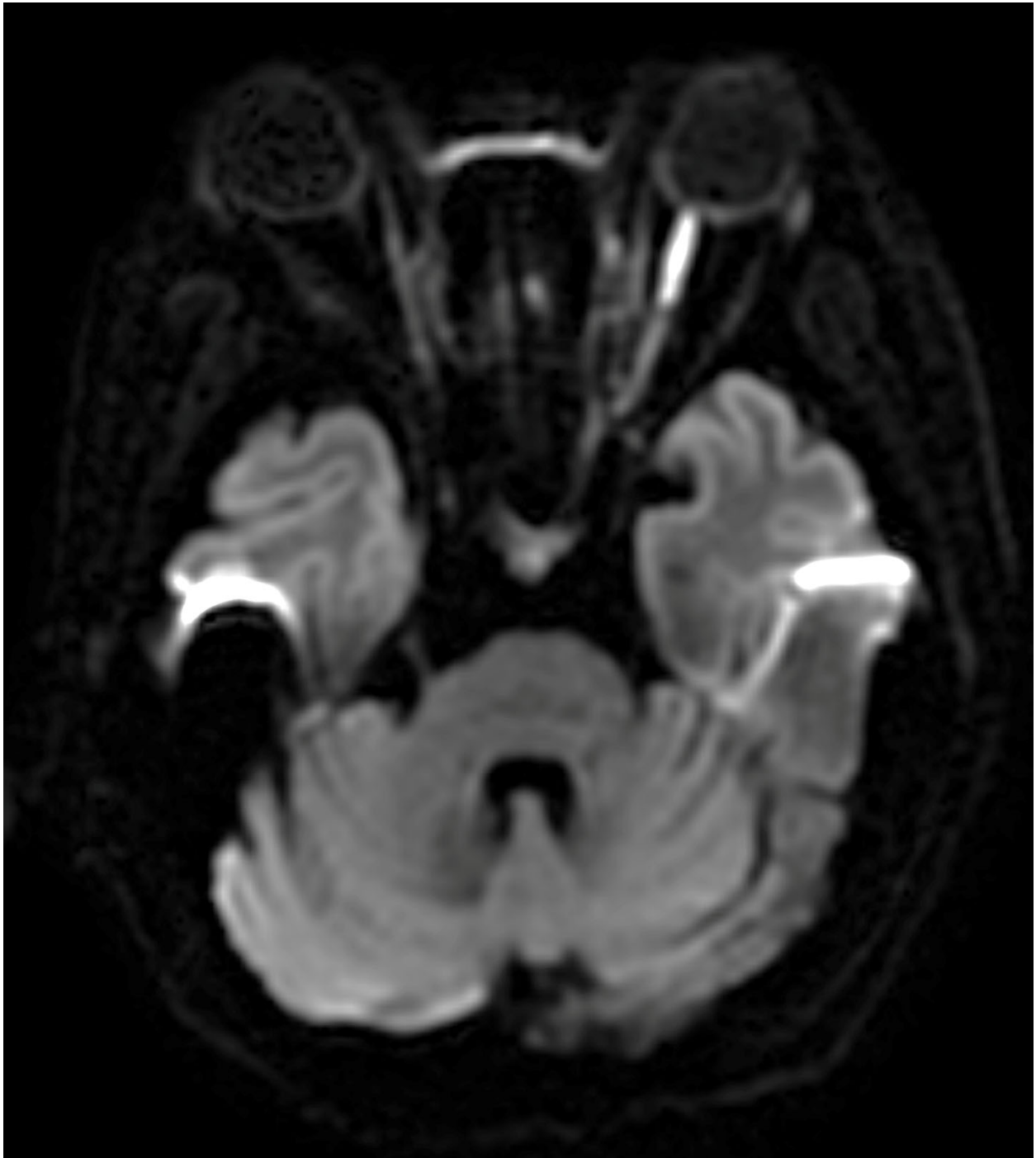
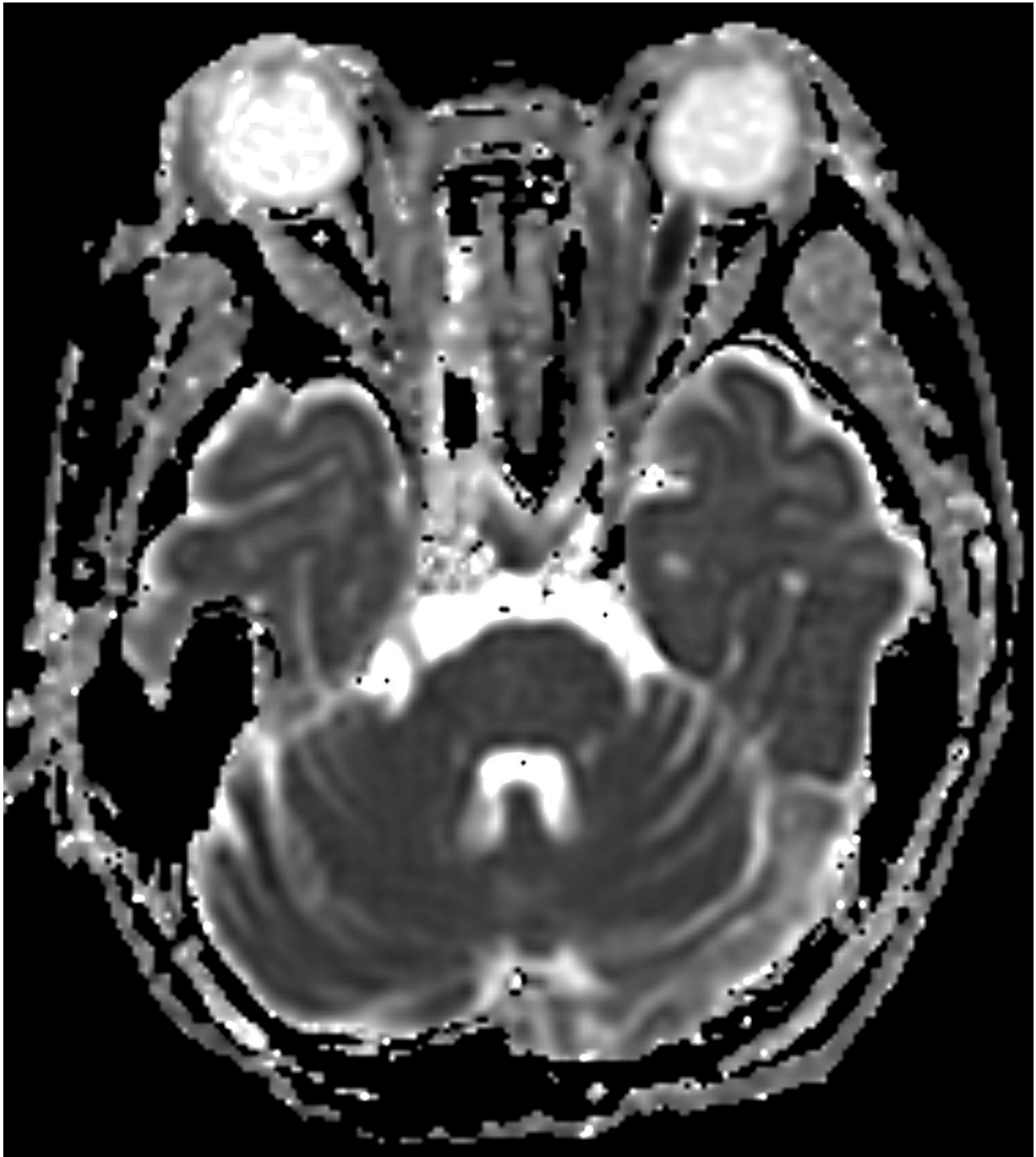

Appendix 1A (as submitted by the authors): Imaging



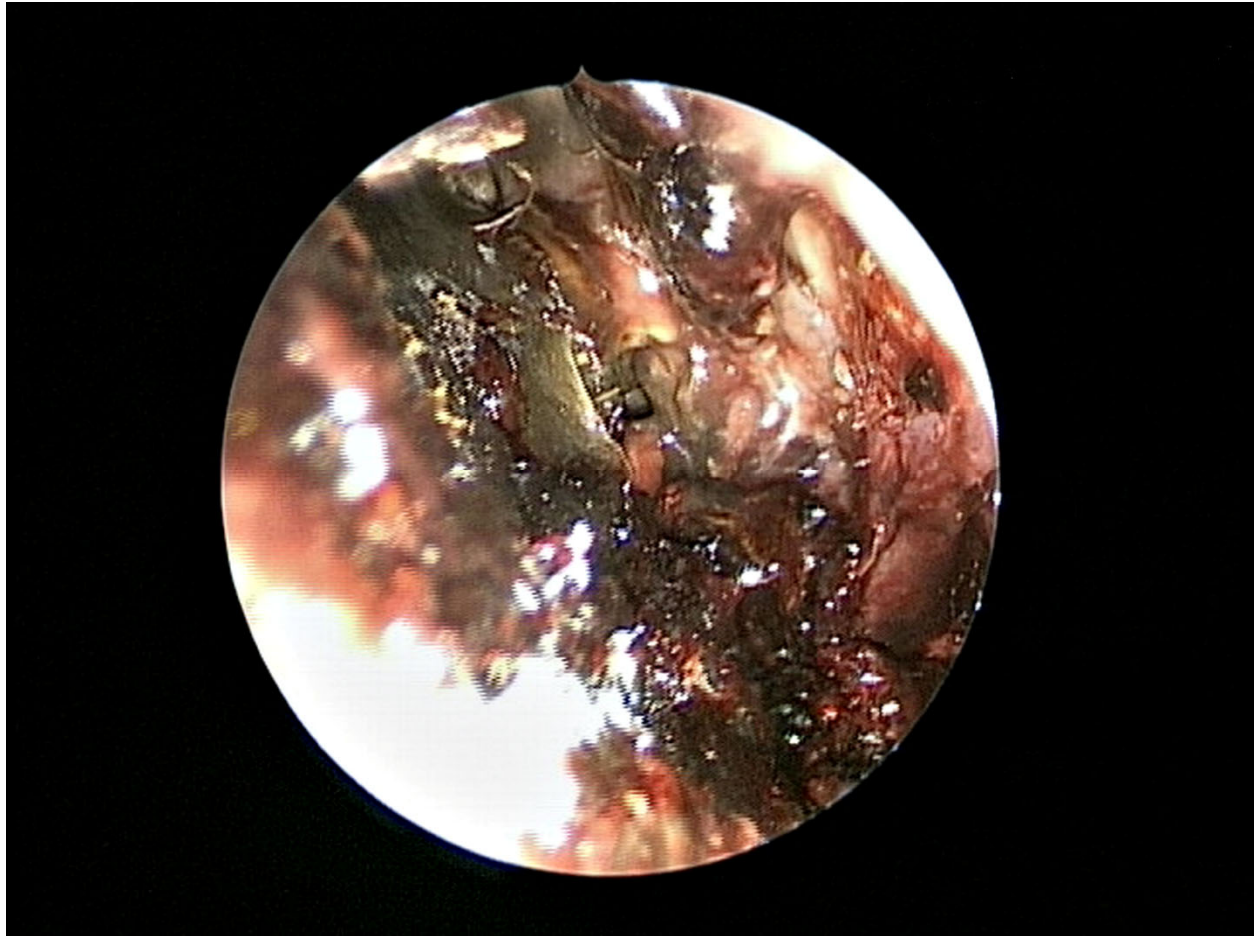
Diffusion-weighted image of the brain shows higher signal intensity along the left optic nerve than the right.

Appendix 1B



Apparent diffusion coefficient map shows hypointense signal along the left optic nerve.

Appendix 1C



Eschar formation over the left nasal cavity found during operation.