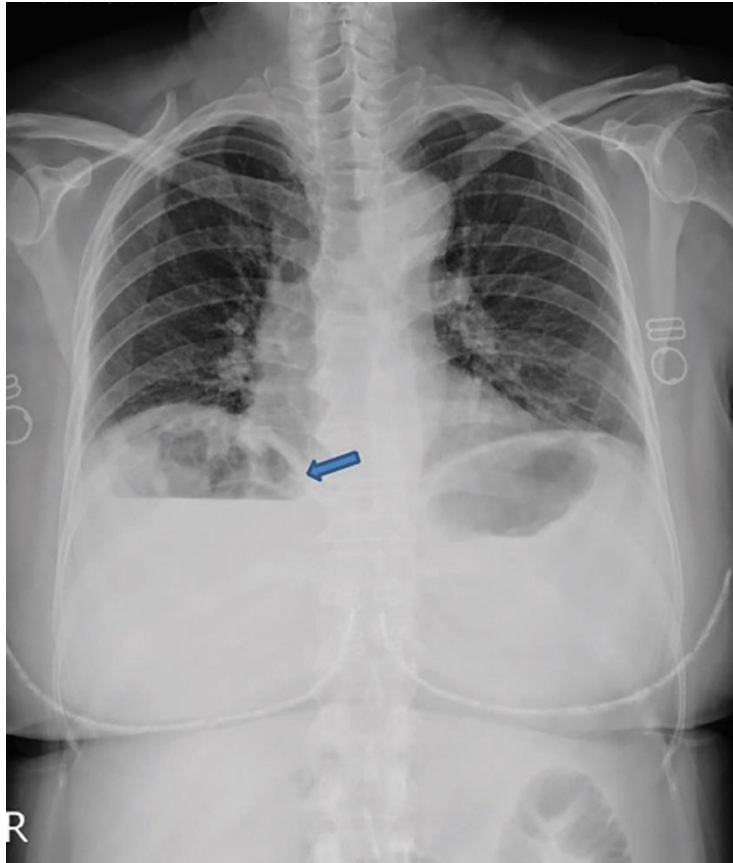


Appendix 1



Chest radiograph showing a semi-oval lesion with air-fluid level lesion over right subphrenic region (arrow). (Note: in some emergency departments in Taiwan, removal of underwear is not required for patients in critical care.)