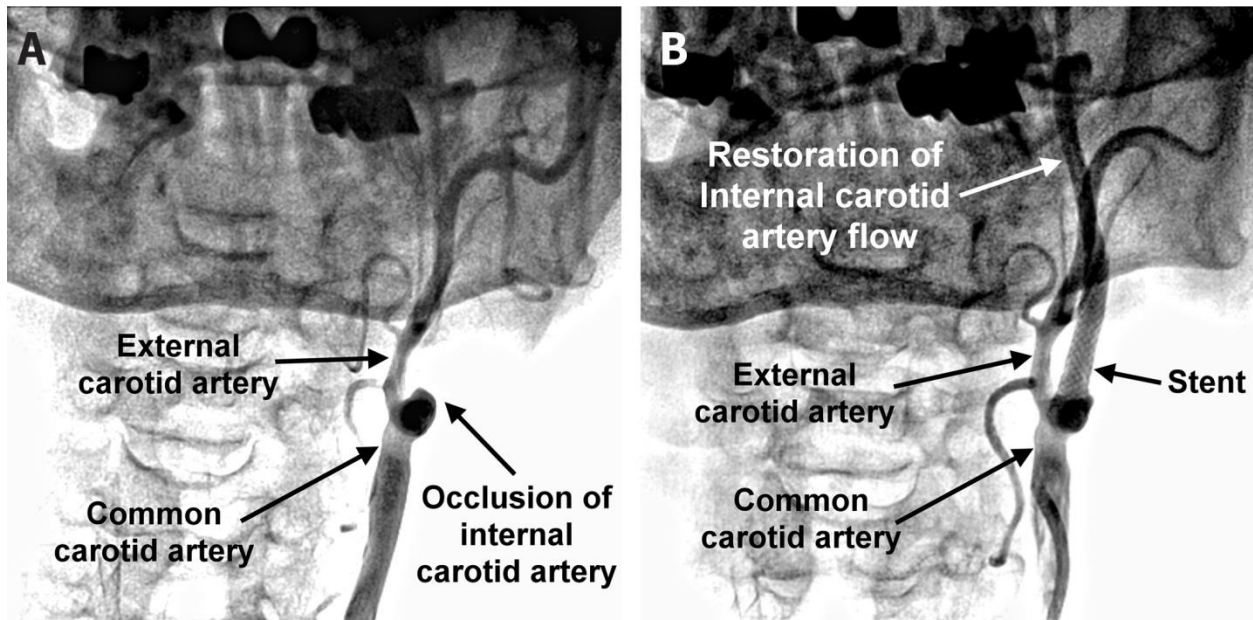


Appendix 1 (as supplied by the author): Ocular ischemic syndrome



(A) Carotid angiography showing total occlusion of the left internal carotid artery. (B) Blood flow of left internal carotid artery restored after subsequent angioplasty with stenting.