

CLINICAL IMAGES

Herniation through the broad ligament

Shahzeer Karmali MD, Robert K. Zurawin MD, Vadim Sherman MD

A healthy 35-year-old, multiparous woman presented to the emergency department with nausea, vomiting and a painful, bloated abdomen. On examination, the patient was afebrile and passing flatus. She had a distended abdomen that was silent and tympanic, with mild tenderness in the lower left quadrant. The results of basic laboratory investigations (i.e., complete blood count, electrolyte panel) were normal. Computed tomography showed dilated loops of distal small bowel in the lower abdomen consistent with a partial obstruction of the small bowel. A diagnostic laparoscopy showed an internal herniation of the small bowel through a 5-cm defect in the broad ligament, between the round ligament and left adnexa (Figure 1A). After reduction of the herniated bowel, the broad ligament was cut to prevent recurrence.

First reported in an autopsy series in 1861 by Quain,¹ herniation through a defect in the broad ligament remains an uncommon cause of intestinal obstruction, accounting for about 4%–7% of internal hernias.² Cilley classified broad-ligament defects in three categories (Figure 1B).³ Our patient had a complete fenestration through the broad ligament, or type 1 defect, which is the most common type.

Defects of the broad ligament may be either acquired or congenital. Trauma resulting from pregnancy or delivery, pelvic inflammatory disease or surgery is an acquired cause. In nulliparous patients, such defects may result from spontaneous rupture of cystic structures within the broad ligament that are thought to be congenital remnants of the mesonephric or müllerian ducts.³ Herniation or obstruction of the small bowel is the most commonly reported complication. Ureteric herniation with obstruction⁴ and ovarian torsion with gangrenous strangulation within defects of the broad ligament have also been reported.⁵

From the Division of General Surgery (Karmali), Department of Surgery, University of Alberta, Edmonton, Alta.; and the Divisions of General Surgery (Sherman) and Obstetrics and Gynecology (Zurawin), Micheal E. DeBaakey Department of Surgery, Baylor College of Medicine, Houston, USA

CMAJ 2009. DOI:10.1503/cmaj.090667

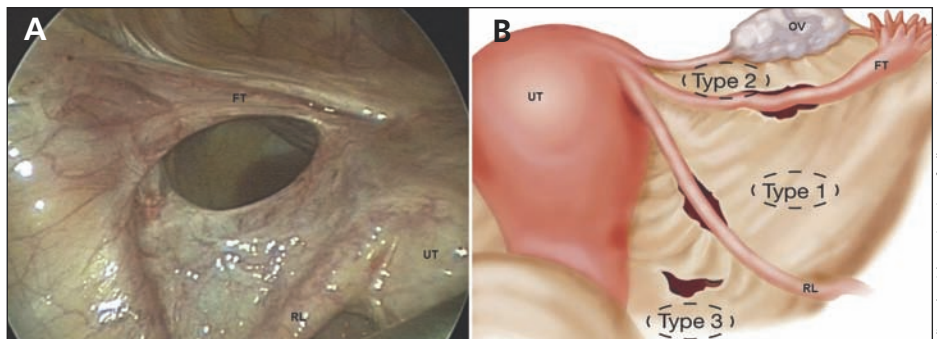


Figure 1: (A) Five-centimetre defect of the broad ligament, between the round ligament and left adnexa, in a 35-year-old woman with obstruction of the small bowel caused by internal herniation. (B) Illustration of the broad ligament, showing locations of associated defects. Note: FT = fallopian tube, OV = ovary, RL = round ligament, UT = uterus.

The management of internal hernia through the broad ligament is two-fold. First, using the Trendelenburg position, the incarcerated contents are gently reduced, and, if necessary, non-viable bowel is resected. Second, to prevent recurrent small-bowel obstruction, the defect can be closed (i.e., using a clip or suture)⁶ or the broad ligament can be completely divided.⁷

The possibility of internal herniation through a defect in the broad ligament should be considered in women presenting with obstruction of the small bowel when more common causes (i.e., adhesions, neoplasms, groin hernias) have been excluded.

This article has been peer reviewed.

Competing interests: None declared.

REFERENCES

1. Baron A. Defect in the broad ligament and its association with intestinal strangulation. *Br J Surg* 1948;36:91-4.
2. Chapman VM, Rhea JT, Novelline RA. Internal hernia through a defect in the broad ligament: a rare cause of intestinal obstruction. *Emerg Radiol* 2003;10:94-5.
3. Cilley R, Poterack K, Lemmer J, et al. Defects of the broad ligament of the uterus. *Am J Gastroenterol* 1986;81:389-91.
4. Nackley AC, Yeko TR. Ureteral displacement associated with pelvic peritoneal defects and endometriosis. *J Am Assoc Gynecol Laparosc* 2000;7:131-3.
5. Bates GJ, Bennett IC, Furnival CM. A strangulated hernia through the broad ligament causing ureteric obstruction. *J R Coll Surg Edinb* 1983;28:335.
6. Varela GG, López-Loredo A, García León JF. Broad ligament hernia-associated bowel obstruction. *JSL* 2007;11:127-30.
7. Takayama S, Hirokawa T, Sakamoto M, et al. Laparoscopic management of small bowel incarceration caused by a broad ligament defect: report of a case. *Surg Today* 2007;37:437-9.