

A young adult with first-episode psychosis: when to consider anti-*N*-methyl-D-aspartate receptor encephalitis

Candace Marsters MD PhD, Svetlana Iskhakova MD, Laura Powe MB BCh BAO, Adrian Budhram MD

■ Cite as: *CMAJ* 2023 March 6;195:E330-2. doi: 10.1503/cmaj.220938

A 22-year-old woman presented to the emergency department after her roommate reported behaviour that included throwing kitchen items, urinating on the floor and threatening suicide. The patient reported having used alcohol, cannabis and psilocybin that evening. Her medical history was remarkable for a suspected mature cystic ovarian teratoma, which was being monitored by ultrasound, and for possible depression, for which she had reportedly been prescribed fluoxetine several months previously. However, it was unclear whether she had ever taken the fluoxetine, and she was taking no prescription medications at the time of her presentation.

We monitored her on the psychiatric unit and treated her for possible substance-induced psychosis with olanzapine. Her symptoms improved after several days and we discharged her. She re-presented to the emergency department 10 days later after assaulting her friend and crashing a car. She had manifestations of active psychosis, including hallucinations, delusions and confabulation. She again reported using alcohol, cannabis and psilocybin, although her accounts of substance use were inconsistent. History from friends did not reveal previous psychotic episodes. Because there is an association between ovarian teratoma and anti-*N*-methyl-D-aspartate receptor (NMDAR) encephalitis, we considered encephalitis as a possible cause of her first-episode psychosis.

When the neurology service assessed the patient on day 4 of admission, she was initially withdrawn but ultimately agreed to participate. She reported increased substance use for the last 6 months, although not in the week preceding admission, and said that low mood was a reason for the increased use. Her Montreal Cognitive Assessment score was within normal limits (28/30) and we identified no focal deficits. Her electrolyte, liver enzyme, creatinine, thyroid-stimulating hormone, HIV and syphilis serology levels were normal, as well as her urine toxicology screen, except for the detection of cannabinoids. Computed tomography of her abdomen and pelvis showed a fat-containing, rounded left ovarian lesion measuring 2.1 cm, in keeping with a mature cystic teratoma. As part of the evaluation for possible autoimmune encephalitis, we ordered brain magnetic resonance imaging (MRI) and electroencephalography (EEG); they were normal. Cerebrospinal fluid (CSF) evaluation showed a normal leukocyte count, normal protein levels

Key points

- Anti-*N*-methyl-D-aspartate receptor (NMDAR) encephalitis is a rare but important differential diagnosis of first-episode psychosis among young adults.
- Almost all patients with anti-NMDAR encephalitis who present with prominent psychiatric symptoms develop neurologic features within 4 weeks of symptom onset.
- Abnormalities on electroencephalography and cerebrospinal fluid evaluation are present in most patients with anti-NMDAR encephalitis.
- Testing for anti-NMDAR in cerebrospinal fluid has higher sensitivity and specificity for anti-NMDAR encephalitis compared with serum testing.
- Ovarian teratoma is the most commonly detected tumour in patients with anti-NMDAR encephalitis, although the rate of anti-NMDAR encephalitis in patients with ovarian teratoma is low.

and no CSF-specific oligoclonal bands. Given her unremarkable neurologic examination and test results, we did not administer empiric immunotherapy. Serum and, subsequently, CSF testing for anti-NMDAR returned negative 1 week after their collection. The patient's psychosis resolved in hospital on olanzapine. We discharged her with a diagnosis of unspecified psychotic disorder. The patient was lost to follow-up but then re-presented 10 months later and reported episodes with symptoms of depression and mania that were compatible with a diagnosis of bipolar spectrum disorder.

Discussion

Psychotic disorders are commonly diagnosed among young adults in Canada, with an incidence of 54.9 per 100 000 person-years in Ontario.¹ Anti-NMDAR encephalitis is an antibody-mediated encephalitis that was first described in young women with subacute neuropsychiatric decline and ovarian teratoma. It is a rare disease with an estimated incidence of 0.17 per 100 000 person-years.² Anti-NMDAR encephalitis affects young adults predominantly, may cause psychosis and can lead to substantial morbidity and even death if not promptly treated. For

these reasons, it is an important cause to be considered in young adults with first-episode psychosis.^{3,4}

Diagnostic criteria for anti-NMDAR encephalitis emphasize its core symptoms, EEG findings and CSF abnormalities (Box 1).⁵ Brain MRI is useful to screen for other neurologic conditions and can show abnormalities in patients with anti-NMDAR encephalitis. However, it is normal in two-thirds of patients and so it is not featured in the diagnostic criteria.^{3,5} These criteria indicate the need for a higher index of suspicion in patients with ovarian teratoma, as was the case in our patient. This is because while the frequency of anti-NMDAR encephalitis in patients with ovarian teratoma is about 1%, it is the most commonly detected tumour in patients with anti-NMDAR encephalitis.^{3,6} These criteria state that a diagnosis of definite anti-NMDAR encephalitis can be made in a patient with just 1 core symptom, such as new-onset psychosis, and a positive anti-NMDAR result. This has raised questions about which patients should be tested for anti-NMDAR. We therefore highlight key features that can help clinicians distinguish anti-NMDAR encephalitis from other causes of first-episode psychosis.

Box 1: Diagnostic criteria for anti-N-methyl-D-aspartate receptor encephalitis⁵

Probable anti-NMDAR encephalitis

Diagnosis can be made when all 3 of the following criteria have been met:

- Rapid onset (< 3 mo) of at least 4 of the 6 following major groups of symptoms:
 - Abnormal (psychiatric) behaviour or cognitive dysfunction
 - Speech dysfunction (pressured speech, verbal reduction, mutism)
 - Seizures
 - Movement disorder, dyskinesias or rigidity or abnormal postures
 - Decreased level of consciousness
 - Autonomic dysfunction or central hypoventilation
- At least 1 of the following laboratory study results:
 - Abnormal EEG (focal or diffuse slow or disorganized activity, epileptic activity or extreme delta brush)
 - CSF with pleocytosis or oligoclonal bands
- Reasonable exclusion of other disorders

Diagnosis can also be made in the presence of 3 of the above groups of symptoms, accompanied by a systemic teratoma.

Definite anti-NMDAR encephalitis

Diagnosis can be made in the presence of 1 or more of the 6 major groups of symptoms and immunoglobulin G antibodies against the GluN1 subunit,* after reasonable exclusion of other disorders.

Note: CSF = cerebrospinal fluid, EEG = electroencephalogram, NMDAR = N-methyl-D-aspartate receptor.

*Antibody testing should include testing of CSF. If only serum is available, confirmatory tests should be included (e.g., live neurons or tissue indirect immunofluorescence/immunohistochemistry, in addition to cell-based array).

Adapted from *Lancet Neurol* 15(4), Graus F, Titulaer MJ, Balu R, et al. A clinical approach to diagnosis of autoimmune encephalitis, 391–404, copyright 2016, with permission from Elsevier.

Clinical course

Prominent psychiatric symptoms such as psychosis may be a presenting feature of anti-NMDAR encephalitis.⁴ A multicentre observational study of 577 patients with anti-NMDAR encephalitis found that almost all developed neurologic features within 4 weeks, such as cognitive impairment, speech disorders, seizures, movement disorders, autonomic dysfunction or central hypoventilation, and only 1% of patients remained monosymptomatic after 1 month.³ Clinicians should therefore be alert to neurologic signs and symptoms in all patients with first-episode psychosis, the presence of which should lead to consideration of anti-NMDAR encephalitis. The absence of neurologic features weeks after symptom onset substantially reduces the likelihood of this disease.

Electroencephalography

A multicentre observational study found that EEG was abnormal in 90% of patients with anti-NMDAR encephalitis.³ A subsequent systematic review of EEG findings in patients with anti-NMDAR encephalitis confirmed a high frequency of EEG abnormalities, with the most common finding being diffuse and generalized slowing, indicative of encephalopathy.⁷ A normal EEG is thus atypical for anti-NMDAR encephalitis and reduces the likelihood of the disease.

Cerebrospinal fluid testing

A multicentre observational study found that CSF evaluation showed abnormalities compatible with inflammation in 80% of patients with anti-NMDAR encephalitis.³ Additional studies have corroborated the high frequency of inflammatory CSF findings in this disease, the most common being mild leukocyte pleocytosis (typically < 100 leukocyte/ μ L).^{7,8} Noninflammatory CSF with a normal leukocyte count, normal protein and no CSF-specific oligoclonal bands reduces the likelihood of anti-NMDAR encephalitis.

Testing for anti-NMDAR

Testing for anti-NMDAR can be performed using serum and CSF samples. However, serum testing has lower sensitivity and specificity (and therefore generates more false negatives and false positives) than CSF testing.^{9,10} With regard to false negatives, an observational study of 250 patients with anti-NMDAR encephalitis found that serum testing missed about 15% of cases compared with testing of CSF.⁹ With regard to false positives, a literature review of anti-NMDAR testing in first-episode psychosis showed a serum positivity rate of 3% across publications, often among patients who did not have distinct features of anti-NMDAR encephalitis and who did not have confirmatory CSF testing for anti-NMDAR performed, highlighting the potential for false-positive serum results.¹⁰ For this reason, in patients with first-episode psychosis who have anti-NMDAR detected in serum, CSF anti-NMDAR testing should be performed to confirm antibody positivity (Figure 1) and avoid misdiagnosis. It is important to note that the results of testing for anti-NMDAR can take up to several weeks to obtain.⁵ While awaiting antibody results, review of clinical symptoms and ancillary tests (e.g., EEG, CSF evaluation) for abnormalities suggestive of anti-NMDAR encephalitis is key for informing the decision about whether to start immunotherapy, the early administration of

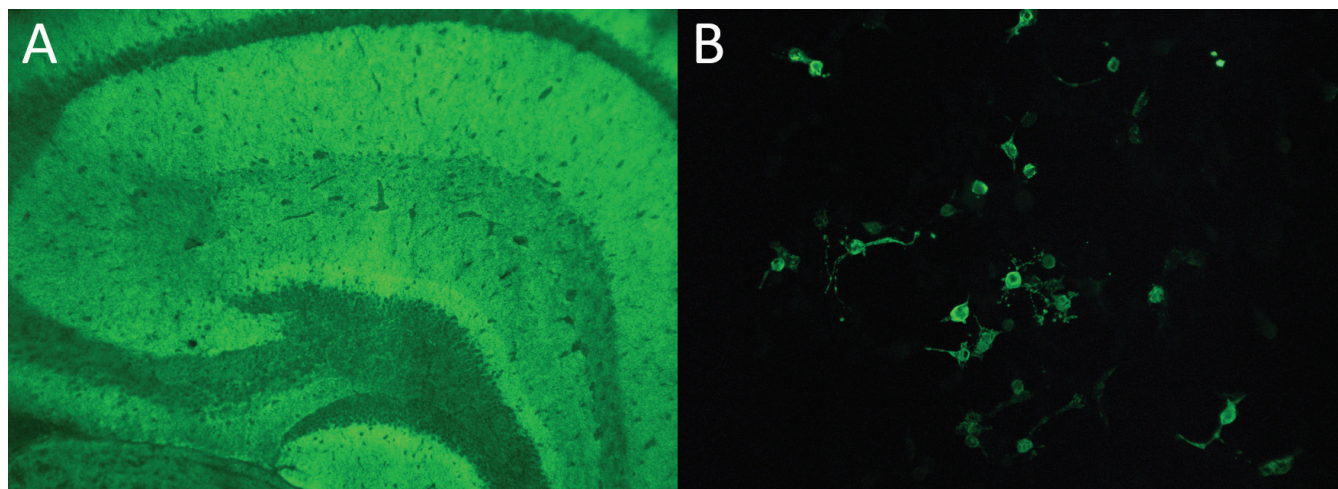


Figure 1: Positivity for anti-*N*-methyl-D-aspartate receptor (anti-NMDAR). Mouse brain tissue indirect immunofluorescence shows hippocampal staining typical of anti-NMDAR (A), alongside positivity for anti-NMDAR by cell-based assay (B).

which is a predictor of good outcome.³ First-line immunotherapies used in anti-NMDAR encephalitis include steroids, intravenous immunoglobulin and plasma exchange.³

Case revisited

Anti-NMDAR encephalitis is a rare yet treatable neuroinflammatory disease that occurs in young adults predominantly, and can manifest as new-onset psychosis. Because a definite diagnosis of anti-NMDAR encephalitis can be made in a patient with first-episode psychosis and a positive anti-NMDAR result, clinicians must consider in which patients with first-episode psychosis to order the test. Consensus guidelines on when to order tests such as MRI, EEG and CSF do not exist, and clinicians must use their judgment. Neurologic symptoms and abnormalities on EEG and CSF evaluation increase the likelihood of anti-NMDAR encephalitis considerably. Without these factors, the yield from anti-NMDAR testing is low; we ordered the test in our patient because of the association between ovarian teratoma and anti-NMDAR encephalitis.^{3,10} Because it can take weeks for the results of anti-NMDAR testing to become available, neurologic symptoms and ancillary test results can help decide whether to provide empiric immunotherapy while awaiting antibody results. Finally, the diagnosis of anti-NMDAR encephalitis should not be made solely on antibody positivity in serum, particularly if the clinical course and ancillary test findings are not typical for this disease.

References

1. Rotenberg M, Tuck A, Anderson KK, et al. The incidence of psychotic disorders and area-level marginalization in Ontario, Canada: a population-based retrospective cohort study. *Can J Psychiatry* 2022;67:216-25.
2. Nissen MS, Ørvik MS, Nilsson AC, et al. NMDA-receptor encephalitis in Denmark from 2009 to 2019: a national cohort study. *J Neurol* 2022;269:1618-30.
3. Titulaer MJ, McCracken L, Gabilondo I, et al. Treatment and prognostic factors for long-term outcome in patients with anti-NMDA receptor encephalitis: an observational cohort study. *Lancet Neurol* 2013;12:157-65.
4. Kayser MS, Dalmau J. Anti-NMDA receptor encephalitis, autoimmunity, and psychosis. *Schizophr Res* 2016;176:36-40.
5. Graus F, Titulaer MJ, Balu R, et al. A clinical approach to diagnosis of autoimmune encephalitis. *Lancet Neurol* 2016;15:391-404.
6. Yaguchi H, Tsuji T, Yabe I, et al. Incidence of anti-NMDAR encephalitis in patients undergoing resection of ovarian teratoma in a single institution. *J Neurol Sci* 2020;409:116608.
7. Gillinder L, Warren N, Hartel G, et al. EEG findings in NMDA encephalitis: a systematic review. *Seizure* 2019;65:20-4.
8. Wang R, Guan H-Z, Ren H-T, et al. CSF findings in patients with anti-*N*-methyl-D-aspartate receptor-encephalitis. *Seizure* 2015;29:137-42.
9. Gresa-Arribas N, Titulaer MJ, Torrents A, et al. Antibody titres at diagnosis and during follow-up of anti-NMDA receptor encephalitis: a retrospective study. *Lancet Neurol* 2014;13:167-77.
10. Guasp M, Giné-Servén E, Maudes E, et al. Clinical, neuroimmunologic, and CSF investigations in first episode psychosis. *Neurology* 2021;97:e61-75.

Competing interests: Laura Powe reports receiving payment from Otsuka Canada Pharmaceutical for a speaking presentation. Adrian Budhram reports membership of the *CMAJ* Practice Advisory Panel. Dr. Budhram holds the London Health Sciences Centre and London Health Sciences Foundation Chair in Neural Antibody Testing for Neuro-Inflammatory Diseases, and receives support from the Opportunities Fund of the Academic Health Sciences Centre Alternative Funding Plan of the Academic Medical Organization of Southwestern Ontario. No other competing interests were declared.

This article has been peer reviewed.

The authors have obtained patient consent.

Affiliations: Division of Neurology, Department of Medicine (Marsters), University of Alberta, Edmonton, Alta.; Departments of Psychiatry (Iskhakova, Powe) and Clinical Neurological Sciences (Budhram), and Pathology and Laboratory Medicine (Budhram), London Health Sciences Centre, Western University, London, Ont.

Contributors: All of the authors contributed to the conception and design of the work. Candace Marsters and Adrian Budhram drafted the manuscript. All of the authors revised it critically for important intellectual content, gave final approval of the version to be published and agreed to be accountable for all aspects of the work.

Content licence: This is an Open Access article distributed in accordance with the terms of the Creative Commons Attribution (CC BY-NC-ND 4.0) licence, which permits use, distribution and reproduction in any medium, provided that the original publication is properly cited, the use is noncommercial (i.e., research or educational use), and no modifications or adaptations are made. See: <https://creativecommons.org/licenses/by-nc-nd/4.0/>

Correspondence to: Adrian Budhram, Adrian.Budhram@lhsc.on.ca