

Aortitis in a patient on chemotherapy

Sho Fukui MD MPH, Genki Kidoguchi MD, Masato Okada MD

■ Cite as: *CMAJ* 2022 November 28;194:E1574. doi: 10.1503/cmaj.220584

A 58-year-old woman, who had received her fifth cycle of docetaxel and carboplatin adjuvant chemotherapy for uterine cancer 10 days before admission, was referred to the rheumatology department with persistent fever for 4 days. Eight days before admission, the patient had received granulocyte colony-stimulating factor (G-CSF) for the second time to prevent febrile neutropenia. Upon referral, she had a fever of 38.5°C and slight tenderness in her lower abdomen. Her leukocyte count was 12.6 (reference range 3.0 – 9.0) $\times 10^9/L$ and C-reactive protein level was 164 (reference < 1.4) mg/L. Contrast-enhanced, whole-body computed tomography (CT) showed no apparent causes of fever. We started treatment with piperacillin-tazobactam for possible abdominal infection. Five days after admission, we ordered another CT scan because the patient's fever persisted. The subsequent scan showed marked circumferential thickening of the wall of the descending thoracic aorta, suggesting aortitis or periaortitis, which was not present on the original CT scan (Figure 1 and Appendix 1, available at www.cmaj.ca/lookup/doi/10.1503/cmaj.220584/tab-related-content).

Given the repeated negative results from blood cultures and lack of response to antibiotic treatment, infectious aortitis was unlikely. The patient had no signs of autoimmune diseases, such as rheumatoid arthritis, systemic lupus erythematosus or immunoglobulin G4-related disease. Primary aortitis (e.g., giant cell arteritis) does not typically develop as acutely as observed in this patient. We therefore made a diagnosis of G-CSF- or chemotherapy-induced aortitis. The fever spontaneously subsided within a week, and a CT scan a month later showed improvement (Appendix 1). Aortitis did not recur after an additional cycle of docetaxel and carboplatin without G-CSF.

Chemotherapy agents, such as taxanes or platinum-containing agents, and G-CSF, particularly polyethylene glycol-conjugated G-CSF, have been reported to be associated with aortitis.^{1,2} Aortitis induced by G-CSF or chemotherapy typically develops about 1–2 weeks after administration^{1,3,4} and resolves within a month after medications are stopped. Glucocorticoids may hasten recovery, but we did not administer them to our patient.^{3,4} Physicians should be aware that CT scans may be normal in the early phase of G-CSF- or chemotherapy-induced aortitis.

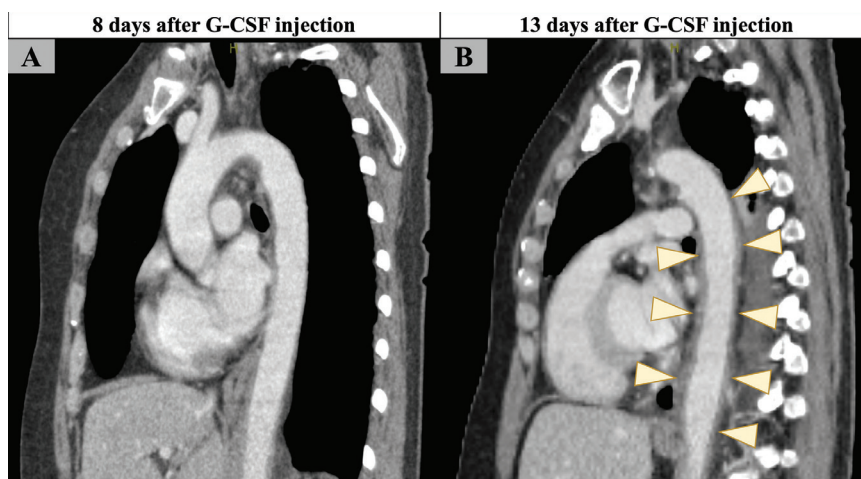


Figure 1: Contrast-enhanced computed tomography scans of the aorta in a febrile 58-year-old woman who had received granulocyte colony-stimulating factor (G-CSF), docetaxel and carboplatin, (A) 8 days after G-CSF administration, showing normal aorta, and (B) 5 days later, showing all-layer circumferential wall thickening of the descending thoracic aorta suggesting aortitis.

References

1. Taimen K, Heino S, Kohonen I, et al. Granulocyte colony-stimulating factor- and chemotherapy-induced large-vessel vasculitis: six patient cases and a systematic literature review. *Rheumatol Adv Pract* 2020;4:rkaa004.
2. Oshima Y, Takahashi S, Tani K, et al. Granulocyte colony-stimulating factor-associated aortitis in the Japanese Adverse Drug Event Report database. *Cytokine* 2019;119:47-51.
3. Lardieri A, McCulley L, Jones SC, et al. Granulocyte colony-stimulating factors and aortitis: a rare adverse event. *Am J Hematol* 2018;93:E333-6.
4. Shirai T, Komatsu H, Sato H, et al. Migratory aortitis associated with granulocyte colony-stimulating factor. *Intern Med* 2020;59:1559-63.

Competing interests: None declared.

This article has been peer reviewed.

The authors have obtained patient consent.

Affiliations: Immuno-Rheumatology Center (Fukui, Kidoguchi, Okada), St. Luke's International Hospital, Tokyo, Japan; General and Emergency Medicine (Fukui), School of Medicine, Kyorin University, Tokyo, Japan

Content licence: This is an Open Access article distributed in accordance with the terms of the Creative Commons Attribution (CC BY-NC-ND 4.0) licence, which permits use, distribution and reproduction in any medium, provided that the original publication is properly cited, the use is noncommercial (i.e., research or educational use), and no modifications or adaptations are made. See: <https://creativecommons.org/licenses/by-nc-nd/4.0/>

Correspondence to: Sho Fukui, fukusho@luke.ac.jp