

# Bow hunter syndrome

Anna Luisa Kühn MD PhD, Gerald T. McGillicuddy MD, Jasmeet Singh MD

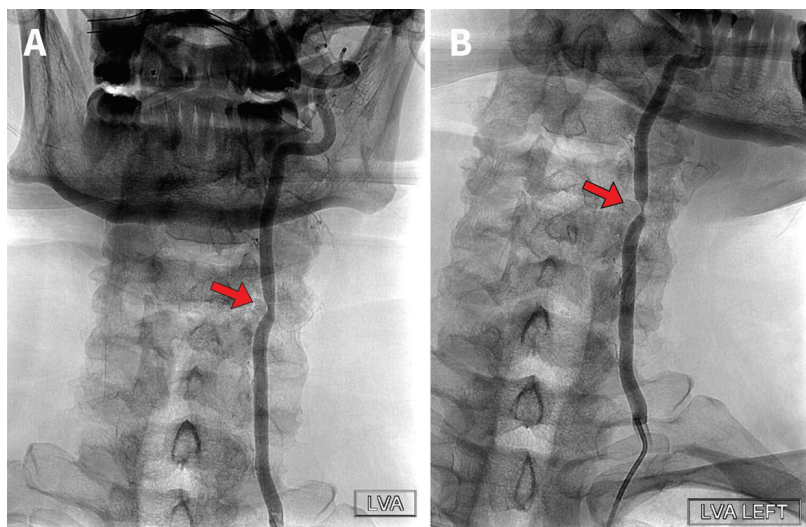
■ Cite as: *CMAJ* 2022 November 7;194:E1486. doi: 10.1503/cmaj.220607

A 59-year-old man presented to our neuro-endovascular clinic with a 10-month history of chronic dizziness, described as a spinning sensation, with associated gait instability and blurred vision upon head rotation. On examination, the spinning sensation could be elicited with mostly leftward head rotation. When the patient turned his head to a more neutral position, the symptoms slowly subsided. Flexion or extension of the neck did not elicit vertigo. The Dix–Hallpike manoeuvre did not elicit nystagmus and a Romberg test was negative. We did not observe any other neurologic abnormalities.

We initially thought the patient had benign paroxysmal positional vertigo; however, the Epley manoeuvres, vestibular rehabilitation therapy and meclizine were ineffective.

Given the refractory nature of the patient's vertigo, lack of a clear diagnosis and persistent ability to elicit symptoms with head rotation, we ordered cerebral angiography, which showed focal 80% narrowing of the left vertebral artery with a leftward head turn (Figure 1). We diagnosed bow hunter syndrome (BHS) and referred the patient to a neurosurgeon for an anterior cervical discectomy and removal of the uncinete process and associated osteophyte, which was compressing the left vertebral artery. At 3 months postsurgery, the patient described no rotational vertigo with only residual dizziness, which was gradually improving.

Bow hunter syndrome is also called rotational vertebral artery occlusion syndrome.<sup>1,2</sup> Patients usually present with reproducible, transient vertigo when they rotate or extend their head owing to dynamic stenosis of the affected vertebral artery (most often caused by an osteophyte, less often by disc herniations or tumours).<sup>2</sup> The incidence of BHS is not known and there are no guidelines on diagnosis and management.



**Figure 1:** Dynamic cerebral angiograms of a 59-year-old man with bow hunter syndrome. (A) When the patient was at rest, with his head in a neutral position, facing forward, we observed mild narrowing of the midcervical left vertebral artery caused by hypertrophy of a left uncovertebral joint of the third and fourth cervical vertebrae (arrow). (B) When the patient moved his head to the left, we noted significant luminal compromise of the left vertebral artery owing to compression of the vessel by the osseous structure (arrow).

Imaging to diagnose BHS includes computed tomography angiography, magnetic resonance angiography and cerebral angiography.<sup>1,3</sup> Some patients can be managed nonoperatively, whereas others benefit from surgery, which appears to have a good prognosis.<sup>3</sup>

## References

1. Duan G, Xu J, Shi J, et al. Advances in the pathogenesis, diagnosis and treatment of bow hunter's syndrome: a comprehensive review of the literature. *Interv Neurol* 2016;5:29-38.
2. Rastogi V, Rawls A, Moore O, et al. Rare etiology of bow hunter's syndrome and systematic review of literature. *J Vasc Interv Neurol* 2015;8:7-16.
3. Go G, Hwang S-H, Park IS, et al. Rotational vertebral artery compression: bow hunter's syndrome. *J Korean Neurosurg Soc* 2013;54:243-5.

**Competing interests:** None declared.

This article has been peer reviewed.

The authors have obtained patient consent.

**Affiliations:** Division of Neurointerventional Radiology (Kühn, Singh), Department of Radiology, University of Massachusetts Medical Center; Department of Neurological Surgery (McGillicuddy), University of Massachusetts Chan Medical School, Worcester, Mass.

**Content licence:** This is an Open Access article distributed in accordance with the terms of the Creative Commons Attribution (CC BY-NC-ND 4.0) licence, which permits use, distribution and reproduction in any medium, provided that the original publication is properly cited, the use is non-commercial (i.e., research or educational use) and no modifications or adaptations are made. See: <https://creativecommons.org/licenses/by-nc-nd/4.0/>

**Correspondence to:** Jasmeet Singh, [jasmeet.singh@umassmemorial.org](mailto:jasmeet.singh@umassmemorial.org)