

# Acute cytomegalovirus infection in a 61-year-old woman

Mai Hongo MD, Yukinori Harada MD PhD, Taro Shimizu MD PhD, Yoshiaki Gu MD PhD

■ Cite as: *CMAJ* 2022 August 22;194:E1109-11. doi: 10.1503/cmaj.220042

A 61-year-old woman was admitted to our medium-sized community hospital in northeastern Japan, with a fever. She had been well until 9 days before admission, when she developed consistent daily fevers of 38–39°C. She was not aware of any sick contacts. She worked in an office, had a history of asthma and thyroiditis, did not smoke nor drink alcohol, and her only regular medication was bilastine. She had visited a clinic 8 days before admission and an oral antibiotic (cefditoren pivoxil) was prescribed; however, her condition did not improve. She developed a rash 7 days before admission and was referred to the outpatient department of our hospital 2 days later. At that time, examination showed small, erythematous papules on her abdomen, arms and legs. Laboratory tests showed a leukocyte count of  $5.10$  (normal range  $3.30$ – $8.60$ )  $\times 10^9/L$ , neutrophils  $2.17$  (normal range  $1.70$ – $6.34$ )  $\times 10^9/L$ , lymphocytes  $2.23$  (normal range  $0.96$ – $3.10$ )  $\times 10^9/L$ , and platelets  $172$  (normal range  $158$ – $348$ )  $\times 10^9/L$ . The patient's serum C-reactive protein level was  $14.4$  (normal range  $0.0$ – $3.0$ ) mg/L, aspartate aminotransferase  $35$  (normal range  $11$ – $32$ ) U/L, and  $\gamma$ -glutamyl transferase  $46$  (normal range  $5$ – $35$ ) U/L. She was suspected of having a viral infection and was not given any specific treatment. Antibodies to cytomegalovirus (CMV) and Epstein-Barr virus (EBV) were tested at this time. She visited the emergency department again 2 days before admission because she could not eat owing to fever, anorexia and a sore throat. No cause of the fever was identified, and she was scheduled for admission for further evaluation. One day before admission, her rash disappeared.

On admission, the patient was fully oriented. Her blood pressure was 122/88 mm Hg, pulse rate 105 beats/min, body temperature 38.0°C and oxygen saturation 99% on ambient air. She was not pale or icteric and had no conjunctival hemorrhages. Examination of the oropharynx showed no pharyngeal edema, exudate or lesions. Her neck was supple. We detected no abnormalities on cardiovascular examination or auscultation of her lungs. Her abdomen was flat and soft without palpable hepatosplenomegaly. She had no spinal or costovertebral angle tenderness and no skin rash or peripheral edema.

Laboratory tests showed a slightly increased leukocyte count of  $9.40 \times 10^9/L$  with neutrophils  $5.83 \times 10^9/L$  and lymphocytes  $2.91 \times 10^9/L$ . Her platelet count was  $202 \times 10^9/L$ . Aspartate aminotransferase ( $54$  U/L), alanine aminotransferase ( $51$  U/L),  $\gamma$ -glutamyl transferase ( $60$  [normal range  $5$ – $35$ ] U/L), C-reactive

## Key points

- Acute cytomegalovirus infection can occur in older adults who are not obviously immunocompromised and should be considered in the differential diagnosis of patients with fever of unknown origin.
- Cytomegalovirus serology should be repeated if infection is suspected but the initial results are negative; in such a situation, polymerase chain reaction testing for cytomegalovirus can also be useful.
- Acute cytomegalovirus infection in patients who are not immunocompromised usually does not require antiviral therapy.

protein ( $51.0$  mg/L) and D-dimer ( $11\ 800$  [reference  $0$ – $1000$ ]  $\mu\text{g/L}$ ) levels were elevated. A SARS-CoV-2 antigen test was negative. We detected slight protein (1+), slight microscopic hematuria (1+), and a few bacteria but no leukocytes on urinalysis. A radiograph of the patient's chest was normal.

We considered viral infection (including infectious mononucleosis), bacterial infection (including infective endocarditis and tuberculosis), autoimmune disease and cancer (including lymphoma) as differential diagnoses based on persistent fever, mild transaminitis, slight proteinuria and microscopic hematuria. We did not think she had *Toxoplasma* infection because she had no risk factors. An HIV test was negative. Antinuclear and antineutrophil cytoplasmic antibodies were negative, and no bacteria or fungi grew on blood or urine cultures. Because of her complete blood count results, she did not fulfill the criteria for hemophagocytic lymphohistiocytosis. We did not order nasopharyngeal swabs for antigen tests for respiratory viruses because she did not report any sick contacts and did not have any respiratory symptoms. Contrast-enhanced chest and abdominal computed tomography showed only a liver cyst and no focus of infection.

During the patient's hospital stay, her fever persisted but her general condition remained stable. The results of CMV and EBV antibody tests, performed on samples collected 5 days before admission, became available on day 3 of her stay; they showed past EBV infection but were negative for CMV immunoglobulin M (IgM) and G (IgG). Because CMV negativity in her age group is low in Japan (about 3%),<sup>1,2</sup> we suspected laboratory error and

retested for serum CMV antibodies. We did not order polymerase chain reaction (PCR) testing for diagnosis of primary CMV infection because it is not covered for reimbursement by the national health insurance system. On day 6, the CMV IgM and IgG test results were positive (Figure 1) and we diagnosed acute CMV infection without tissue-invasive disease. On further history, the patient recalled sharing eating utensils with someone, a possible route of infection. As she was not immunocompromised, we did not administer specific antiviral treatment, such as valganciclovir or ganciclovir, which are used to treat CMV disease in patients who are immunocompromised. We treated the patient with a non-steroidal anti-inflammatory drug and she was discharged on day 12.

As the mean duration of symptomatic CMV infection is about 8 weeks,<sup>3</sup> we monitored the patient without further investigation. Her fever and malaise resolved completely within 4 weeks after discharge. She was well at the last outpatient follow-up, 3 months after discharge.

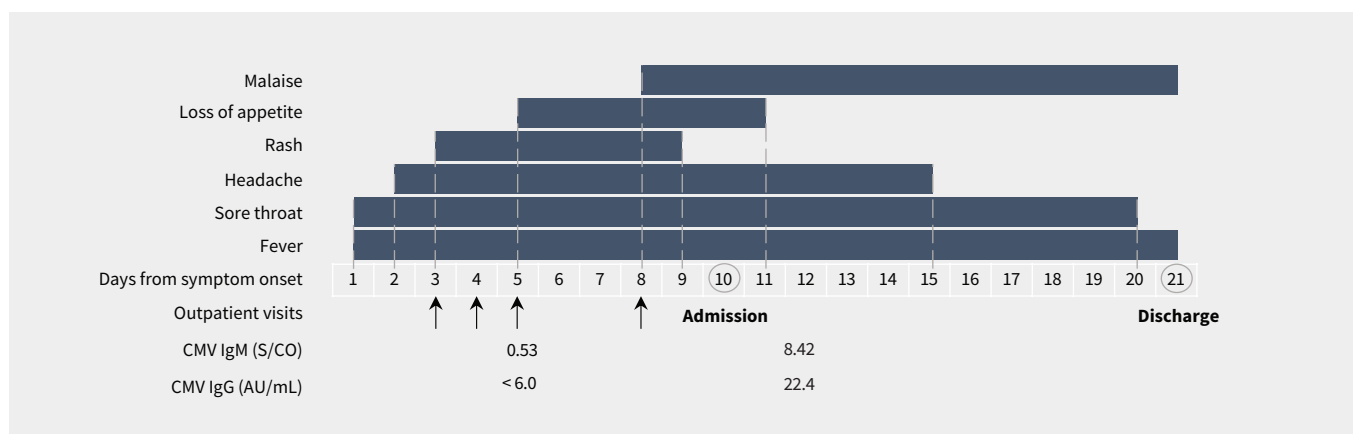
## Discussion

Cytomegalovirus infection can vary from asymptomatic infection to tissue-invasive disease. Clinicians should recognize the difference between CMV infection and CMV disease: the former refers to evidence of CMV replication regardless of symptoms, while the latter refers to evidence of CMV infection with attributable symptoms. Furthermore, CMV disease can be categorized as a viral syndrome (e.g., fever, malaise, leukopenia, neutropenia, thrombocytopenia, elevation of hepatic aminotransferases) or tissue-invasive disease.<sup>4,5</sup> Tissue-invasive disease is defined as appropriate clinical symptoms and signs of end-organ disease (e.g., enteritis, hepatitis, nephritis, pneumonitis, meningoencephalitis, retinitis) with documentation of CMV in tissue from the relevant organ.<sup>4,5</sup> In patients who are immunocompetent, most infections are asymptomatic, and the most common clinical presentation is CMV mononucleosis, presenting as fever, malaise, sore throat, headache, lymphocytosis, presence of more than 10% atypical lymphocytes, and elevation of hepatic aminotransferases.<sup>6</sup> Although tissue-invasive CMV disease can occur in patients who are immunocompetent,<sup>7</sup> its incidence is low. In contrast, for those who are immunocompromised

(e.g., are post-transplant, have HIV infection, are treated with immunomodulatory drugs) and infants with congenital CMV infection, tissue-invasive disease is a major concern.<sup>6</sup>

Cytomegalovirus seroprevalence varies by region, tending to be higher in Africa, Asia and South America, and lower in Europe and North America.<sup>8</sup> A previous study estimated the global mean seroprevalence for the general population at 83%; CMV seroprevalence was reported to be 42% in Canada and 72% in Japan.<sup>8</sup> Cytomegalovirus seroprevalence increases with age, and in countries with high CMV seroprevalence such as Japan, seropositivity reaches nearly 100% in those aged 60 years or older.<sup>1</sup> In Canada, 67%–73% of blood and organ donors and organ recipients were reported to be seropositive by the age of 70 years.<sup>9</sup>

The diagnostic approaches for CMV infection and disease depend on the patient's clinical history. For diagnosing primary CMV infection in patients who are immunocompetent, serologic studies are the standard: either the detection of CMV IgM or a fourfold rise in CMV IgG (usually at least 2 weeks apart) confirm the diagnosis. Cytomegalovirus IgM antibodies are typically detectable within the first 2 weeks and may remain elevated for several months or even up to 1 year.<sup>6,10</sup> Cytomegalovirus IgG antibodies are detectable 2 to 3 weeks after the development of symptoms.<sup>10</sup> When the diagnosis is suspected but IgM and IgG antibodies are both negative, repeat serologic testing 1 or 2 weeks later can confirm seroconversion. In this setting, the PCR test may be helpful for the timely diagnosis of primary CMV infection. However, as both the sensitivity and specificity of PCR can be low,<sup>6,10</sup> using PCR alone is not recommended for the diagnosis of CMV infection in patients who are immunocompetent. In contrast, for patients who are immunocompromised and, particularly, those who are post-transplant, PCR is the preferred diagnostic test and serologic studies have no role in diagnosing active CMV infection and disease. This is because both primary and secondary infection due to reactivation of CMV in seropositive patients is common in this patient population.<sup>4</sup> Polymerase chain reaction is also preferred in this population, as rapid detection and monitoring of DNA levels are required to select appropriate antiviral therapy and decide on the duration of therapy in patients who are immunocompromised and have CMV disease.<sup>4</sup>



**Figure 1:** Time course of symptoms and titres of antibodies for cytomegalovirus (CMV). Normal values for CMV immunoglobulin M (IgM): < 0.85; CMV immunoglobulin G (IgG) < 6.0.

In patients who are immunocompromised, CMV-IgG is useful for assessing latent CMV infection to stratify the risk of CMV infection and disease.

Cytomegalovirus infection and disease in patients who are immunocompetent are generally self limited and antiviral therapy is usually unnecessary; even in severe CMV disease, the benefit of antiviral therapy is inconclusive.<sup>7</sup> In contrast, most patients who are post-transplant and have CMV infection, even if asymptomatic, require antiviral treatment to prevent the development of tissue-invasive disease (pre-emptive therapy). For pre-emptive therapy, oral valganciclovir is usually selected, and patients are treated until the viral load is undetectable or less than the lower quantifiable limit of the assay.<sup>4</sup> For symptomatic CMV disease in patients who are post-transplant, oral valganciclovir or intravenous ganciclovir are recommended until eradication of CMV-DNA below the lower limit of quantification (< 200 IU/mL) and resolution of all clinical signs of CMV disease.<sup>4</sup>

## References

1. Furui Y, Satake M, Hoshi Y, et al. Cytomegalovirus (CMV) seroprevalence in Japanese blood donors and high detection frequency of CMV DNA in elderly donors. *Transfusion* 2013;53:2190-7.
2. Takeda N, Isonuma H, Sekiya S, et al. Studies of anti-cytomegalovirus IgG antibody positive rate and cytomegalovirus mononucleosis in adults [article in Japanese]. *Kansenshogaku Zasshi* 2001;75:775-9.
3. Wreghitt TG, Teare EL, Sule O, et al. Cytomegalovirus infection in immunocompetent patients. *Clin Infect Dis* 2003;37:1603-6.
4. Kotton CN, Kumar D, Caliendo AM, et al. The third international consensus guidelines on the management of cytomegalovirus in solid-organ transplantation. *Transplantation* 2018;102:900-31.
5. Ljungman P, Boeckh M, Hirsch HH, et al. Definitions of cytomegalovirus infection and disease in transplant patients for use in clinical trials. *Clin Infect Dis* 2017; 64:87-91.
6. Taylor GH. Cytomegalovirus. *Am Fam Physician* 2003;67:519-24.
7. Rafailidis PI, Mourtzoukou EG, Varbobitis IC, et al. Severe cytomegalovirus infection in apparently immunocompetent patients: a systematic review. *Virology* 2008;5:47.
8. Zuhair M, Smit GSA, Wallis G, et al. Estimation of the worldwide seroprevalence of cytomegalovirus: a systematic review and meta-analysis. *Rev Med Virol* 2019; 29:e2034.
9. Mabilangan C, Burton C, O'Brien S, et al. Using blood donors and solid organ transplant donors and recipients to estimate the seroprevalence of cytomegalovirus and Epstein-Barr virus in Canada: a cross-sectional study. *J Assoc Med Microbiol Infect Dis Can* 2020;5:158-76.
10. Chou S. Newer methods for diagnosis of cytomegalovirus infection. *Rev Infect Dis* 1990;12(Suppl 7):S727-36.

**Competing interests:** Yukinori Harada reports receiving a grant from the Japan Society for the Promotion of Science Grants in Aid for Scientific Research (KAKENHI) program, and an honorarium from PRECISION, Inc., as a manuscript fee. Dr. Harada also reports holding an unpaid position as a joint representative of the Diagnostic Excellence Working Group of the Japanese Society of Hospital General Medicine. No other competing interests were declared.

This article has been peer reviewed.

The authors have obtained patient consent.

**Affiliations:** Department of General Practice (Hongo), Saka General Hospital, Miyagi, Japan; Department of Diagnostic and Generalist Medicine (Harada, Shimizu), Dokkyo Medical University, Mibu, Shimotsugagun, Tochigi, Japan; Department of Infectious Diseases (Gu), Graduate School of Medical and Dental Sciences, Tokyo Medical and Dental University, Tokyo, Japan

**Contributors:** All of the authors contributed to the conception and design of the work. Mai Hongo drafted the manuscript. All of the authors revised it critically for important intellectual content, gave final approval of the version to be published and agreed to be accountable for all aspects of the work.

**Content licence:** This is an Open Access article distributed in accordance with the terms of the Creative Commons Attribution (CC BY-NC-ND 4.0) licence, which permits use, distribution and reproduction in any medium, provided that the original publication is properly cited, the use is noncommercial (i.e., research or educational use), and no modifications or adaptations are made. See: <https://creativecommons.org/licenses/by-nc-nd/4.0/>

**Correspondence to:** Yoshiaki Gu, [yogu.cid@tmd.ac.jp](mailto:yogu.cid@tmd.ac.jp)

The section Cases presents brief case reports that convey clear, practical lessons. Preference is given to common presentations of important rare conditions, and important unusual presentations of common problems. Articles start with a case presentation (500 words maximum), and a discussion of the underlying condition follows (1000 words maximum). Visual elements (e.g., tables of the differential diagnosis, clinical features or diagnostic approach) are encouraged. Consent from patients for publication of their story is a necessity. See information for authors at [www.cmaj.ca](http://www.cmaj.ca).