

Giant cell arteritis presenting with progressive dysphagia and tongue necrosis

Caroline Payen MBBS, Florentin Kucharczak PhD, Valentin Favier MD PhD

■ Cite as: *CMAJ* 2022 March 21;194:E420. doi: 10.1503/cmaj.211483

A 72-year-old man was admitted to hospital with 1 month of progressive solid food dysphagia that caused a 10-kg weight loss. The patient reported alcohol and tobacco use but had no known medical conditions. An oral examination and head and neck computed tomography (CT) were normal apart from poor dentition. Laboratory investigations showed a raised C-reactive protein level (54.4 [normal < 5] mg/L) and normal leukocyte count (6.83 [normal 4.0–10.0] $\times 10^9/L$). Gastroscopy and barium swallow test were unremarkable. He was discharged without a diagnosis.

The patient returned to hospital 1 week later with severe oral and maxillary pain and persistent dysphagia. We found a lingual lesion with white coating (Figure 1A). The result for a repeat C-reactive protein test was 117.6 mg/L and the patient's leukocyte count was $11.04 \times 10^9/L$.

Two days later, the left lingual lesion had become necrotic (Figure 1B). We suspected malignant disease and performed a panendoscopic examination and biopsied his tongue. No other lesions were found. The histopathology showed complete ischemic tissue necrosis, with no signs of malignant disease or vasculitis. We arranged a CT angiogram to determine the cause of his tongue ischemia, which showed isolated luminal narrowing of the left lingual artery. Because we suspected giant cell arteritis, we performed a temporal artery biopsy. It confirmed a granulomatous arteritis compatible with giant cell arteritis.

We started treatment with methylprednisolone (250 mg/d for 3 d) followed by prednisone (1 mg/kg/d). The patient's tongue healed, and his pain and dysphagia resolved.

Giant cell arteritis, or temporal arteritis, has a prevalence of 1 in 500 individuals,¹ and involves large and medium arteries such as carotid artery branches. Common symptoms include headache, scalp tenderness, jaw claudication, ocular ischemic manifestations and inflammatory arthralgia. Dysphagia and tongue necrosis are uncommon manifestations of giant cell arteritis associated with a high (50%) risk of recurrence.² Tongue necrosis has many differential diagnoses in addition to vasculitis, including malignant disease, embolism and drug- or radiation-related adverse effects.¹

Corticosteroid therapy should be started as soon as giant cell arteritis is suspected. Treatment with prednisone is suggested at 1 mg/kg/d for 6 weeks.³

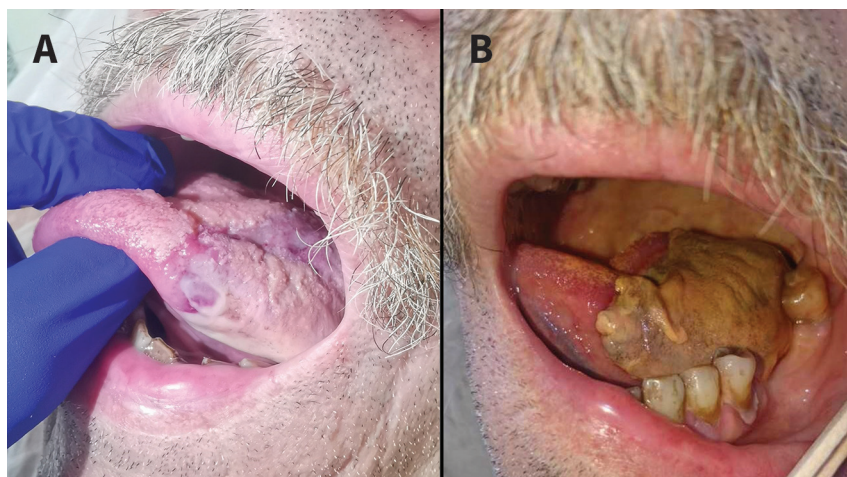


Figure 1: (A) White-coated lesion of the left border of the tongue in a 72-year-old man with 5-week progressive solid food dysphagia. (B) Secondary necrosis of the left border of the patient's tongue, 2 days later.

References

1. Zaragoza JR, Vernon N, Ghaffari G. Tongue necrosis as an initial manifestation of giant cell arteritis: case report and review of the literature. *Case Rep Rheumatol* 2015;2015:901795.
2. Barbosa de Siqueira Sobrinho RA, Alvino de Lima KC, Carvalho Moura H, et al. Tongue necrosis secondary to giant cell arteritis: a case report and literature review. *Case Rep Med* 2017;2017:1-5.
3. DeBord LC, Chiu I, Liou NE. Delayed diagnosis of giant cell arteritis in the setting of isolated lingual necrosis. *Clin Med Insights Case Rep* 2019;12:1179547619857690.

Competing interests: None declared.

This article has been peer reviewed.

The authors have obtained patient consent.

Affiliations: Otolaryngology, Head and Neck Surgery Department, University Hospital of Montpellier, Montpellier, France

Content licence: This is an Open Access article distributed in accordance with the terms of the Creative Commons Attribution (CC BY-NC-ND 4.0) licence, which permits use, distribution and reproduction in any medium, provided that the original publication is properly cited, the use is noncommercial (i.e., research or educational use), and no modifications or adaptations are made. See: <https://creativecommons.org/licenses/by-nc-nd/4.0/>

Correspondence to: Valentin Favier, Valentin_favier@hotmail.com