

Asymptomatic hydrocephalus

Amit R. Persad, MD, Victoria Bass MD, Kotoo Meguro MD

■ Cite as: *CMAJ* 2021 April 6;193:E480. doi: 10.1503/cmaj.200889

A 72-year-old woman was admitted to hospital from the emergency department after a witnessed generalized tonic-clonic seizure, for which she was initially given phenytoin. The patient was seen by the neurosurgery team for assessment of hydrocephalus, which had been diagnosed using emergency computed tomography (CT) of her head (Figure 1). The scan showed lateral and third ventriculomegaly, and there was marked cortical thinning with no herniation, which suggested a long-term obstructive pathology.

The patient lived independently and had no previous history of seizures or diagnosis of hydrocephalus. Her developmental history was unremarkable; she had finished high school and had worked in various retail jobs. When our team examined her, she was alert and oriented, and did not report headache, visual disturbance or cognitive changes; her neurologic examination (including a Mini-Mental State Examination) was normal. The only pertinent physical finding was a long-standing gait disturbance related to hip dysplasia. An electroencephalogram showed epileptiform discharges, and we prescribed levetiracetam (500 mg administered orally twice daily) and stopped treatment with phenytoin. The patient also had an urinary tract infection (UTI), which was treated with trimethoprim/sulfamethoxazole. After 2 days in hospital, she was discharged with follow-up in the adult hydrocephalus clinic. She was well at 6-month follow-up, with no further seizures.

Hydrocephalus has an adult prevalence of about 1 in 10 000 persons, with 10% of cases caused by stenosis of the aqueduct of Sylvius.¹ Other common causes include congenital hydrocephalus, infection, trauma and obstructive mass lesions. As with our patient, people can function normally, even with substantial ventriculomegaly and cysts.^{2,3} In our opinion, this patient's seizure was not caused by long-term hydrocephalus; however, she may have had decreased seizure threshold given co-occurring hydrocephalus and UTI.

Our patient's CT imaging is consistent with long-standing overt ventriculomegaly in adults,¹ a type of arrested hydrocephalus stemming from congenital problems such as aqueductal stenosis.

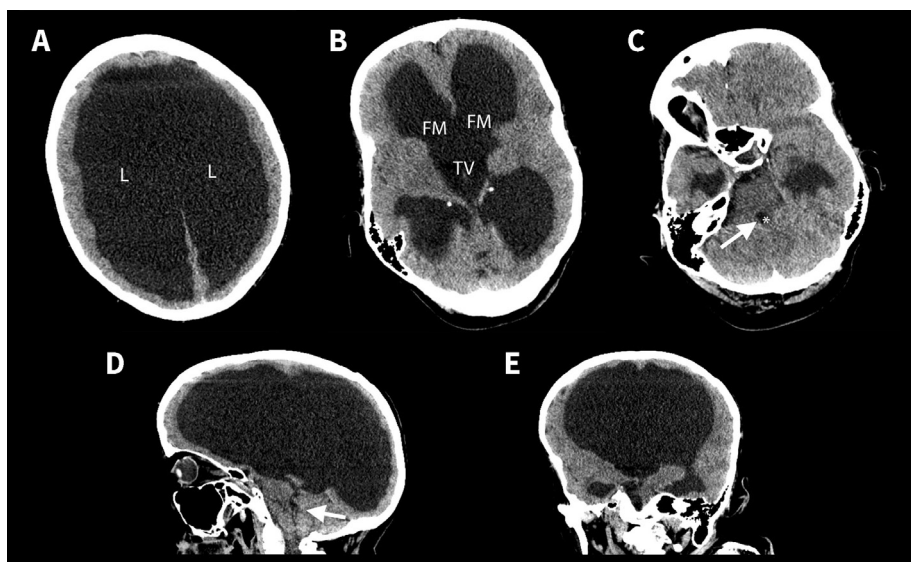


Figure 1: Computed tomography images showing massive ventriculomegaly in the brain of a 72-year-old woman. Axial views at the level of (A) the lateral ventricles showing thinned cortex, (B) the foramen of Monro showing an open foramen of Monro and enlarged third ventricle, and (C) the fourth ventricle showing the small caliber of the fourth ventricle (arrow). (D) Sagittal (arrow indicates the fourth ventricle) and (E) axial views showing obstructive ventriculomegaly. Note: L = lateral ventricle, FM = foramen of Monro, TV = third ventricle.

References

- Oi S, Shimoda M, Shibata M, et al. Pathophysiology of long-standing overt ventriculomegaly in adults. *J Neurosurg* 2000;92:933-40.
- Feuillet L, Dufour H, Pelletier J. Brain of a white-collar worker. *Lancet* 2007;370:262.
- Hubele F, Imperiale A, Kremer S, et al. Asymptomatic giant arachnoid cyst. *Clin Nucl Med* 2012;37:982-3.

Competing interests: None declared.

This article has been peer reviewed.

The authors have obtained patient consent.

Affiliations: Division of Neurosurgery (Persad, Meguro), Department of Surgery, College of Medicine, University of Saskatchewan, Saskatoon, Sask.; Division of Neurosurgery (Bass), McMaster University, Hamilton, Ont.

Content licence: This is an Open Access article distributed in accordance with the terms of the Creative Commons Attribution (CC BY-NC-ND 4.0) licence, which permits use, distribution and reproduction in any medium, provided that the original publication is properly cited, the use is noncommercial (i.e., research or educational use), and no modifications or adaptations are made. See: <https://creativecommons.org/licenses/by-nc-nd/4.0/>

Correspondence to: Kotoo Meguro, kotoo.meguro@usask.ca