

Warfarin and absolute risk of hemorrhagic stroke

We read with great interest the *CMAJ* article by Gomes and colleagues,¹ which highlights the importance of quantifying the risk of bleeding episodes associated with warfarin now that new therapeutic options are becoming available.

We have just completed a population-based cohort study using the Health Improvement Network, a primary care database from the United Kingdom, aimed at estimating the incidence rate of hemorrhagic stroke in the general population.² We identified individuals aged 20 to 89 years between 2000 and 2008 and followed them for an average of 5.8 years. Overall, we ascertained 1797 cases of intracerebral hemorrhage and 1340 cases of subarachnoid hemorrhage. We wanted to explore if we could reproduce the estimates of hemorrhagic stroke risk among new users of warfarin reported by Gomes and colleagues using our data from the UK.

We found that, among those aged 65 years and older who were prescribed warfarin for the first time, the incidence rate of hemorrhagic stroke after starting warfarin was 294.6 cases per 100 000 person-years (95% CI [confidence interval] 118.5–606.1) within the first 30 days and 165.6 cases per 100 000 person-years (95% CI 136.6–199.2) during the overall follow-up. These figures correspond to annual rates of 0.29% per person-year for the 30-day period, and 0.17% per person-year for the overall follow-up period. Both estimates are extremely similar to those reported by Gomes and colleagues¹ for intracranial hemorrhage: 0.4% for the initial 30 days and 0.2% overall.

In conclusion, we have been able to reproduce similar estimates of absolute risk to those reported by Gomes and colleagues¹ in a different population (UK) when using an analogous design despite different sources of information. Along with their study, our results serve to underline the importance of performing this type of study in a population-based setting, which mimics the real-life scenario of a clinician better than

estimates based on clinical trial data. It is therefore important that newer anticoagulant drugs that have emerged in recent years should also be subjected to population-based studies performed with valid sources of information and valid methods in years to come.

Antonio Gonzalez-Perez MSc, David Gaist MD PhD, Luis A. Garcia Rodriguez MD

Spanish Centre for Pharmacoepidemiologic Research (CEIFE) (Gonzalez-Perez, Rodriguez), Madrid, Spain; Andalusian Bioinformatics Research Center (CAEBi) (Gonzalez-Perez), Seville, Spain; Neurology Department (Gaist), Odense University Hospital, Odense, Denmark; and the Institute of Clinical Research (Gaist), Faculty of Health Sciences, University of Southern Denmark, Odense, Denmark

References

1. Gomes T, Mamdani MM, Holbrook AM, et al. Rates of hemorrhage during warfarin therapy for atrial fibrillation. *CMAJ* 2013;185:E121-7.
2. Gaist D, Wallander MA, González-Pérez A, et al. Incidence of hemorrhagic stroke in the general pop-

ulation: validation of data from The Health Improvement Network. *Pharmacoepidemiol Drug Saf* 2013;22:176-82.

CMAJ 2013. DOI:10.1503/cmaj.113-2115

Not all diclofenac is equal

I hope that topical diclofenac (Voltaren Emulgel), which is absorbed to a negligible extent but is most useful in treating some soft-tissue and joint pain, does not become labelled as a problem, similar to oral formulations.

The distinction was not mentioned in either of the Apr. 2, 2013, *CMAJ* news articles^{1,2} about the hazards of diclofenac.

Robert C. Dickson MD
Physician, Hamilton, Ont.

References

1. Spitz S. Physicians should be cautious when prescribing diclofenac. *CMAJ* 2013;185:470.
2. Spitz S. Diclofenac linked to increased risk of *C. difficile*. *CMAJ* 2013;185:471.

CMAJ 2013. DOI:10.1503/cmaj.113-2117

CORRECTION

Neurocognitive and psychiatric changes as the initial presentation of neurosyphilis

In a recent Practice article,¹ the magnetic resonance imaging scan showing mineral deposits within the globus pallidus was incorrect. The correct image (Figure 1) and revised caption are included here.

Reference

1. Costiniuk CT, MacPherson PA. Neurocognitive and psychiatric changes as the initial presentation of neurosyphilis. *CMAJ* 2013;185:499-503.

CMAJ 2013. DOI:10.1503/cmaj.113-2116

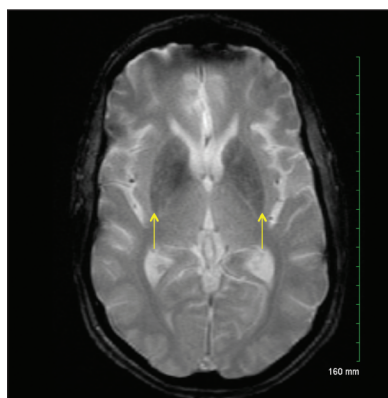


Figure 1: Gradient-echo magnetic resonance imaging scan of the brain in case 1, showing diffuse, somewhat increased mineralization seen as low signal intensity in the basal ganglia with bilateral involvement of the putamen (arrows) and caudate nucleus. Even lower signal intensity of the medial globus pallidus is a physiological finding.