

CLINICAL IMAGES

Oral lichen planus

Eric T. Stoopler DMD, Thomas P. Sollecito DMD

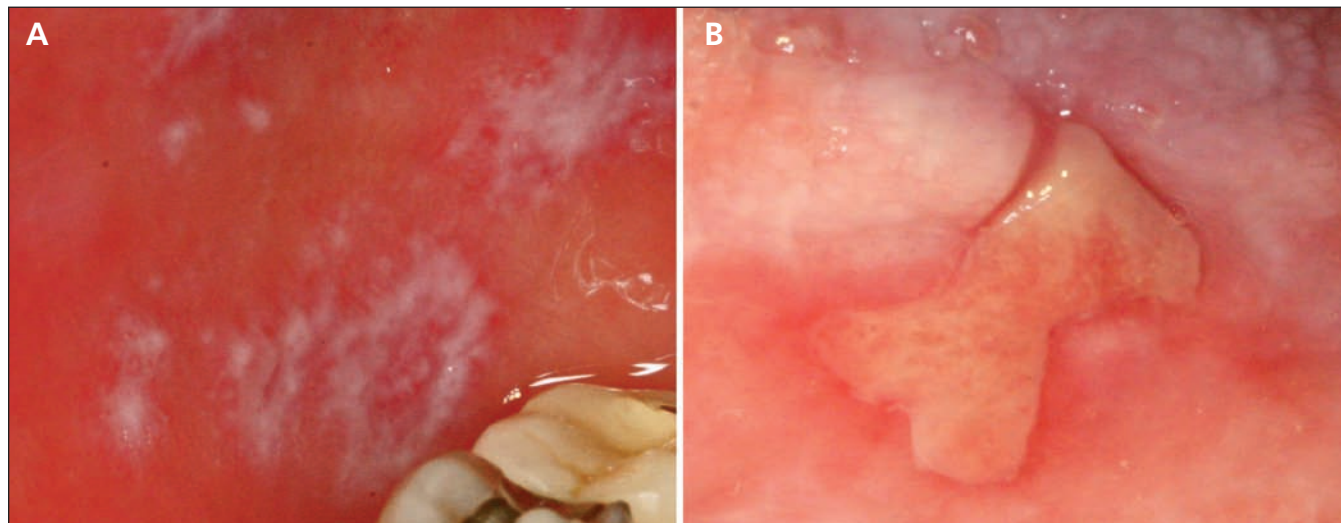


Figure 1: (A) Annular and reticular striations accompanied by erythema on the buccal mucosa of a 72-year-old woman presenting with a painful burning sensation in her mouth. (B) Asymmetric ulceration with surrounding erythema on the lateral surface of the patient's tongue.

Competing interests: None declared.

This article has been peer reviewed.

Affiliation: From the Department of Oral Medicine, University of Pennsylvania School of Dental Medicine, Philadelphia, Pa.

Correspondence to: Eric T. Stoopler, ets@dental.upenn.edu

CMAJ 2012. DOI:10.1503/cmaj.111825

A 72-year-old woman presented with a six-month history of a painful burning sensation in her mouth. Examination revealed lesions on the buccal mucosa and the lateral surface of her tongue (Figure 1). A biopsy of the buccal mucosa revealed histopathologic features consistent with oral lichen planus (Appendix 1, available at www.cmaj.ca/lookup/suppl/doi:10.1503/cmaj.111825/-/DC1). Topical corticosteroid treatment and topical antifungal prophylaxis resulted in substantial improvement of her condition within one month.

Lichen planus is a chronic autoimmune disease that affects various surfaces, including the skin, scalp, nails and mucous membranes.^{1,2} Global prevalence is about 1% to 2%.² The disease affects people of all ethnic groups. It is most commonly seen in people 30–60 years old and occurs more often in females than in males.²

Oral lichen planus primarily affects the buccal mucosa, gingiva and the dorsal surface of the tongue and may not be associated with lesions on other mucosal or cutaneous surfaces.² Clinical variants of oral lichen planus include asymptomatic forms such as reticular, papular, plaque-like lesions; erythematous and erosive forms of

the disease are often associated with pain and bleeding.¹ Current evidence points to a complex disease process mediated by cytotoxic CD8+ T cells that is directed against basilar keratinocytes and results in vacuolar degeneration and lysis of these cells.^{1,2} Diagnosis is based on defined histopathologic criteria coupled with the clinical appearance of the lesions. Although no cure is available, results of a systematic review show that initial treatment of symptomatic lesions with topical or systemic corticosteroids often results in partial resolution of the condition depending on the distribution and severity of the lesions.³ Malignant transformation of oral lichen planus occurs in about 1% of patients but is more prevalent among those with atrophic and erosive lesions, which emphasizes the need for long-term follow-up of patients with this condition.^{1–3}

References

1. Crincoli V, Di Bisceglie MB, Scivetti M, et al. Oral lichen planus: update on etiopathogenesis, diagnosis and treatment. *Immunopharmacol Immunotoxicol* 2011;33:11–20.
2. Parashar P. Oral lichen planus. *Otolaryngol Clin North Am* 2011;44:89–107.
3. Al-Hashimi I, Schifter M, Lockhart PB, et al. Oral lichen planus and oral lichenoid lesions: diagnostic and therapeutic considerations. *Oral Surg Oral Med Oral Pathol Oral Radiol Endod* 2007; Suppl:S25.e1–12.