

CLINICAL IMAGES

Massive “sweet” hydrothorax

Po-Jen Yang MD, Tsan-Hsing Liu MD

Previously published at www.cmaj.ca

See also practice article by McGrath and Barber, page 1879

A 59-year-old woman with end-stage renal disease presented to the emergency department with shortness of breath about one month after starting continuous ambulatory peritoneal dialysis. On examination, she had decreased breath sounds on the right side. A chest radiograph showed a large right-sided pleural effusion with a mediastinal shift to the left (Figure 1). The possible diagnoses included pneumonia with parapneumonic effusion, malignant effusion, hemothorax, heart failure and fluid overload.

We drained the pleural fluid, which was clear and yellowish (Figure 2). Laboratory analysis of the effusion showed a glucose level of 18.4 mmol/L, a protein level of less than 20 g/L and a lactate dehydrogenase level of 10 U/L. The low protein and lactate dehydrogenase levels were consistent with a transudate. The elevated glucose level, much higher than our patient's serum glucose level of 6.9 mmol/L, suggested pleuroperitoneal communication and subsequent leakage of dialysis fluid into the pleural space. We stopped the peritoneal dialysis and started temporary hemodialysis. During subsequent video-assisted thoracic surgery, multiple defects of the right diaphragm were identified and sutured. Our patient resumed continuous ambulatory peritoneal dialysis uneventfully one week later.

Hydrothorax is a well-recognized complication of peritoneal dialysis, occurring in about 1.6% to 6% of patients receiving this form of dialysis.¹⁻³ It can appear at any time during the course of peritoneal dialysis and is most often secondary to pleuroperitoneal communication. A large transudative pleural effusion, even tension hydrothorax, may develop, most frequently on the right side.^{2,4} Congestive heart failure,

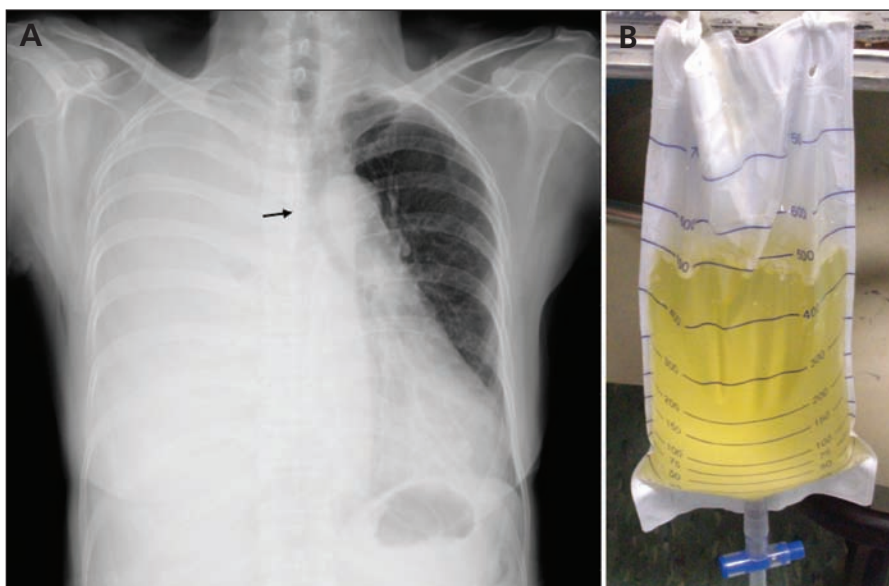


Figure 1: (A) Chest radiograph showing a large pleural effusion with a mediastinal shift to the left (arrow) in a 59-year-old woman receiving continuous ambulatory peritoneal dialysis. (B) The pleural fluid was clear and yellowish, similar to the peritoneal dialysate.

hypoalbuminemia and fluid overload should be considered in the differential diagnosis.² Thoracentesis with analysis of the pleural fluid is an important step toward the diagnosis. A high glucose level in the pleural effusion is an important clue, since no other form of hydrothorax has elevated glucose levels.² Recently, technetium-99m peritoneal scintigraphy has been used to image this condition. Video-assisted thoracic surgery permits excellent visualization of the entire parietal pleura and diaphragm during repair and pleurodesis.²

This article has been peer reviewed.

Competing interests: None declared.

REFERENCES

1. Nomoto Y, Suga T, Nakajima K, et al. Acute hydrothorax in continuous ambulatory PD — a collaborative study of 161 centers. *Am J Nephrol* 1989;9:363-7.
2. Szeto CC, Chow KM. Pathogenesis and management of hydrothorax complicating peritoneal dialysis. *Curr Opin Pulm Med* 2004;10:315-9.
3. Van Dijk CM, Ledesma SG, Teitelbaum I. Patient characteristics associated with defects of the peritoneal cavity boundary. *Perit Dial Int* 2005;25:367-73.

From the Department of Emergency Medicine, Chi-Mei Medical Center (Yang), Yung-Kang City, Tainan, and the Department of Emergency Medicine, E-Da Hospital (Liu), I-Shou University, Kaohsiung, Taiwan

CMAJ 2010. DOI:10.1503/cmaj.091464