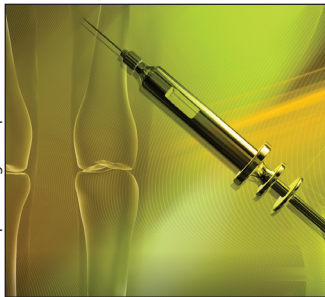

Biologics for rheumatoid arthritis

In an overview of randomized controlled trials, anakinra was less effective than adalimumab and etanercept, and etanercept was safer than adalimumab, anakinra and infliximab. Singh and colleagues came to this conclusion after reviewing updated Cochrane systematic reviews of 6 biologics for rheumatoid arthritis. Given the limitations of indirect comparisons, these findings should be used with caution, say the authors. The trials in the review were of too short duration to assess the long-term benefits and harms. **See Research, page 787**



© 2009 Jupiterimages Corp.

Interdisciplinary health research

The growing support by funding agencies of interdisciplinary research was felt to be unwarranted by 44 of 61 biomedical and clinician scientists. This is what Laberge and colleagues found using semistructured interviews. Their study also highlights the contrasting views presented by biomedical and clinician scientists. **See Research, page 797**

Self-harm and risk of motor vehicle crashes

Young drivers who reported having engaged in deliberate self-harm in the previous year were at significantly increased risk of a motor vehicle crash over next couple of years. Martiniuk and colleagues came to this conclusion from their study that prospectively linked data from a survey of more than 18 000 newly licensed drivers aged 17–24 years to data held by the traffic authority in New South Wales, Australia. The researchers were unable to discern whether a crash was because of the intention to injure or kill oneself. **See Research, page 807**



© 2009 Jupiterimages Corp.

Osteoporosis-related fractures

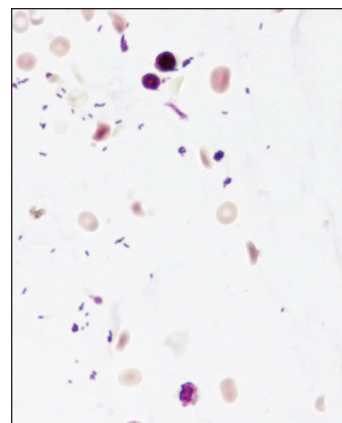
Pharmacologic agents used for the treatment of osteoporosis are effective in preventing fractures in postmenopausal women and older men, say Rahmani and Morin. The presence of a fragility fracture increases the risk of further fractures, they add. **See Review, page 815**

Bariatric surgery for severe obesity

Bariatric surgery substantially improves obesity-related comorbidities, survival and quality of life but is associated with risk of perioperative death and chronic gastrointestinal symptoms. This is one of the key messages of a commentary on the treatment of morbid obesity by Padwal and Sharma. **See Commentary, page 777**

Listeriosis in mother and child

A 28-year-old pregnant woman presented at 33 weeks' gestation with abdominal cramps and fever. The infant, delivered by cesarean section, had decreased muscle tone and reflexes and no inspiratory effort at birth. Histological examination of the placenta showed characteristic features of listeriosis. **See Practice, page 821**



Broken pacemaker lead

A 68-year-old man, with a pacemaker inserted two years ago, had dizziness after taking part in a Judo competition. A radiograph showed that the ventricular lead of his pacemaker had broken in two places. The pacemaker was replaced, and the patient took up running instead of practicing Judo. **See Clinical image, page 823**