

Smoking-cessation therapies are effective

Varenicline, bupropion and nicotine replacement therapy in the form of gum, inhaler, nasal spray, tablet or skin patch are all significantly more effective than placebo at promoting smoking abstinence at 6 and 12 months, finds a meta-analysis by Eisenberg and colleagues. **See Research, page 135**



Richard Radstone/Getty images

Most smokers who were contacted by Cunningham and Selby in a phone survey said that they would be interested in getting free nicotine replacement therapy and would use it to quit smoking. **See Research, page 145**

We have effective treatments to assist smokers in their attempts to give up

smoking, say Ebbert and Hays, but to do a better job controlling the tobacco epidemic we need to disseminate effective interventions to the population, making treatments available to smokers. **See Commentaries, page 123**

Air quality

Dales and colleagues review the quality of air in homes and discuss the role of health professionals in treating patients with respiratory and other related conditions. Homeowners can improve the quality of air with simple measures, they add. **See Review, page 147**

How useful are hospital mortality ratios?

The limitations of the hospital standardized mortality ratio as a performance measure are analyzed by Shojania and Forster. They look at the validity, precision and potential bias associated with the measure as well as its cost and capacity to promote improvement in performance. **See Analysis, page 153**



Photo courtesy of Roberto Pinto Moraes (Butantan Institute)

Caterpillar envenomation

Caterpillars induced a fatal bleeding syndrome in a 22-year-old woman returning from a trip to Peru. **See Practice, page 158**

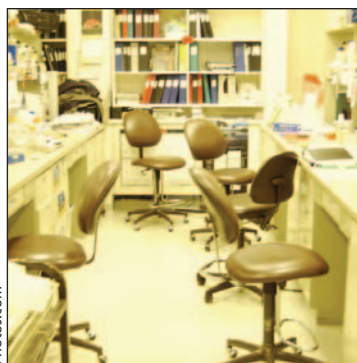
Watermelon stomach

An endoscopic image of a watermelon stomach of a 65-year-old man is featured in Practice. **See Practice, page 162**

Gallstone ileus

A computed tomography scan of the abdomen shows air in the biliary tree and a gallstone in the small intestine of an 80-year-old man who recovered after enterolithotomy. **See Clinical Images, page 203**

Shoddy laboratory medicine



Photos.com

High-profile scandals involving shoddy laboratory medicine “are regrettable situations but they have served to highlight a problem we have had for a very long time,” says Jagdish Butany, president of the Canadian Association of Pathologists. **See News, page 125**