

TEACHING CASE REPORT

A young man with deep vein thrombosis, hyperhomocysteinemia and cobalamin deficiency

The case: A 21-year-old university student presented to hospital with a 1-week history of swelling and discomfort in his right calf. Compression ultrasonography revealed occlusive thrombi in the right superficial femoral and popliteal veins. Investigations, including complete blood count, coagulation studies and renal function tests, yielded normal results. The mean corpuscular volume was elevated (106 fL). Screening for inherited thrombophilia revealed a normal factor V Leiden genotype and factor II variant genotype. Protein C, protein S, antithrombin III and anticardiolipin antibody levels were also normal. The patient was prescribed anticoagulant therapy.

The patient returned 3 months later, reporting progressive gait instability, weakness in both legs and intermittent paresthesia in his feet. He also reported that he was having increasing difficulty concentrating on his university courses and that his marks had slipped. Findings on physical examination were consistent with cobalamin (vitamin B₁₂) deficiency (Table 1). The hemoglobin concentration was 139 g/L, and the mean corpuscular volume was 108 fL. The leukocyte and platelet counts were normal. A peripheral blood smear showed round macrocytes. The serum cobalamin level was decreased (55 pmol/L), and the plasma homocysteine level was elevated (88 µmol/L). The red blood cell folate level was normal, and results of the Schilling test and a test for anti-intrinsic factor antibodies were negative.

Magnetic resonance imaging of the brain revealed atrophic changes, and fluid-attenuated inversion recovery (FLAIR) sequences showed diffuse hyperintense signal changes in the periventricular and deep subcortical

white matter involving both hemispheres (Figure 1). Magnetic resonance imaging scans of the spine were unremarkable.

Further history revealed that the patient's diet was limited to toasted oats cereal (Cheerios) without milk and to bread and french-fried potatoes. The patient admitted to a profound aversion to most foods and textures, including meat, and avoided all but a limited diet since early childhood. There were no elements suggestive of a mood, anxiety or eating disorder.

Table 1: Findings on neurologic examination of patient 3 months after initial presentation

System	Finding
Mental status	Minor difficulties with executive function
Motor function	Tone: spasticity of lower extremities Power: Medical Research Council (MRC) grade 4/5 in lower extremities Reflexes: reduced knee reflexes, absent ankle reflexes Babinski reflex: bilateral plantar response
Sensory function	Pinprick and light touch: diminished in both feet Proprioception: reduced at great toes Vibration: absent below the knees
Balance and gait	Romberg test: positive High-steppage, scissoring gait

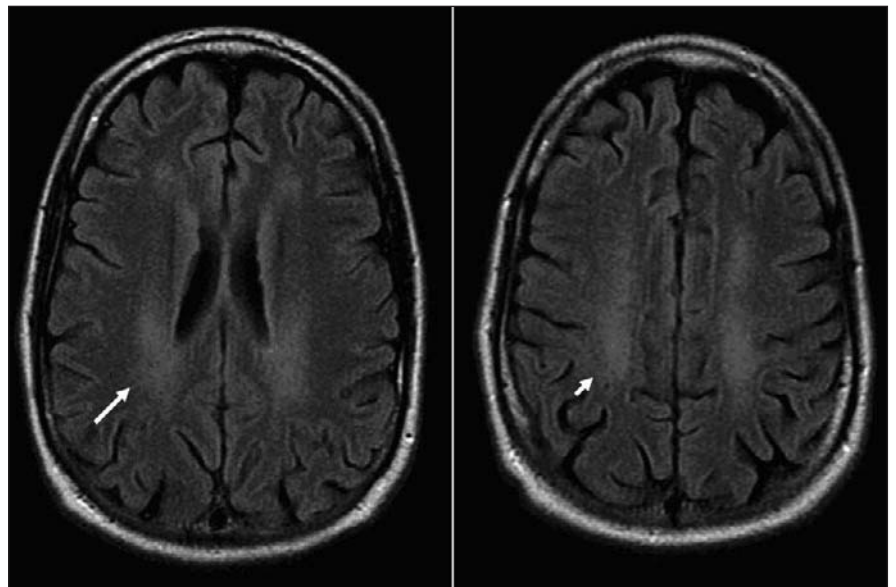


Figure 1: Magnetic resonance imaging scans of the brain, showing changes consistent with cobalamin deficiency. Fluid-attenuated inversion recovery (FLAIR) images show diffuse hyperintense signal changes in the periventricular (long arrow) and deep subcortical white matter (short arrow) involving both cerebral hemispheres. Moderate atrophy is demonstrated by sulcal widening to an extent not in keeping with the patient's age.

Box 1: Clinical features of cobalamin deficiency**Neurologic**

- Peripheral neuropathy
- Myelopathy
- Subacute combined degeneration of the dorsal and lateral spinal columns (symmetric dysesthesia, ataxia, reduced vibration and proprioception sense, reduced or absent reflexes, weakness, and spastic paraparesis affecting the lower extremities more than the upper extremities)
- Urinary or fecal incontinence
- Optic atrophy

Psychiatric

- Cognitive impairment
- Personality changes

Hematologic

- Macrocytosis
- Anemia
- Hypersegmented neutrophils
- Thrombocytopenia
- Leukopenia

Other

- Atrophic glossitis
- Icterus

The patient was given cobalamin injections daily for 1 week, followed by weekly injections for 1 month and then monthly injections. The anticoagulation therapy was continued. Eight weeks later, he reported improvement

in his gait, mood and academic performance. His motor power had increased, but his reflex and sensory abnormalities persisted. At follow-up 2 years later, all neurologic deficits had resolved. Despite psychological intervention, however, he continued to avoid most foods. He successfully completed his university degree and is now working full-time.

Cobalamin plays a vital role in the synthesis of DNA. Severe cobalamin deficiency manifests clinically as a syndrome involving either or both the neurologic and hematopoietic systems (Box 1). Although cobalamin deficiency usually presents with anemia or macrocytosis, neurologic manifestations may sometimes precede the hematologic disorder. In a series of 141 consecutive patients with neuropsychiatric abnormalities due to cobalamin deficiency, Lindenbaum and colleagues¹ found that 28% had neither anemia nor macrocytosis.¹ These observations suggest that the absence of macrocytosis or anemia does not exclude a diagnosis of cobalamin deficiency.

Serum levels of homocysteine are elevated in patients with cobalamin deficiency, owing to cobalamin's role in homocysteine metabolism (Figure 2), and usually return to normal with vitamin replacement. In their series of 141 patients, Lindenbaum and colleagues¹ noted that 36 of the 37 patients who

had their homocysteine level measured had a level above 3 standard deviations from the mean for normal controls.¹ Hyperhomocysteinemia on its own is associated with an increased risk of myocardial infarction, stroke and venous thrombosis.² However, it is unclear whether the hyperhomocysteinemia in patients with cobalamin deficiency also promotes such thrombotic complications.³ Our patient had no apparent risk factors for venous thrombosis other than the hyperhomocysteinemia associated with cobalamin deficiency. There is insufficient evidence to recommend cobalamin testing in patients with idiopathic deep vein thrombosis. An oral dose of 1000 or 2000 µg of cobalamin, initially taken daily and thereafter weekly and then monthly, may be as effective as intramuscular administration in obtaining short-term hematologic and neurologic responses in patients with cobalamin deficiency.⁴

Diets of most adults in North America provide the recommended intake of cobalamin, since it is readily found in animal foods, dairy products, eggs and fortified breakfast cereals. One serving of Cheerios, a major component of our patient's diet, contains 25% of the recommended daily allowance if purchased in the United States (www.cheerios.com/ourCereals/Cheerios/Cheerios_home.aspx) and 75% if purchased in the United Kingdom (www.cpuk.co.uk/brands/cheerios.aspx). The recommended daily al-

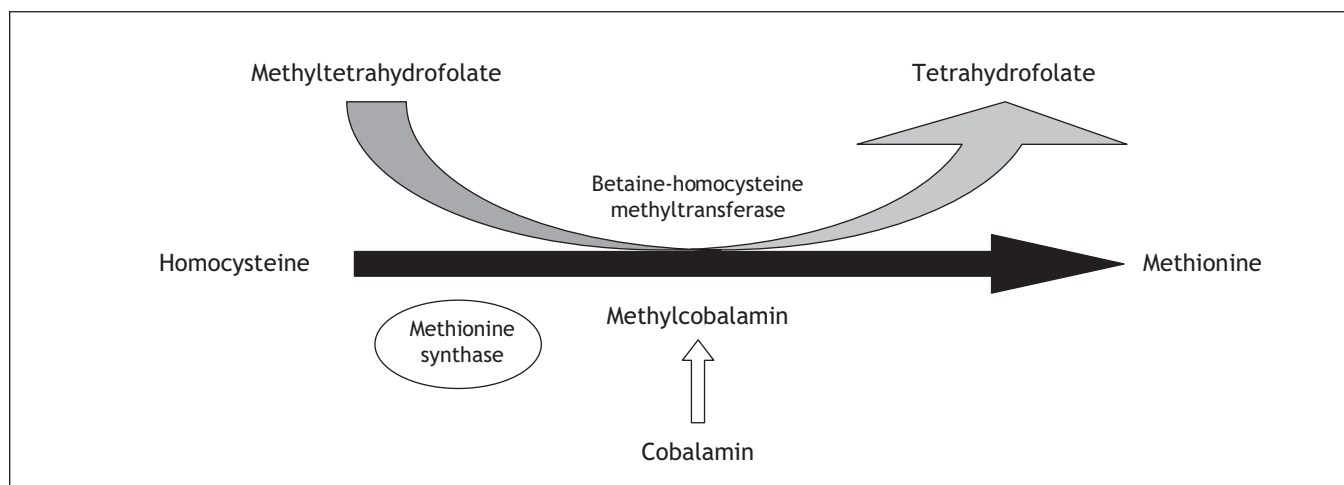


Figure 2: The role of cobalamin in homocysteine metabolism. Methylcobalamin is a cofactor in the synthesis of methionine from homocysteine. Cobalamin deficiency is characterized by elevations in serum homocysteine levels.

lowance for cobalamin is 2.4 µg in Canada and the United States, and 1.5 µg in the United Kingdom. Our patient consumed Cheerios purchased in Canada, which does not contain cobalamin (www.cheerios.ca/en/nutrition.html), since its addition to breakfast cereals is currently prohibited under section B.13.060 of the Food and Drug Regulations. A revised policy — whereby the addition of 0.4–2.4 µg per reference amount will be permitted at the discretion of manufacturers — is expected to be implemented through regulatory proposals published in the Canada Gazette Part I for comment in the near future.⁵ Interestingly, if our patient had lived in the United States or the United Kingdom, his dietary habits may not have resulted in cobalamin deficiency.

Camilla L. Wong MD
Geriatric Medicine
University of British Columbia
Vancouver, BC

Harriette G.C. Van Spall MD
Department of Cardiology
University of Toronto

Khalid A. Hassan MB
Department of Neurology
University of Toronto
Toronto, Ont.

Judith Coret-Simon MD
Department of Diagnostic Imaging
McMaster University
Hamilton, Ont.

Demetrios J. Sahlas MD
Department of Neurology
University of Toronto

Steven L. Shumak MD
Internal Medicine
University of Toronto
Toronto, Ont.

Competing interests: None declared.

REFERENCES

1. Lindenbaum J, Heaton EB, Savage DG, et al. Neuropsychiatric disorders caused by cobalamin deficiency in the absence of anemia or macrocytosis. *N Engl J Med* 1988;318:1720-8.
2. Kaplan ED. Association between homocyst(e)ine levels and risk of vascular events. *Drugs Today (Barc)* 2003;39:175-92.
3. Cantu C, Alonso E, Jara A, et al. Hyperhomocysteinemia, low folate and vitamin B12 concentrations, and methylene tetrahydrofolate reductase mutation in cerebral venous thrombosis. *Stroke* 2004;35:1790-4.
4. Vidal-Alaball J, Butler CC, Cannings JR, et al. Oral vitamin B12 versus intramuscular vitamin B12 for vitamin B12 deficiency. [Cochrane review]. *Cochrane Database Syst Rev* 2005;(3): CD004655.
5. Addition of vitamins and minerals to foods, 2005. Health Canada's proposed policy and implementation plans. Ottawa: Health Canada; 2005. Available: www.hc-sc.gc.ca/fn-an/alt_formats/hpfb-dgpsa/pdf/nutrition/fortification_final_doc_e.pdf (accessed 2007 Sept 20).

Reprints

Bulk reprints of *CMAJ* articles are available in minimum quantities of 50

For information or orders:

Reprint Coordinator

tel 800 663-7336 x2110, fax 613 565-7704

janis.murrey@cma.ca

CMAJ·JAMC

