

## TEACHING CASE REPORT

### Pediatric hypocalcemia: making the diagnosis

**Case 1:** A 2-year-old North African boy was brought to our hospital because of absent teeth development and failure to walk. The patient appeared to be well nourished and content. His body mass index was 19.1 kg/m<sup>2</sup> (90th percentile), he was 86 cm long (25th percentile) and he weighed 13.6 kg (75th percentile). Palpation of the patient's extremities revealed prominent, flared distal radii, humeri and femurs. The result of a total serum calcium test was 1.4 (normal 2.1–2.6) mmol/L.

**Case 2:** A 6-year-old boy presented with hard, nodular skin lesions on his torso. The patient was short (< 3rd percentile), and he had mild developmental delays and obesity. Because a skin biopsy demonstrated subcutaneous calcification, his total serum calcium level was measured and found to be 1.3 mmol/L.

**Case 3:** A 12-year-old boy presented with concerns about intermittent numbness of his extremities. He reported having had 1 episode where he "lost control" of his right leg and fell. A CT scan showed calcification of the basal ganglia. His total serum calcium level was 1.5 mmol/L.

There is limited epidemiologic data on pediatric hypocalcemia, and the most common causes vary by developmental stage. For example, the incidence of neonatal hypocalcemia may be as high as 50% in infants born to mothers with diabetes.<sup>2</sup> There are also elevated risks, although more moderate, associated with winter and spring births, prolonged breastfeeding, lower socioeconomic status and low maternal vitamin D intake during pregnancy.<sup>2</sup> All pre-pubertal children of African, Asian and Middle Eastern descent appear to have increased risk of hypocalcemia because of inefficient

formation of vitamin D precursors in pigmented skin.<sup>3</sup>

Hypocalcemia in children may be asymptomatic or there may be a wide range of signs and symptoms (Box 1). Because very young patients cannot accurately verbalize symptoms, they are more likely to present with signs such as weakness, feeding problems, facial spasms, jitteriness or seizures.<sup>2</sup> In addition, features of conditions known to be associated with hypocalcemia may be identified (Table 1).

There are multiple causes of hypocalcemia in children; thus, diagnosis must follow a systematic approach. Fortunately, primary care physicians can use widely available laboratory tests to begin the diagnostic process. Since pediatric hypocalcemia can represent the first manifestation of a genetic disorder, a definitive diagnosis may eventually require further testing at a specialized centre.

Under normal circumstances, cal-

#### Box 1: Selected clinical features of hypocalcemia

- Laryngospasm
- Tetany
- Infant feeding problems
- Muscle cramps (especially with exercise)
- Seizure
- Paresthesia
- Numbness
- Chvostek's sign
- Trousseau's sign
- Lengthened QTc interval (> 450 milliseconds)

cium homeostasis maintains total calcium levels within the narrow range of 2.1–2.6 mmol/L (ionized calcium 1.0–1.3 mmol/L).<sup>1</sup> The first step in maintaining a healthy calcium balance is adequate dietary intake of calcium. Normal intake of breast milk or infant formula supplies age-appropriate amounts of calcium. Older children require a balanced diet that provides 500 mg (children aged 1–3 years), 800 mg (4–8 years) or

**Table 1:** Selected conditions associated with hypocalcemia

| Clinical feature  | Potential underlying cause   |
|---|--|
| Impaired growth   | <ul style="list-style-type: none"> <li>• Rickets (all types)</li> <li>• Syndromes associated with hypoparathyroidism</li> <li>• Malabsorptive state (impaired vitamin D and calcium absorption)</li> </ul> |
| Heart murmur  | <ul style="list-style-type: none"> <li>• DiGeorge's syndrome (cardiac malformation, thymic hypoplasia, hypoparathyroidism)</li> </ul>  |
| Bone abnormalities                                      | <ul style="list-style-type: none"> <li>• Rickets (all types)</li> <li>• Certain rare syndromes</li> </ul>  |
| Developmental delay                                     | <ul style="list-style-type: none"> <li>• Syndromes associated with hypoparathyroidism</li> </ul>   |
| Mucocutaneous candidiasis, adrenal insufficiency        | <ul style="list-style-type: none"> <li>• Autoimmune polyendocrinopathy causing hypoparathyroidism</li> </ul>   |
| Lymphadenopathy, hepatosplenomegaly                     | <ul style="list-style-type: none"> <li>• Tumour lysis syndrome secondary to underlying malignancy</li> </ul>   |
| Neck scar   | <ul style="list-style-type: none"> <li>• Previous thyroid surgery with iatrogenic hypoparathyroidism</li> </ul>  |
| Round face, obesity, brachydactyly, developmental delay | <ul style="list-style-type: none"> <li>• Albright's hereditary osteodystrophy (pseudohypoparathyroidism)</li> </ul>  |

1300 mg (> 8 years) of calcium daily. One cup of milk contains about 300 mg of calcium.<sup>4</sup>

Calcium homeostasis depends on multiple interacting organ systems (Figure 1). The parathyroid glands sense hypocalcemia via membrane-bound receptors and rapidly generate parathyroid hormone. [Release of parathyroid hormone requires adequate magnesium levels.] Once released, the hormone promotes a shift from net bone formation to calcium-liberating bone resorption. In the kidneys, parathyroid hormone upregulates retention of urinary calcium and enhances renal activation of potent 1,25-dihydroxy vitamin D, whose major role is to increase intestinal calcium absorption. Formation of 1,25-dihydroxy vitamin D requires adequate amounts of precursor vitamin D from diet or exposure to UV light. Finally, normalization of calcium feeds back to

inhibit parathyroid hormone secretion.<sup>5</sup>

Most pediatric endocrinologists use a panel of investigations to create a snapshot of calcium homeostasis in order to diagnose hypocalcemia (Box 2). This approach enables determination of the level of each mineral or enzyme

in relation to the others. This is in contrast with the stepwise investigations implied by some textbook algorithms.

Once hypocalcemia has been confirmed and the panel results are available, the result can be interpreted in their physiologic context (Figure 2).

#### Box 2: An approach to diagnosing pediatric hypocalcemia

- Obtain a complete patient history and perform a physical examination to detect clinical features of hypocalcemia or those that may point to a specific underlying disorder.
- Confirm the diagnosis of hypocalcemia by measuring total serum calcium and albumin simultaneously or by measuring ionized serum calcium (hypoalbuminemia can cause “factitious” hypocalcemia).
- If the diagnosis is confirmed, order a serum hypocalcemic panel (calcium, phosphate, magnesium, creatinine, alkaline phosphatase, parathyroid hormone, 25-hydroxyvitamin D) and test the ratio of calcium to creatinine in the patient’s urine.
- Order a test for serum 1,25-dihydroxyvitamin D. However, this test is of limited clinical usefulness outside specialized clinics because of slow laboratory turnaround and variable assay quality.

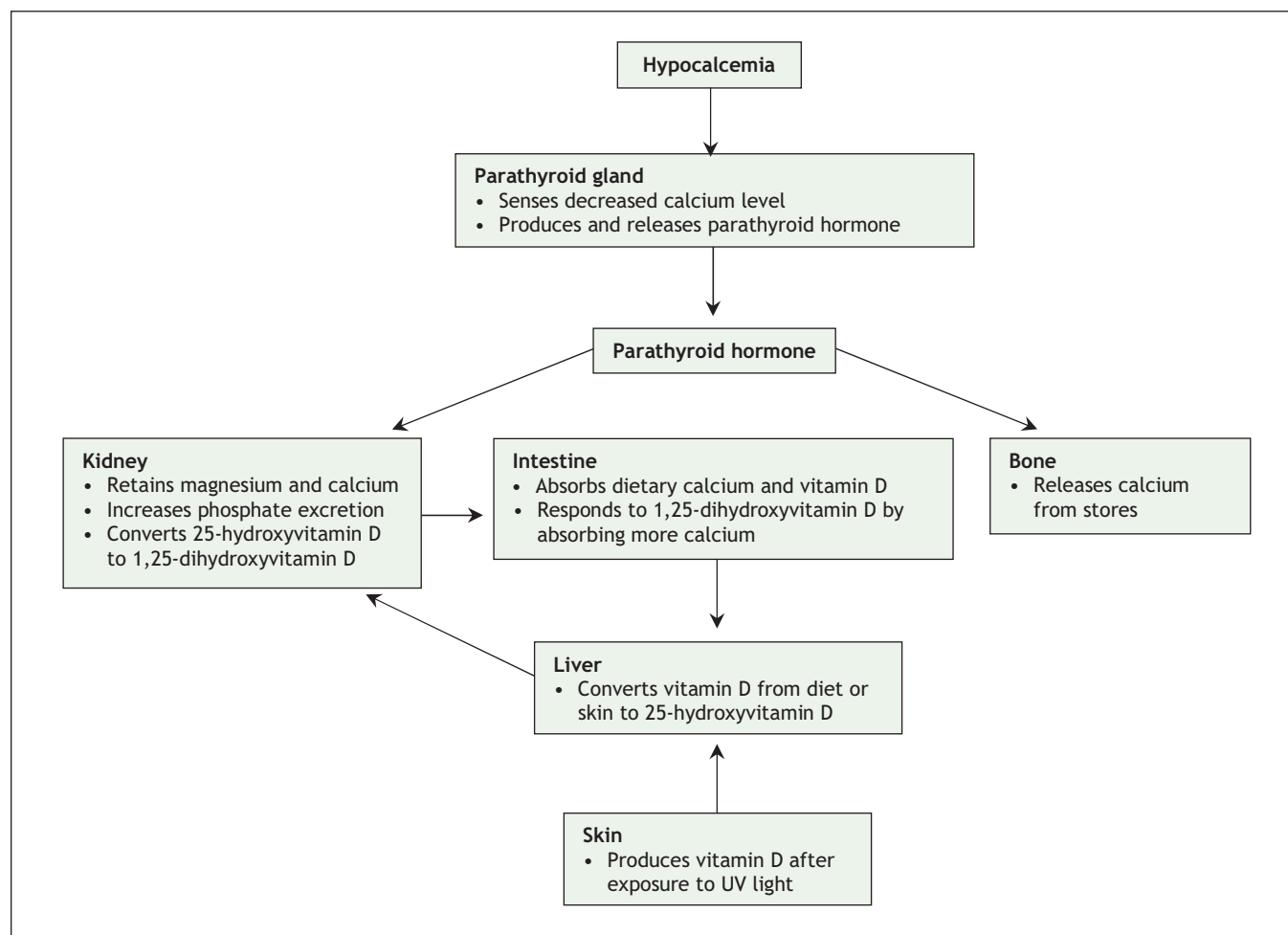
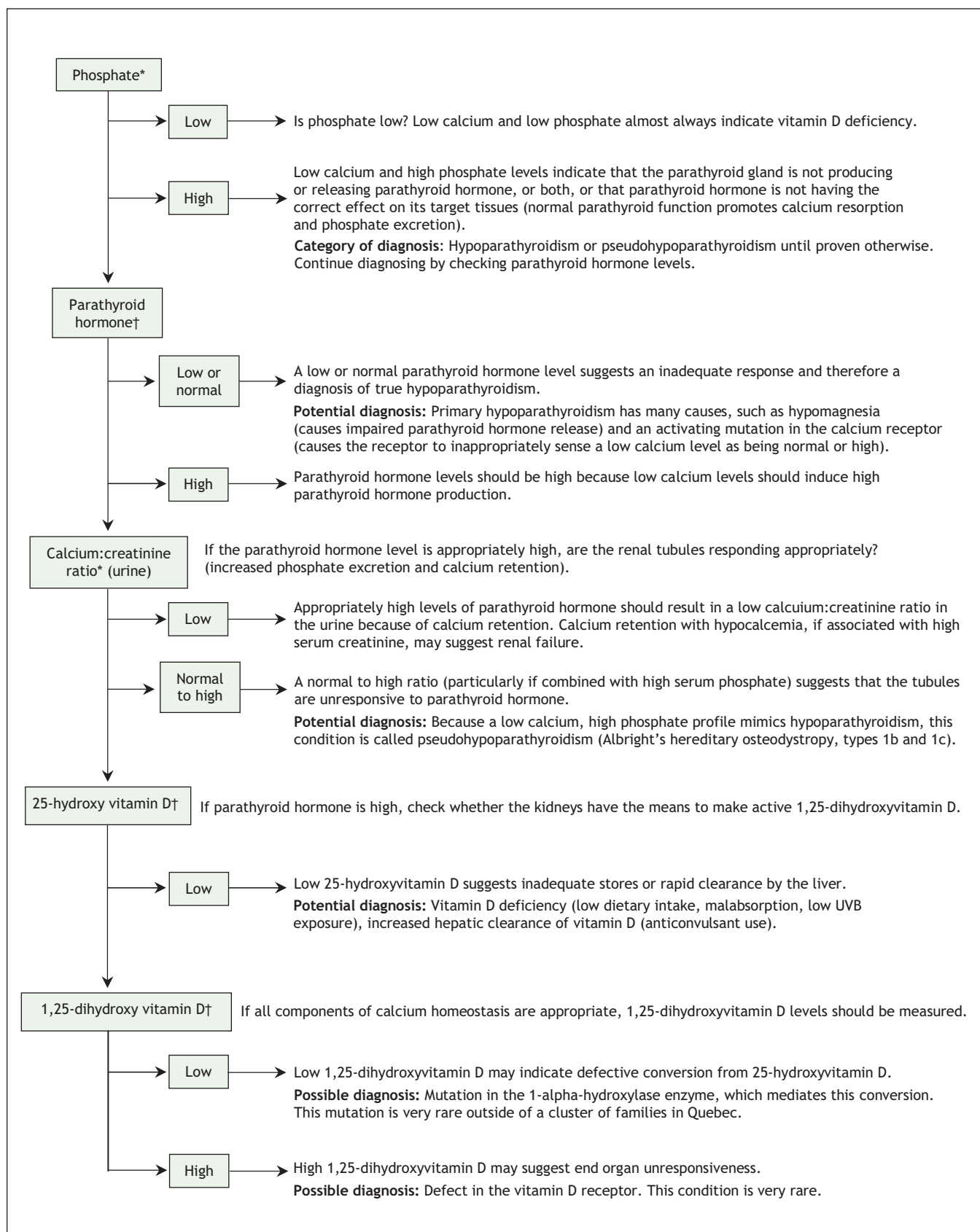


Figure 1: Overview of calcium homeostasis.



**Figure 2:** An approach to interpreting the results of a pediatric calcium panel in the context of hypocalcemia. \*Reference values vary with age. †Reference values vary with laboratory and assay.

## Applying a diagnostic approach

**Case 1:** This patient was found to have low serum calcium, phosphate and 25-hydroxyvitamin D, as well as high levels of parathyroid hormone.

A combination of factors, including the patient's ethnic background, low milk intake and the results of his physical examination, raised the likelihood of vitamin D-deficiency rickets. The results of laboratory tests confirmed this diagnosis.

**Case 2:** The second patient's serum had high levels of phosphate and very high levels of parathyroid hormone. Test results also revealed normal 25-hydroxyvitamin D levels and a high ratio of calcium to creatinine in his urine.

A laboratory profile that is consistent with hypoparathyroidism except for a high level of parathyroid hormone supports a diagnosis of pseudohypoparathyroidism. This patient also had a short stature, obesity, a round face and brachydactyly of his fourth and

fifth fingers. These are all features of Albright's hereditary osteodystrophy, a disorder in which a maternally inherited mutated copy of the *GNAS1* gene leads to parathyroid-hormone resistance.

**Case 3:** This patient had high levels of phosphate but normal levels of magnesium and parathyroid hormone

The results of laboratory investigations supported a diagnosis of hypoparathyroidism. A subsequent genetic workup identified a rare activating mutation of the calcium receptor. This mutation causes the receptor to inappropriately sense low calcium levels as being normal.

## Teaching points

Once a diagnosis of hypocalcemia has been made, a systematic workup that includes a panel of blood tests can help sort out what may otherwise be a confusing clinical picture. Hypocalcemia in children can be an early presentation of a genetic syndrome, and a systematic approach can facilitate

referral for definitive diagnosis and treatment.

**Jonathan Dawrant MD BSc**  
**Danièle Pacaud MD**  
 Department of Pediatrics  
 Alberta Children's Hospital  
 Calgary, Alta.

This article has been peer reviewed.

**Competing interests:** None declared.

## REFERENCES

1. Kruse K. Vitamin D and parathyroid. In: Ranke MB, editor. *Diagnostics of endocrine function in children and adolescents*. 3rd ed. Basel (Switzerland): Karger; 2003. p. 240.
2. Diamond Jr. Frank B., Root AW. Pediatric endocrinology. In: Sperling MA, editor. *Pediatric endocrinology*. 2nd ed. Philadelphia: Saunders; 2002. p. 97.
3. Primary vitamin D deficiency in children. *Drug Ther Bull* 2006;44:12-6.
4. Health Canada. Food and nutrition. Dietary reference intakes: reference values for elements. Ottawa; Health Canada: 2005. Available: [www.hc-sc.gc.ca/fn-an/nutrition/reference/table/ref\\_elements\\_tbl\\_e.html](http://www.hc-sc.gc.ca/fn-an/nutrition/reference/table/ref_elements_tbl_e.html) (accessed 2007 Oct 15).
5. Spiegel AM. The parathyroid glands, hypercalcemia and hypocalcemia. In: Goldman L, Ausiello D, editors. *Cecil textbook of medicine*. 22nd ed. Philadelphia: W.B. Saunders; 2004.