

Case report

Severe necrotizing pancreatitis following combined hepatitis A and B vaccination

Eran Shlomovitz, Ward Davies, Ewa Cairns, William C. Brintnell, Mark Goldszmidt, George K. Dresser

ABSTRACT

Necrotizing pancreatitis is a severe form of pancreatitis and is associated with substantial morbidity and mortality. We report a case of necrotizing pancreatitis that developed following combined hepatitis A and B vaccination. No other causes of pancreatitis could be determined. Although confirming the diagnosis is challenging, 3 main factors suggest a possible link to the vaccine: the chronology of the events, the patient's human leukocyte antigen genotype and the incongruent immune response to the vaccine components. This report serves to alert physicians to the possible development of necrotizing pancreatitis after vaccination.

CMAJ 2007;176(3):339-42

The causes of acute pancreatitis are well documented, with alcohol and gallstones among the most common. Viruses such as mumps, Coxsackie B, measles, Epstein-Barr and hepatitis A, B and E can also cause acute pancreatitis.¹ Furthermore, the pancreas is a target organ for the hepatitis B virus.² An autoimmune trigger may be the cause of some cases of pancreatitis;³ however, accurately diagnosing autoimmune pancreatitis can be challenging because of its variable characteristics and clinical presentations.⁴ Vaccine-induced pancreatitis may be a subset of this immunologically driven phenomenon, as is suggested by several reports of pancreatitis following vaccination against hepatitis A⁵ and other viruses.⁶⁻⁸ Necrotizing pancreatitis accounts for 5% of all cases of acute pancreatitis and is far more severe than the more common interstitial pancreatitis. Necrotizing pancreatitis can be distinguished by extensive necrosis of peripancreatic fat in the omentum and retroperitoneum. We report a case of necrotizing pancreatitis that occurred after combined hepatitis A and B vaccination.

Case

A 63-year-old man was administered a combined hepatitis A and B vaccination intramuscularly. The accelerated vaccination protocol was followed: the vaccine was administered on

days 0, 7 and 21, with a planned booster vaccination 1 year later. The patient was clinically asymptomatic until 3 weeks after the third dose of vaccine was administered, at which point he presented to hospital with severe vomiting and epigastric pain. The patient was a healthy and active man who did not consume alcohol and had no known chronic or autoimmune conditions. He did not use any natural health products, nor did he use any oral, nasal or intravenous medications. He had no history of drug abuse or blood transfusions, nor any history of pancreatitis, recent illnesses, viral prodromes or contact with ill people. On examination the patient's vital signs were stable, and he was afebrile. Further physical examination was unremarkable except for epigastric tenderness. The patient's body mass index was calculated to be 25 kg/m². The results of blood work, serology and immunology tests supported a diagnosis of pancreatitis (Table 1, Table 2). Blood and urine cultures showed no growth. Abdominal ultrasound and CT scans (Fig. 1) as well as endoscopic retrograde cholangiopancreatography ruled out other causes of pancreatitis such as gallstones, pancreatic neoplasms and rare congenital anomalies such as pancreatic divisum. The patient was admitted to hospital for 30 days in a tertiary care centre. The results of seroconversion tests performed 3 months after vaccination showed evidence of hepatitis A immunity, but a lack of immunity to hepatitis B.

Despite medical management, the patient's clinical condition deteriorated during his stay in the hospital, and the decision was made to surgically débride the pancreas. Histologic examination of the débrided tissue revealed complete destruction of the cellular components consistent with necrotizing pancreatitis. Unfortunately, because of the extent of tissue necrosis we were unable to perform immunohistochemical analysis. The patient's human leukocyte antigen (HLA) genotype was determined after discharge: HLA-DRB1*0401,0401 (DR4, DR4); HLA-DQB1*0301, 0302 (DQ7, DQ8); HLA-DRB4 (DR53), HLA-A*02, 29; HLA-B*44, 44; and HLA-Cw*05, 16. At a 6-month follow-up, the patient was doing well with no apparent sequelae.

Comments

We present here a case of acute necrotizing pancreatitis in a

person who had recently received a combined hepatitis A and B vaccine. Extensive patient history as well as laboratory and imaging investigations did not reveal any known precipitants of pancreatitis. In this case, the temporal relation between the vaccination and the onset of necrotizing pancreatitis suggests that the events are associated. In addition, the patient's HLA genotype and the incongruent immune response to the vaccine components suggest a link.

Although the exact mechanism linking vaccination and acute pancreatitis is unknown, numerous potential explanations have been suggested. Some authors postulate that the activation of pancreatic zymogens by serum factors can initiate acinar cell injury.⁹ Heterophilic reactivity, or "molecular mimicry," has also been suggested with respect to the hepatitis B vaccine.¹⁰ Vaccines have been shown to induce the production of autoantibodies in several animal models.¹¹⁻¹³ In this theory, immunologic injury may be caused by a cytotoxic antibody system that has a heterophilic reactivity to acinar cells.⁹ There are also suggestions in the literature of several additional mechanisms of immunologic injury such as polyclonal activation (adjuvant reaction) of lymphocytes, "bystander activation" of self-reactive lymphocytes or somatic mutation of immunoglobulin variable genes.¹⁴ Additional mechanisms could include secondary pancreatitis caused by vaccine-induced vasculitis or the release of anaphylactic me-

diators such as histamine and leukotrienes induced by vaccine antigens.⁵

In previous cases in which vaccination was suspected to have caused pancreatitis,⁵⁻⁸ the link was proposed largely because of the temporal association between vaccination and the onset of symptoms, which was reported to be as long as several weeks to months.¹⁴ In the present case, pancreatitis developed within 3 weeks following the third dose of the vaccine. This is clearly within the time period when adverse reactions would be expected to occur. Furthermore, positive rechallenge symptoms as well as exacerbation of symptoms upon repeat exposure have previously been observed after hepatitis B vaccination.^{8,15} This may suggest that a period of subclinical pancreatitis occurs before the onset of severe clinical symptoms.

The HLA genotype of our patient suggests that he may have been genetically predisposed to an autoimmune reaction to the hepatitis B vaccine. The expression of the MHC class II alleles HLA-DRB1*0401 and HLA-DQB1*0301 has been found to be associated with development of an autoimmune disease

Table 1: Results of blood work at presentation

Component	Result	Reference
Leukocyte count, $\times 10^9/L$	21.0	4.0-11.0
Hemoglobin, g/L	166	130-175
Platelet count, $\times 10^9/L$	319	140-400
Mean corpuscular volume, fl	88	78-98
Neutrophil count, $\times 10^9/L$	16.4	2.1-7.5
Lymphocyte count, $\times 10^9/L$	3.6	1.1-3.9
Monocyte count, $\times 10^9/L$	0.8	0.1-0.8
Basophil count, $\times 10^9/L$	0.2	0.0-0.2
Sodium, mmol/L	143	135-147
Potassium, mmol/L	4.8	3.5-5.0
Chloride, mmol/L	102	96-106
Carbon dioxide, mmol/L	29	22-31
Anion gap, mmol/L	12	8-15
Glucose (random), mmol/L	7.9	3.9-6.1
Urea, mmol/L	6.1	3.0-7.0
Creatinine, $\mu\text{mol/L}$	87	50-110
Pancreatic isoamylase, U/L	1778	< 55
Calcium (corrected), mmol/L	2.4	2.12-2.62
Bilirubin (total), $\mu\text{mol/L}$	11	1-17
Gamma-glutamyl transferase, U/L	30	5-50
Alkaline phosphatase, U/L	69	40-130
Aspartate transaminase, U/L	31	5-40
Alanine transaminase, U/L	29	5-60

Table 2: Results of serologic and immunologic investigations

Component	No. of days*	Result	Reference
C-reactive protein, mg/L	9	189.7	≤ 7.50
Hepatitis A IgM antibodies	19	Negative	—
Hepatitis B core IgM antibodies	19	Negative	—
Hepatitis A IgG antibodies	29	Positive	—
Hepatitis B surface antigens	29	Negative	—
Hepatitis B surface antibodies, U/ml	29	4	< 10
Hepatitis B core antibodies	29	Negative	—
IgG total, g/L	30	14.8	6.4-13.8
IgA, g/L	30	4.8	0.8-4.6
IgM, g/L	30	0.9	0.6-2.7
Anti-myeloperoxidase (pANCA), U/mL	70	< 1.0	< 7
Anti-proteinase 3 (cANCA), U/mL	70	< 1.0	< 7
Rheumatoid factor, U/mL	70	< 21	≤ 21
C3, g/L	70	1.50	0.66-1.68
C4, g/L	70	0.20	0.10-0.40
Antinuclear antibodies	70	Negative	—
Anti-islet cell antibodies	397	Negative	—

Note: pANCA = perinuclear antineutrophil cytoplasmic antibodies, cANCA = cytoplasmic antineutrophil cytoplasmic antibodies, C3 = complement 3, C4 = complement 4.

*Number of days between patient admission and investigation.

after hepatitis B vaccination.¹⁶⁻¹⁸ Furthermore, an increased frequency of the HLA-Cw5, HLA-B44 and DR4 genotype was reported in patients who had chronic pancreatitis.¹⁹ Schuenke and colleagues demonstrated that the nonresponder HLA-DR allele DRB1*0401 has a significantly higher affinity than responder alleles to an immunodominant hepatitis B surface antigen (HBsAg): it is postulated that nonresponder alleles may be associated with aberrant T-cell responses.²⁰ The expression of HLA alleles encoding autoimmune susceptibility may increase the probability of cross-reactive immune cells becoming activated, which in turn may induce an autoimmune reaction.¹⁷

Both the routine and accelerated protocol for combined hepatitis A and B vaccination have been shown to induce a strong immune response to a dual threat.²¹⁻²⁶ In the present case, seroconversion was tested 2 months after the third dose of the vaccine was administered (about 3 months after the initial dose) and showed that immunity had developed to hepatitis A but not to hepatitis B. After 3 months, the expected rate of hepatitis B seroprotection achieved by either vaccination schedule is about 95.2%.^{27,28} The incongruent immune response seen in this patient decreases the likelihood that the lack of hepatitis B seroprotection was due to a generalized reduction in immune response and may suggest an underlying immune mechanism related to the hepatitis B component of the vaccine.

A weakness in this theory is related to the age and sex of the patient. Several studies have demonstrated decreased immunogenicity associated with increased age, smoking, obesity, male sex and the presence of a chronic disease. In

higher age groups, the expected seroprotection rate is between 84% and 88.9%.^{29,30} In these studies, however, the vast majority (89%) of patients who lacked a hepatitis B response were considered to be either overweight or obese. Based on the available data and the fact that the patient in the present case was a healthy nonsmoker with a body mass index of 25 kg/m², it is more likely that the lack of hepatitis B response was related to an underlying immune mechanism rather than a random nonresponse.

Vaccine-induced pancreatitis is likely an underdiagnosed condition and may often be masked by the incidental presence of more commonly recognized causes, or it may simply be misdiagnosed as idiopathic pancreatitis. Since we were unable to rule out all possible, yet rare, causes of pancreatitis, it is not possible to establish a direct causal relation between vaccination and pancreatitis; however, this report can be used to alert practitioners to the rare possibility of necrotizing pancreatitis after combined hepatitis A and B vaccination.

This article has been peer reviewed.

From the General Surgery Residency Program (Shlomovitz), Department of Surgery, University of Toronto, Toronto; the Divisions of General Surgery (Davies), General Internal Medicine (Dresser, Goldszmidt), Clinical Pharmacology (Dresser) and Rheumatology (Cairns, Brintnell), and the Departments of Surgery (Davies), Immunology and Microbiology (Cairns, Brintnell) and Medicine (Dresser, Goldszmidt), London Health Sciences Centre, University of Western Ontario, London, Ont.

Competing interests: None declared.

Contributors: All of the study authors made a significant and substantial contribution to the acquisition, analysis and interpretation of the data. Furthermore, all authors were closely involved in the process of drafting, revising and approving the final version of this article.

Acknowledgement: We thank Dr. Gabriele C. DeLuca for his insightful comments and suggestions.

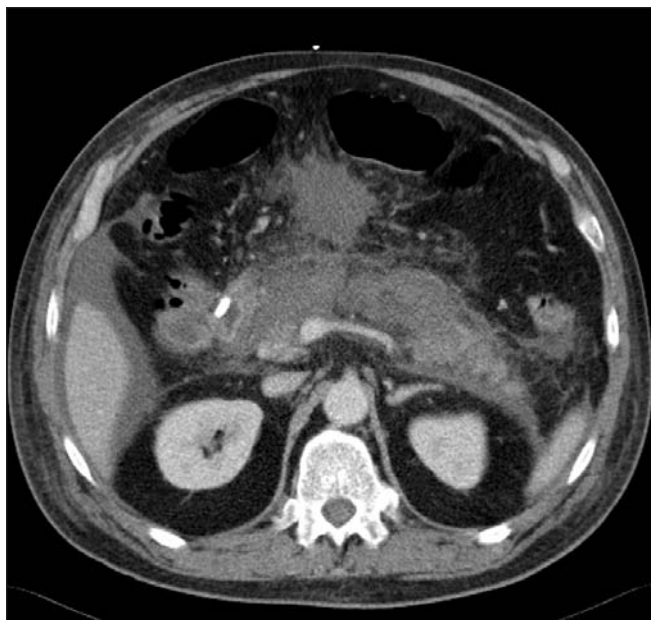


Fig. 1: A contrast-enhanced CT scan at the level of splenic vein. The pancreatic head demonstrates heterogeneous enhancement with peripancreatic fat stranding and the pancreatic neck and body are replaced by a complex collection of non-enhancing tissue. Findings are consistent with phlegmonous pancreatitis with pancreatic necrosis.

REFERENCES

- Mishra A, Saigal S, Gupta R, et al. Acute pancreatitis associated with viral hepatitis: a report of six cases with review of literature. *Am J Gastroenterol* 1999;94:2292-5.
- Hohenberger P. [The pancreas as target organ for hepatitis B virus — immunohistological detection of HBsAg in pancreatic carcinoma and chronic pancreatitis]. *Leber Magen Darm* 1985;15:58-63.
- Sarles H, Sarles JC, Muratore R, et al. Chronic inflammatory sclerosis of the pancreas — An autonomous pancreatic disease? *Am J Dig Dis* 1961;6:688-98.
- Sahel J, Barthet M, Gasmi M. Autoimmune pancreatitis: increasing evidence for a clinical entity with various patterns. *Eur J Gastroenterol Hepatol* 2004;16:1265-8.
- Haviv YS, Sharkia M, Galun E, et al. Pancreatitis following hepatitis A vaccination. *Eur J Med Res* 2000;5:229-30.
- Feldman G, Zer M. Infantile acute pancreatitis after mumps vaccination simulating an acute abdomen. *Pediatr Surg Int* 2000;16:488-9.
- Adler JB, Mazzotta SA, Barkin JS. Pancreatitis caused by measles, mumps, and rubella vaccine. *Pancreas* 1991;6:489-90.
- Gatt DT. Pancreatitis following monovalent typhoid and cholera vaccinations. *Br J Clin Pract* 1986;40:300-1.
- Janigan DT, Nevalainen TJ, MacAulay MA, et al. Foreign serum-induced pancreatitis in mice. I. A new model of acute pancreatitis. *Lab Invest* 1975;33:591-607.
- Marshall E. A shadow falls on hepatitis B vaccination effort. *Science* 1998;281:630-1.
- Hogenesch H, Azcona-Olivera J, Scott-Moncrieff C, et al. Vaccine-induced autoimmunity in the dog. *Adv Vet Med* 1999;41:733-47.
- Murphy-Ullrich JE, Oberley TD, Mosher DF. Detection of autoantibodies and glomerular injury in rabbits immunized with denatured human fibronectin monomer. *Am J Pathol* 1984;117:1-11.
- Abrahamson DR, Caulfield JP. Proteinuria and structural alterations in rat glomerular basement membranes induced by intravenously injected anti-laminin immunoglobulin G. *J Exp Med* 1982;156:128-45.
- Shoenfeld Y, Aron-Maor A. Vaccination and autoimmunity — “vaccinosis”: A dangerous liaison? *J Autoimmun* 2000;14:1-10.

15. Geier MR, Geier DA. A case-series of adverse events, positive re-challenge of symptoms, and events in identical twins following hepatitis B vaccination: analysis of the Vaccine Adverse Event Reporting System (VAERS) database and literature review. *Clin Exp Rheumatol* 2004;22:749-55.
16. Pope JE, Stevens A, Howson W, et al. The development of rheumatoid arthritis after recombinant hepatitis B vaccination. *J Rheumatol* 1998;25:1687-93.
17. Miller JD, Whitehair LH. Concurrent HLA-related response factors mediate recombinant hepatitis B vaccine major adverse events. *Autoimmunity* 2005;38:181-94.
18. Mineta M, Tanimura M, Tana T, et al. Contribution of HLA class I and class II alleles to the regulation of antibody production to hepatitis B surface antigen in humans. *Int Immunol* 1996;8:525-31.
19. Forbes A, Schwarz G, Mirakian R, et al. HLA antigens in chronic pancreatitis. *Tissue Antigens* 1987;30:176-83.
20. Schuenke KW, Cook RG, Rich RR. Binding specificity of a class II-restricted hepatitis B epitope by DR molecules from responder and nonresponder vaccine recipients. *Hum Immunol* 1998;59:783-93.
21. Abraham B, Parenti D. Antibody production in response to hepatitis B surface antigen in a combination hepatitis A/hepatitis B vaccine. *J Infect Dis* 2000;182:1005-6.
22. Greub G, Genton B, Safary A, et al. Comparison of the reactogenicity and immunogenicity of a two injection combined high-dose hepatitis A and hepatitis B vaccine to those of Twinrix. *Vaccine* 2000;19:1113-7.
23. Abraham B, Baine Y, De-Clercq N, et al. Magnitude and quality of antibody response to a combination hepatitis A and hepatitis B vaccine. *Antiviral Res* 2002;53:63-73.
24. Joines RW, Blatter M, Abraham B, et al. A prospective, randomized, comparative US trial of a combination hepatitis A and B vaccine (Twinrix) with corresponding monovalent vaccines (Havrix and Engerix-B) in adults. *Vaccine* 2001;19:4710-9.
25. Murdoch DL, Goa K, Figgitt DP. Combined hepatitis A and B vaccines: a review of their immunogenicity and tolerability. *Drugs* 2003;63:2625-49.
26. Van Damme P, Van Herck K. A review of the efficacy, immunogenicity and tolerability of a combined hepatitis A and B vaccine. *Expert Rev Vaccines* 2004;3:249-67.
27. Nothdurft HD, Dietrich M, Zuckerman JN, et al. A new accelerated vaccination schedule for rapid protection against hepatitis A and B. *Vaccine* 2002;20:1157-62.
28. Nothdurft HD, Dietrich M, Zuckerman JN, et al. Rapid protection against hepatitis A and B using an accelerated vaccination schedule: comparison of combined vaccine, Twinrix, with separate vaccines. *BioDrugs* 2003;17(Suppl 1):15-8.
29. Averhoff F, Mahoney F, Coleman P, et al. Immunogenicity of hepatitis B vaccines. Implications for persons at occupational risk of hepatitis B virus infection. *Am J Prev Med* 1998;15:1-8.
30. Stoffel M, Lievens M, Dieussaert I, et al. Immunogenicity of Twinrix in older adults: a critical analysis. *Expert Rev Vaccines* 2003;2:9-14.

Correspondence to: Dr. Eran Shlomovitz, General Surgery Residency Program, Department of Surgery, University of Toronto, Rm 440, Mount Sinai Hospital, 600 University Ave, Toronto ON M5G 1X5; eran.shlomo@gmail.com.

LEADERSHIP

CMAJ is a founding member of the International Committee of Medical Journal Editors, an organization that is devoted to ensuring the highest integrity in scientific publishing and is a driving force in the mandatory registration of clinical trials.