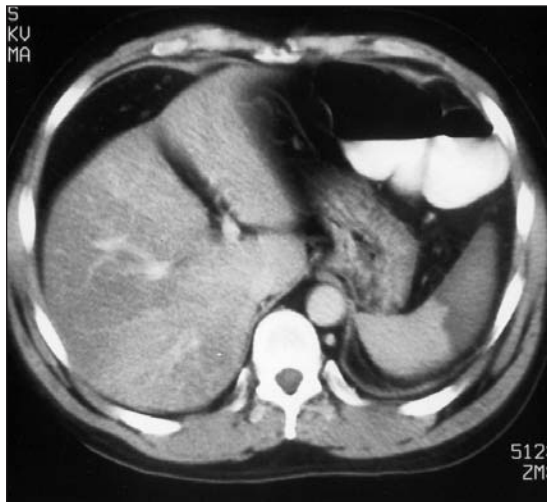
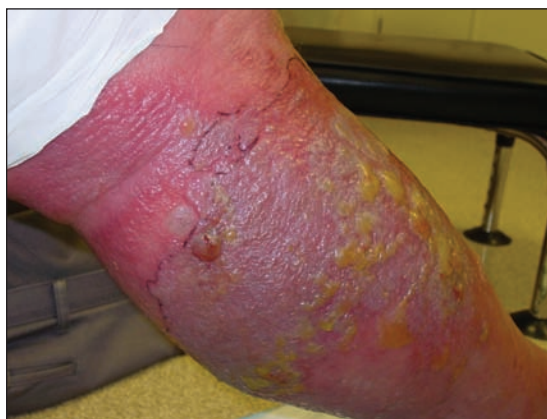

CLINICAL VISTAS BRIEFS

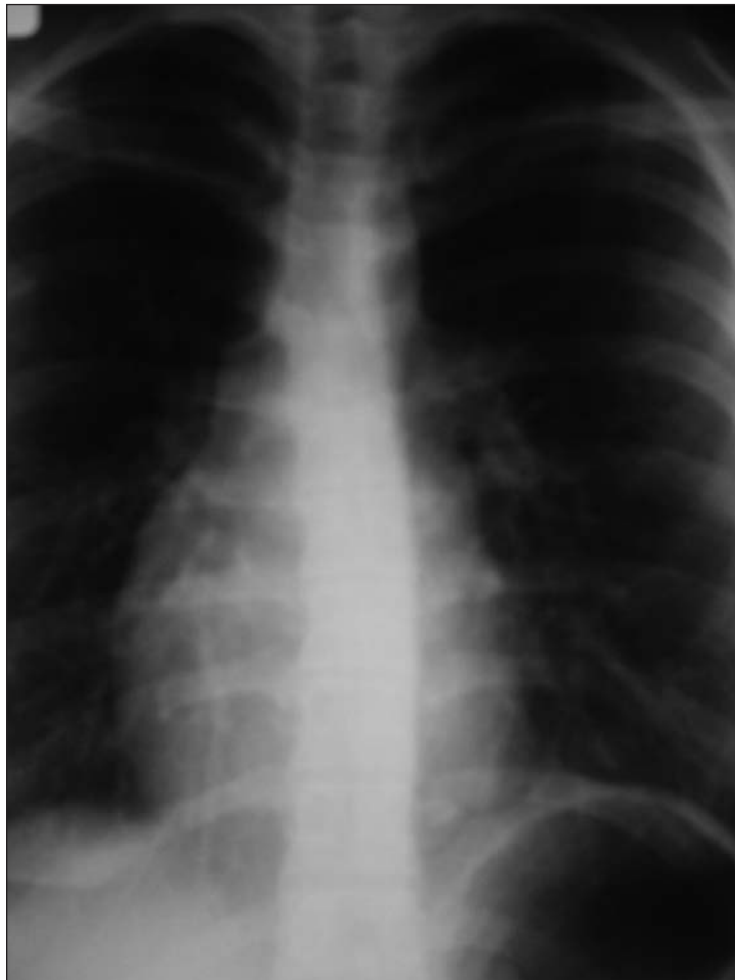What's your call?



A 41-year-old East Indian man arrived at hospital complaining of acute pain in his lower-left abdominal quadrant; an examination revealed some tenderness in that area, low-grade fever, leukocytosis and neutrophilia. An abdominal CT scan with contrast was ordered. What's your diagnosis?



A 57-year-old man with type 2 diabetes with blistering on his lower limb, which began 4 days after he was treated with cefazolin and probenecid for acutely painful erythema (accompanied by fever and nausea) that had been diagnosed as cellulitis.



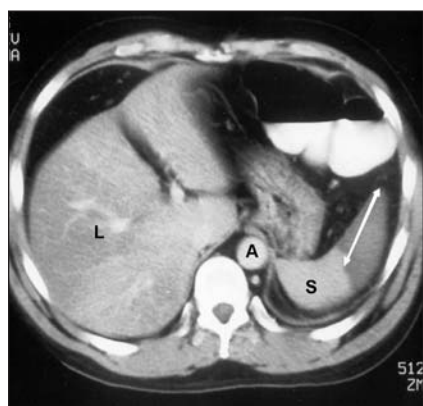
Routine chest radiograph of an asymptomatic 17-year-old girl.

See page 247 for diagnoses.

CLINICAL VISTAS BRIEFS

Acute splenic infarction

Although no intense pelvic symptoms were found during the physical exam, the CT scan showed a wedge-like hypodense area in the spleen (Fig. 1, arrow) consistent with acute splenic infarction. Results of a hypercoagulable work-up were normal. Electrophoresis revealed hemoglobin S at 40%, consistent with heterozygous sickle cell trait. The patient was treated conservatively with analgesia and fluid rehydration; his symptoms resolved.



Sickle cell disorders are the commonest genetic hematological disorders; the gene is frequent among people of African-American and Asian extraction. When heterozygous, the condition is called sickle cell trait; even so, it is usually asymptomatic. Nevertheless, people with homozygous sickle cell disorder as well as the heterozygous trait have been known to undergo tissue infarction. Although splenic infarction is rare, it is a recognized and dramatic complication of sickle cell trait (*Am J Med* 1989;87:30-4).

Splenic infarction usually causes pain in the left upper quadrant of the abdomen, although the pain is occasionally referred to the shoulder. Comorbid conditions (e.g., thalassemia, hypoxia, infection) and exposure to high altitudes (those above 3000 m or 10 000 feet) can precipitate infarction. In people with sickle cell trait, this can include microvascular infarction of the renal medulla.

Complications of splenic infarction

include abscess or pseudocyst formation, rupture and hemorrhage.

Patients with sickle cell trait and splenic infarction have been documented to have leukocytosis and fever in the first 72 hours. Patients who are having a sickle cell crisis may have an associated marrow response (leukocytosis, reticulocytosis). Our patient was unusual in that he had no evidence of active infection or bacteremia, nor had he been exercising or at a high altitude.

Samaad Malik

Department of Surgery

Patrick Duffy

Department of Internal Medicine

Paul A. Shulte

Department of Diagnostic Imaging

University of Saskatchewan

Regina General Hospital

Regina, Sask.

DOI:10.1503/cmaj.060026

**A blistering disease:
bullous erysipelas**

This patient with non-insulin-dependent diabetes mellitus had initially come to the emergency department. His diagnosis at that time was cellulitis, which was treated with a course of intravenous cefazolin and oral probenecid. By 4 days afterward his systemic symptoms had resolved, but he was referred to us for assessment of severe blistering that had erupted within the erythema.

We ruptured and drained the patient's bullae; a culture of the contained fluid grew only normal skin flora. He was provided a regimen of wound care, and his doses of cefazolin and probenecid were increased and continued for 14 days, followed by a 4-week course of cephalexin (by mouth). His edema and erythema resolved with no recurrence; graduated compression stockings were prescribed.

We diagnosed bullous erysipelas, which is a clinical diagnosis that indicates superficial cellulitis with lymphatic involvement; it is typically

caused by group A β -hemolytic streptococci. It typically appears on the legs and face as sharply demarcated, tender erythema and edema, with an indurated border. Accompanying signs and symptoms include lymphangitis, fever and chills. Erysipelas generally responds robustly to antibiotic therapy with β -lactams (*Dermatology* 2006; 212:31-5).

In a few cases, the clinical course is complicated by local appearance of bullae, necrosis or hemorrhage. This may represent a synergistic superinfection with *Staphylococcus aureus* or anaerobic microbes. These more aggressive forms of erysipelas respond less well to therapy and have a protracted course of disease (*Dermatology* 2006; 212:31-5).

Bullous involvement complicates erysipelas in some 5% of cases, with flaccid intraepidermal sterile blisters. The bullous form tends to occur more frequently among women and people with liver or renal disease. Those with bullous lesions have increased rates of infection with MRSA, the methicillin-resistant strains of *S. aureus* (*Dermatology* 2006;212:31-5). Diagnosis involves the differential exclusion of cellulitis, allergic contact dermatitis, bullous pemphigoid, necrotizing fasciitis and varicella-zoster.

Management of bullous erysipelas includes appropriate empiric antibiotic therapy, with consideration given to local rates of MRSA. Bullous fluid may be cultured, but the yield is generally low. Suggested adjuvant therapy includes rupture of the bullae, débridement of sloughed tissue and compression stockings. Recurrence, attributed to lymphatic obstruction, occurs in 30% of patients within 3 years.

Janet Edwards**Peter Green**

Division of Dermatology

David Haase

Division of Infectious Disease

Dalhousie University

Halifax, NS

DOI:10.1503/cmaj.060735

Dextrocardia with situs solitus

A routine physical examination of this apparently well teenage girl revealed a right-sided cardiac apex. Chest radiography confirmed that her heart was in the right chest and that the cardiac apex pointed to the right. The aortic arch was on her left; mediastinal contours were normal; her lungs were clear; and the gastric bubble was on her left side.

Dextrocardia refers to a heart positioned in the right side of the chest. Situs solitus describes viscera that are in the normal position, with the stomach on the left side; in situs inversus, the positions of the abdominal organs and viscera are reversed. Dextrocardia with situs solitus occurs in an estimated 7500–29 000 living people worldwide. Dextrocardia should be distinguished from dextroposition, in which the heart is located within the right thorax but its apex points to the

patient's left. Cardiac dextroposition can result from hypoplasia of the right lung or from a left-diaphragmatic hernia or eventration.

Patients with dextrocardia should undergo radiography of the chest and abdomen, electrocardiography and echocardiography. Other tests should be done when clinically indicated; for example, if Kartagener syndrome is suspected, radiography or CT of the paranasal sinuses might be necessary (bronchiectasis is best detected by CT scanning). Dextrocardia with situs solitus is often complicated by cardiovascular abnormalities, notably atrioventricular discordance, single ventricle, atrial or ventricular septal defect, anomalous pulmonary venous return or transposition of the great arteries. Although dextrocardia with situs inversus is seldom associated with congenital heart disease, these patients are at increased risk of pulmonary disease. Some 20% of patients with dextrocardia with situs inversus display Kartagener's syndrome,

which includes chronic sinusitis, nasal polyposis and bronchiectasis.

Syndromes specifically associated with dextrocardia include scimitar syndrome, which includes hypoplasia of and anomalous arterial blood supply to the right lung along with anomalous venous connection of the right pulmonary veins to the inferior vena cava, and Cantrell's syndrome, which is characterized by a diverticulum of the ventricle and defects of the midline abdominal wall, anterior diaphragm, lower sternum and the diaphragmatic portion of the pericardium. About 30% of patients with asplenia or polysplenia have dextrocardia.

Alexander K.C. Leung
Department of Pediatrics
University of Calgary
William Lane M. Robson
The Children's Clinic
Calgary, Alta.

DOI:10.1503/cmaj.060721



Online manuscript
submissions and
peer review

NOW AVAILABLE AT **CMAJ**

<http://mc.manuscriptcentral.com/cmaj>