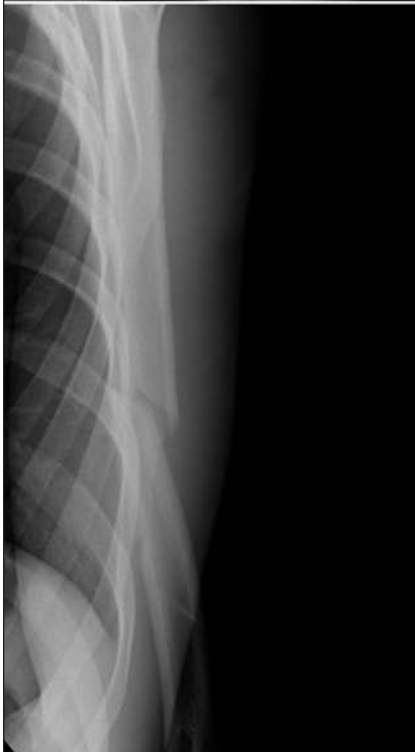
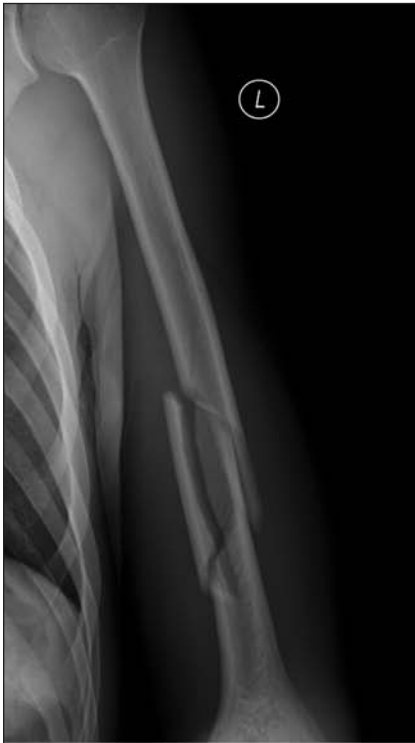
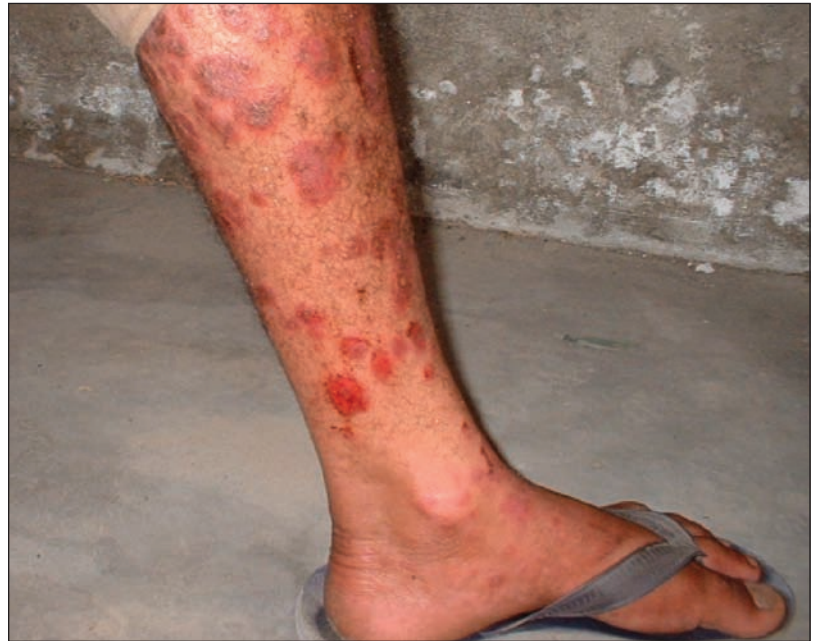CLINICAL VISTAS BRIEFS

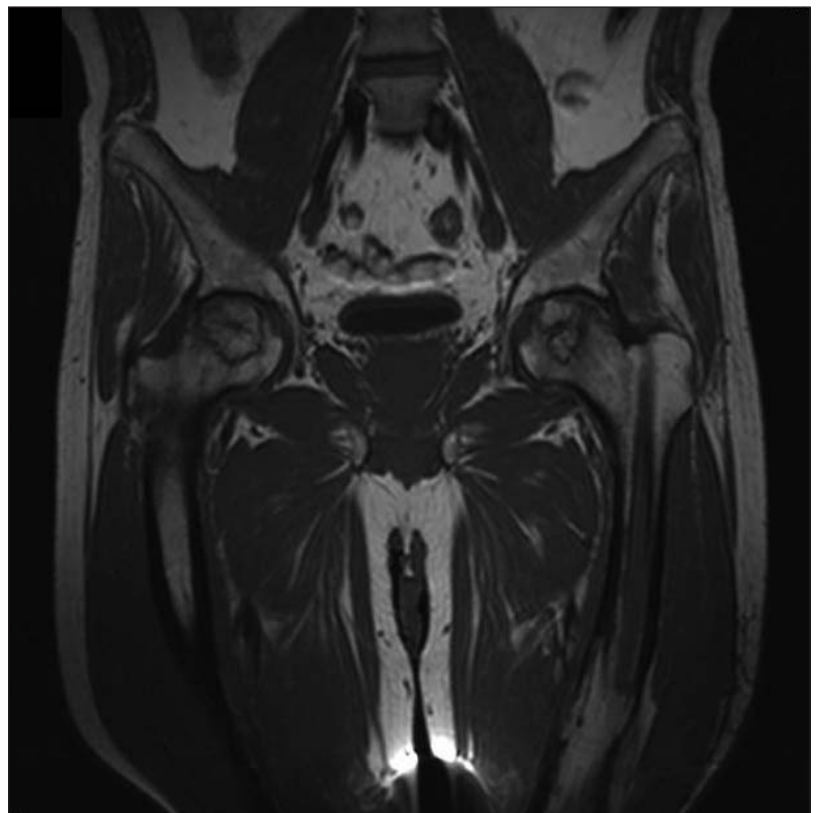
What's your call?



Frontal (top) and lateral (bottom) digital radiographs of the left humerus of a 20-year-old, left-handed man who had sudden arm pain after throwing a dodgeball.



A 32-year-old man with diffuse, well demarcated, raised, erythematous scaly plaques. Removal of the plaques often led to pinpoint capillary bleeding.



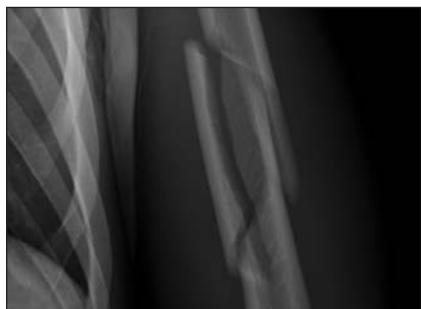MRI scan of a 45-year-old man who has had recurrent bilateral hip pain for 13 months and, upon examination, mild loss of range of motion.

See page 33 for diagnoses.

## CLINICAL VISTAS BRIEFS

## Ball-thrower's fracture of the humerus

These radiographs reveal a mildly displaced, comminuted spiral fracture at the distal diaphysis of the left humerus with an associated butterfly fragment (Fig. 1). The patient, a healthy recreational athlete with no prior arm pains, described making an off-balanced but forceful throw that was accompanied by a loud snapping noise.



He was neurologically and vascularly intact, distal to the injury. No underlying lesion was identified to suggest a pathological fracture. Test results for serum calcium and thyroid-stimulating and intact parathyroid hormones were all in the normal range; a whole-body bone scan showed no evidence of other lesions. The patient was treated with a hanging cast that was later converted to a functional brace. Bony union was achieved at 11 weeks; no residual deficits were noted.

Fractures of the humeral shaft during a throw are relatively rare. Although they have been reported for various thrown objects, including hand grenades, javelins, shot-puts, cricket balls, stones and snowballs (*Am J Sports Med* 1998;26:242-6), the items most frequently thrown are balls; hence, the injury's name. The fracture is almost always the result of a full-effort throw that is often accompanied by an audible crack or snap. Ball-thrower's fracture is generally accepted to result from intense torsion upon the humerus during the acceleration phase of the throw.

Interestingly, this fracture rarely occurs in professional pitchers; altered shoulder biomechanics and cortical

hypertrophy from years of training may be protective (*Am J Sports Med* 1998; 26:242-6). Because untrained athletes do not experience these changes, the torsional force generated by throwing can exceed bone integrity.

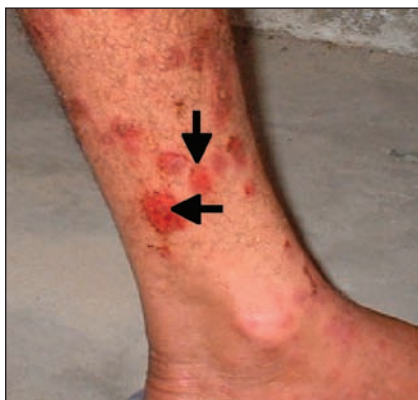Treatment involves a hanging cast, followed by a functional brace. The radial nerve is not usually involved, but when injured it almost always heals without medical intervention. Surgery is rarely recommended, and recovery is seldom less than excellent.

**Michael N. Colapinto**

Department of Radiology  
McMaster University, Hamilton, Ont.  
**Emil H. Schemitsch, Louis Wu**  
Departments of Orthopaedic Surgery  
(E.H.S.) and Medical Imaging (L.W.)  
St. Michael's Hospital, Toronto, Ont.

DOI:10.1503/cmaj.060378

## Psoriasis with Auspitz sign



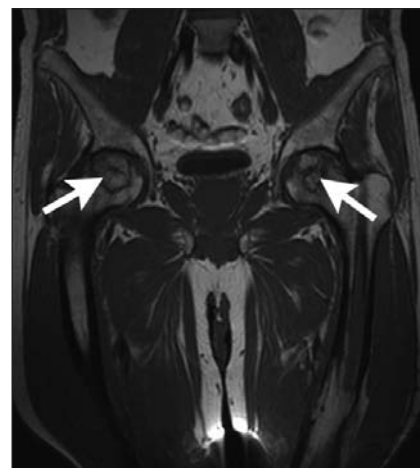
Psoriasis plaques often present as they did in this case: well demarcated, raised and erythematous, with silvery scales. Pinpoint capillary bleeding, known as Auspitz sign (arrows, Fig. 1), can result when the scales are gently scraped away with a spatula or fingernail.

**Ahmad Ayaz Sabri**  
**Muhammad Ahad Qayyum**  
Punjab Medical College  
Faisalabad, Pakistan

DOI:10.1503/cmaj.060423

## Avascular necrosis of the femoral heads after single corticosteroid injection

This patient had minimal tenderness over his hips, with mild limitation to his range of motion. Both hips had cystic changes in the femoral heads without collapse (Fig. 1). He had been treated 8 months previously with a single intramuscular dose of betamethasone (dose equivalent to 75.5 mg prednisolone) for an allergic condition.



Work-up and further history excluded the other known causes of avascular necrosis: liver disease, alcoholism, caisson disease (decompression sickness), pancreatitis, drug abuse, gout, sickle-cell disease, hyperlipidemia, Gaucher's disease and diabetes. The case was managed conservatively with rest, relief of weight-bearing with crutches, physiotherapy and simple analgesics.

Avascular necrosis of bone is a rare but potentially severe complication of prolonged corticosteroid therapy. It has also been recognized after short-term treatment (*CMAJ* 2001;164:205-6). The annual incidence of avascular necrosis is about 5 per 10 000 population.

**Izge Gunal, Vasfi Karatosun**  
Department of Orthopedics  
Dokuz Eylul University Hospital  
Izmir, Turkey

DOI:10.1503/cmaj.051638