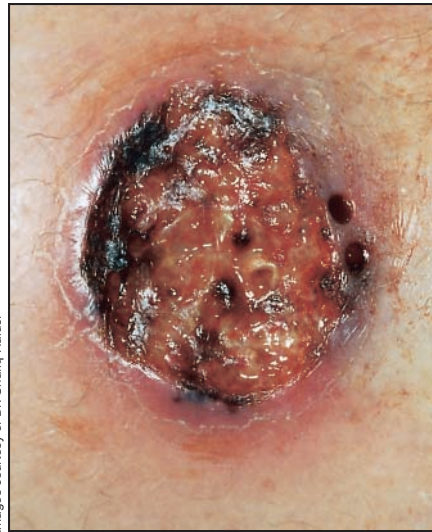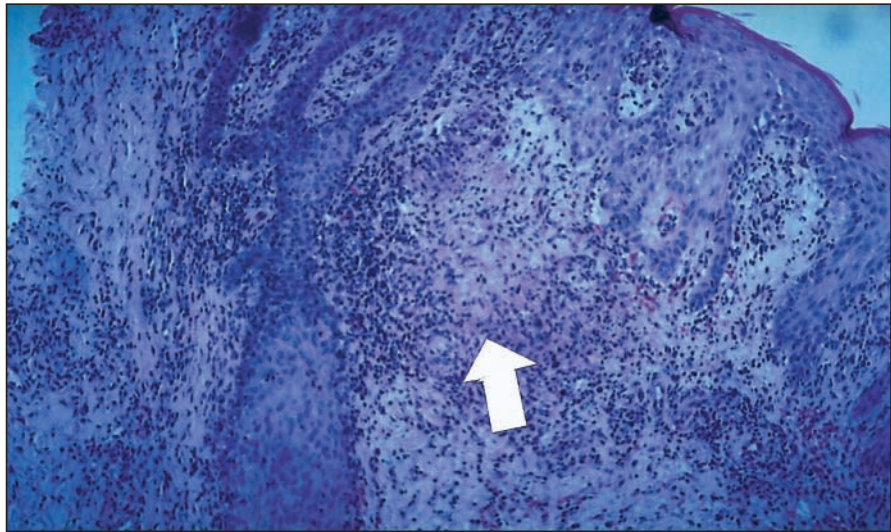


## Cutaneous ulcer in a man returning from Central America



Images courtesy of Dr. Shariq Haider



A previously healthy 54-year-old man returned from a 2-week vacation in the rain forests of Belize, where he recalled being bitten several times by mosquitoes and flies. He was well upon his return to Canada, but 6 weeks later a localized “volcano”-like eruption developed on his right shin with progressive, generalized lymphedema of his right lower extremity. His family physician prescribed a course of antibiotics for presumed cellulitis, with no improvement. Over the next 6 weeks the lesion ulcerated, and the lymphedema worsened. He was referred to our tropical medicine clinic, where he was seen to have a painful ulcer 2 × 2 cm in diameter over his right shin that had raised edges and marked central granulation tissue with serous discharge (Fig. 1).

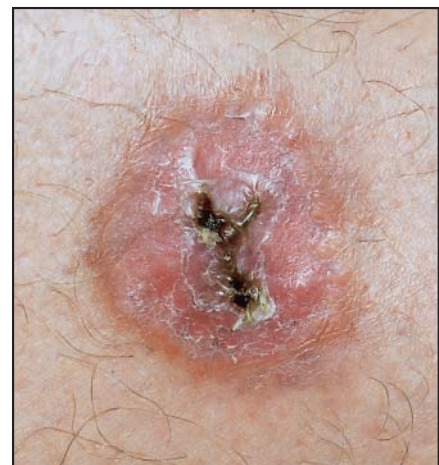The differential diagnosis of such a lesion includes chronic tropical ulcers frequently caused by Vincent’s organisms, Buruli ulcers caused by *Mycobacterium ulcerans*, cutaneous leishmaniasis and pyoderma gangrenosum.<sup>1,2</sup> Chronic tropical ulcers typically respond to local care and systemic antibiotic therapy, and Buruli ulcers are painless and do not have raised margins. Given the clinical presentation, cutaneous leishmaniasis seemed the most likely diagnosis.

Numerous methods are available for

diagnosing cutaneous leishmaniasis.<sup>3</sup> A biopsy of the lesion showed epidermal hyperplasia and deep dermal chronic inflammation with occasional granulomas, but no amastigotes (the undifferentiated form of the *Leishmania* parasite found within the macrophages) (Fig. 2). Giemsa and hematoxylin–eosin staining of fluid aspirates did not yield *Leishmania* amastigotes; however, on day 5, culture of a biopsy specimen in M199 medium (Life Technologies Inc., Rockville, Md.) showed *Leishmania* promastigotes (a differentiated stage of the parasite’s life cycle). A sample of the ulcer was also found to contain DNA for *Leishmania braziliensis*, detected using the polymerase chain reaction test and a specific primer set developed at the National Reference Centre for Parasitology, Montreal.<sup>4</sup> Because *L. braziliensis* is associated with mucocutaneous leishmaniasis, our patient was given sodium stibogluconate (antimony compound) intravenously at a dose of 20 mg/kg daily for 20 days, with healing of the ulcer (Fig. 3) and resolution of the lymphedema.

Leishmaniasis is a heterogeneous parasitic disease transmitted to humans by the bite of a sandfly. The disease is endemic in 88 countries, involving regions of Africa,

Asia, the Mediterranean, and South and Central America.<sup>5</sup> It can involve the skin but also the viscera, especially of the liver and spleen. Of particular concern is the increased number of often fatal cases of visceral leishmaniasis seen mainly in southern Europe as a coinfection with HIV acquired principally through intravenous drug use.<sup>5</sup> Most cases of cutaneous leishmaniasis are self-limited over periods of weeks; however, certain subtypes of *Leishmania* sp. can cause mucocutaneous disease, with destructive lesions of the oral and nasal cavities that require treatment.<sup>6</sup> Treatment options include allopurinol, oral therapy with antifungal azole agents, topical treatments



(heating, freezing, intralesional antimony compounds, paramomycin ointment) and the “gold standard” of systemic therapy with antimony compounds.<sup>7,8</sup>

The case reported here highlights the need to consider leishmaniasis in anyone returning from a tropical destination who has a progressive ulcer that does not respond to local care and systemic antibiotic therapy.

#### Shariq Haider

Tropical Medicine Clinic  
Division of Infectious Diseases  
McMaster University

#### Odette Boutross-Tadross

Jasim Radhi  
Department of Pathology  
McMaster University  
Hamilton, Ont.

#### Ndao Momar

McGill University Centre for Tropical Diseases  
National Reference Centre for Parasitology  
Montréal, Que.

#### References

1. Cook GC, editor. *Manson's tropical diseases*. 20th ed. Philadelphia: Saunders; 1996. p. 1213-45.
2. Weir E. Buruli ulcer: the third most common mycobacterial infection. *CMAJ* 2002;166(13):1691.
3. Weigle KA, de Davalos M, Heredia P, Molineros

R, Saravia NG, D'Alessandro A. Diagnosis of cutaneous and mucocutaneous leishmaniasis in Colombia: a comparison of seven methods. *Am J Trop Med Hyg* 1987;36(3):489-96.

4. Weigle KA, Labrada LA, Lozano C, Santrich C, Barker DC. PCR-based diagnosis of acute and chronic cutaneous leishmaniasis caused by *Leishmania (viannia)*. *J Clin Microbiol* 2002;40(2):601-6.
5. Herwaldt BL. Leishmaniasis. *Lancet* 1999;354:1191-9.
6. Royer M, Crowe M. American cutaneous leishmaniasis. A cluster of 3 cases during military training in Panama. *Arch Pathol Lab Med* 2002;126:471-3.
7. Berman JD. Human leishmaniasis: clinical, diagnostic, and chemotherapeutic developments in the last 10 years. *Clin Infect Dis* 1997;24:684-703.
8. Alrajhi AA, Ibrahim EA, De Vol EB, Khairat M, Faris RM, Maguire JH. Fluconazole for the treatment of cutaneous leishmaniasis caused by *Leishmania major*. *N Engl J Med* 2002;346(12):891-5.

## IN THE LITERATURE

# Long-term management of atrial fibrillation: Rhythm or rate control?

β See related article page 572

**Atrial Fibrillation Follow-up Investigation of Rhythm Management (AFFIRM) Investigators. A comparison of rate control and rhythm control in patients with atrial fibrillation. *N Engl J Med* 2002;347:1825-33.**

**Background:** Atrial fibrillation may produce symptoms that are thought to be due to the poorly controlled ventricular rate or the irregular rhythm, or both. Although anticoagulation reduces the risk of stroke, it is not known whether treatment strategies to maintain sinus rhythm are superior to those that simply maintain rate control. In theory, rhythm-control strategies might result in fewer symptoms, better exercise tolerance, lower risk of stroke, eventual discontinuation of anticoagulation, better quality of life and improved survival. Atrial fibrillation, however, often responds poorly to antiarrhythmic drugs, which themselves can be associated with adverse effects.

**Question:** In the long-term management of atrial fibrillation is it preferable to start with a rhythm-control strategy or a rate-control approach?

**Design:** This multicentre, randomized, nonblinded trial compared rhythm-control and rate-control strategies in patients with atrial fibrillation who were at least 65 years of age or had other risk factors for stroke or death. Eligible patients had atrial fibrillation that was judged clinically by the investigators to likely be recurrent and cause illness or death, such that long-term treatment was deemed warranted.

In the rhythm-control group, the treating physician was free to choose one or more antiarrhythmic drugs from among amiodarone, disopyramide, flecainide, moricizine, procainamide, propafenone, quinidine, sotalol and dofetilide. Cardioversion was allowed as necessary to maintain sinus rhythm. In the rate-control group, the choice of

one or more drugs was allowed from among β-blockers, calcium-channel blockers (verapamil and diltiazem) and digoxin, with the aim of maintaining a heart rate not exceeding 80 beats/min at rest or 110 beats/min during a 6-minute walk. After failure of at least 2 trials of a rhythm-control or rate-control drug, patients could be considered for nonpharmacologic therapy as appropriate to their group assignment.

Although both groups were given warfarin to reach an international normalized ratio (INR) of 2.0–3.0, the treating physicians of patients in the rhythm-control group were free to stop the warfarin once sinus rhythm had been maintained for at least 4 weeks. The primary analysis was an intention-to-treat comparison of the time to death from any cause, adjusted for interim analyses.

**Results:** The 4060 patients enrolled in the study had a mean age of 69.7 years and similar baseline characteristics. In