was written. Gay and bisexual men who injected drugs have a higher incidence rate (3.1 per 100 person-years [95% CI 0.6–6.1]) than those who did not (0.9 per 100 person-years [95% CI 0.4–1.4]). Robert Remis and colleagues are correct in assuming that our rate of HIV incidence among noninjecting participants is similar to that reported for men under 30 years in the Omega cohort (1.0 per 100 person-years from 1996 to 1999). However, the annualized incidence rates presented in Table 1 for noninjecting gay and bisexual men indicate that HIV infection appears to be increasing in this population.

Remis and colleagues felt that we should have reported follow-up risky sexual behaviour among participants who had safe as well as unsafe sexual practices at baseline. Of the 285 men with regular partners, 89 (31.2%) reported having unprotected insertive anal sex and 100 (35.0%) reported having unprotected receptive anal sex in the year before the baseline visit. At 1-year follow-up, 66 (74.1%) of the 89 subjects and 71 (71.0%) of the 100 subjects reported having unprotective insertive and receptive anal sex respectively. Of the 279 men with casual partners, 46 (16.5%) reported having unprotected insertive and 36 (12.4%) unprotected receptive anal sex in the year before the baseline visit. Of these men, 21 (46.6%) and 16 (44.4%) reported having had unprotected insertive and receptive anal intercourse respectively by the time of their first follow-up visit. In combining these data with other information presented in our paper,[1] the odds of relapse among men with regular partners increased 2-fold for both unprotected insertive intercourse (odds ratio 2.2, 95% CI 1.4-3.7) and receptive anal intercourse (odds ratio 1.9, 95% CI 1.4-3.0). Among men with casual partners, similar odds were observed for unprotected insertive intercourse (odds ratio 1.7, 95% CI 1.0–2.8), but the odds for receptive anal intercourse were not significantly increased (odds ratio 1.3, 95% CI 0.7–2.3). These new data along with the findings originally presented in our article confirm the high HIV rates and sexual risk behaviour in our cohort.

Robert S. Hogg
British Columbia Centre for Excellence in HIV/AIDS
St. Paul's Hospital
Vancouver, BC
Steffanie A. Strathdee
Johns Hopkins School of Hygiene and Public Health
Baltimore, Md.
Keith Chan
Stephen L. Martindale
Kevin J.P. Craib
British Columbia Centre for Excellence in HIV/AIDS
St. Paul's Hospital
Vancouver, BC

Reference

1. Strathdee SA, Martindale SL, Cornelisse PGA, Miller ML, Craib KJP, Schechter MT, et al. HIV infection and risk behaviours among young gay and bisexual men in Vancouver. *CMAJ* 2000;162(1):21-5.

Submitting letters

Letters may be submitted by mail, courier, email or fax. They must be signed by all authors and limited to 300 words in length. Letters that refer to articles must be received within 2 months of the publication of the article. *CMAJ* corresponds only with the authors of accepted letters. Letters are subject to editing and abridgement.

Note to email users

Email should be addressed to **pubs@cma.ca** and should indicate "Letter to the editor of *CMAJ*" in the subject line. A signed copy must be sent subsequently to *CMAJ* by fax or regular mail. Accepted letters sent by email appear in the Readers' Forum of *eCMAJ* (**www.cma.ca/cmaj**) promptly, and are published in a subsequent issue of the journal.

Different centuries, same old story

The recent *Escherichia coli* outbreak in Walkerton, Ont., is remarkably similar to a cholera outbreak in Hamburg, Germany, in 1892. However, it is not the outbreak of waterborne disease that makes these stories similar but the delays in warning citizens of the emerging epidemics threatening them.

In Hamburg, the first person to die from cholera was a building worker who inspected a sewage outlet on Aug. 15. Although his vomiting and diarrhea were consistent with cholera, an official diagnosis could not be made without a cultured bacillus. Another building worker became ill with the same symptoms and died Aug. 17. However, gastrointestinal upset was not uncommon during the summer months in Hamburg and local doctors were not persuaded to take the time to investigate the cause of each illness. Physicians did not attempt to culture the bacillus until Aug. 20. In the meantime, others began to show signs of infection: 2 people on the 16th, 4 more on the 17th and 12 on the 18th. By Aug. 19, 31 patients had received treatment.

Although "official" confirmation of the cholera outbreak had been received by Aug. 22, the chief medical officer and the Senate chose not to warn people to boil water, and the contamination was not publicized until Aug. 24. By then, every part of the city had been infected and thousands of citizens had unsuspectingly consumed the infected water; they soon became ill with cholera and began to infect others. By the time the cholera outbreak was fully contained almost 17 000 poeple had been infected and 8600 had died. The outbreak of 1892 killed 13.4% of the population of Hamburg; it killed as many people as all other cholera outbreaks in Germany during the 19th century.[1]

Although several public inquiries and investigations are taking place to ascertain just went wrong in Walkerton, the Hamburg outbreak does illus-

trate the fact that history, even medical history, does tend to repeat itself.

Adrian M. Viens
Joint Centre for Bioethics
University of Toronto
Toronto, Ont.

Reference

1. Evans RJ. *Death in Hamburg: society and politics in the cholera years 1830–1910*. London: Penguin; 1987. p. 285-314.

Plastic bread-bag clips: the saga continues

We read with interest the recent report of plastic bread-bag clips in the gastrointestinal tract.[1] We were recently consulted regarding a patient whose small bowel was ultimately found to have been perforated owing to an impacted plastic bread-bag clip.

The patient, a 39-year-old man, had been experiencing intermittent episodes of colicky abdominal pain for about 5 years. He had previously been admitted to hospital with signs and symptoms consistent with a small bowel obstruction. He had undergone several investigations, including CT scans and a small bowel follow-through, but no cause was identified.

He presented at our hospital with severe pain and a recent onset of nausea and vomiting. This followed several weeks of increasing crampy pain, associated with at least 1 episode of rectal bleeding. He was admitted to the GI service and over the next 36 hours developed signs of peritonitis, for which the surgical service was consulted. In the meantime, he had undergone both an ultrasound and a CT scan, which showed a small amount of free fluid but nothing else.

He underwent a laparotomy, and the clip was found in the distal small bowel, where it appeared to have attached itself and slowly eroded through the wall, as described by Ken Newell and colleagues.[1] He underwent a resection and primary anastomosis, from which he has recovered well. Unfortunately, the "best before" date was no longer visible on the clip.

In contrast to most of the patients in the study by Newell and colleagues,[1] this patient was young and had his own teeth. However, he is a single parent of young, active children and said that he often eats in a rush and does not chew his food well.

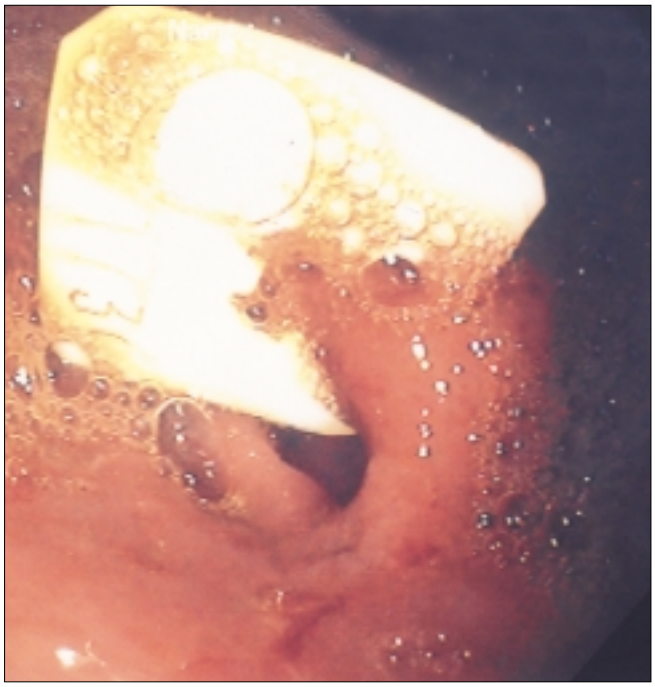

Fig. 1: Endoscopic view of the pyloris with the plastic bread-bag clip embedded in the pyloric lip.

The findings in this case support the authors' recommendation that the clips be made of a radiopaque material to allow early identification of the foreign body.

Susan McDonald
General surgery resident
Con Rusnak
General surgeon
Capital Health Region
Victoria, BC

Reference

1. Newell KJ, Taylor B, Walton JC, Tweedie EJ. Plastic bread-bag clips in the gastrointestinal tract: report of 5 cases and review of the literature. *CMAJ* 2000;162(4):527-9.

I was surprised to see how many cases of plastic bread-bag clip ingestion with complications have been previously reported.[1] We also had 1 case recently in a 73-year-old woman who had unknowingly ingested a plastic bread-bag clip and subsequently complained of epigastric pain. An upper gastrointestinal barium study suggested gastric ulceration. When we performed a gastroscopy we were surprised to see a plastic bread-bag clip lodged in the pyloris (Fig. 1). The angled teeth of the plastic clip had trapped the pyloric lip and had become deeply embedded. We used a snare to grab the clip and gently pull it out of the gastric mucosa. The clip was removed without sequela and the patient was placed on acid suppression with complete resolution of her symptoms. With regards to the risk factors mentioned by the authors, our patient wore dentures but did not have dementia.

I support Ken Newell and colleagues' suggestion that other forms of bag ties be used or that these clips be physically altered to minimize these occurrences.[1]

Carlo Fallone
Gastroenterologist
McGill University Health Centre
Montreal, Que.

Reference

1. Newell KJ, Taylor B, Walton JC, Tweedie EJ. Plastic bread-bag clips in the gastrointestinal tract: report of 5 cases and review of the literature. *CMAJ* 2000;162(4):527-9.