

Acute hepatitis in an 18-year-old returning traveller

Sana Jawad MD BSc, Carla S. Coffin MD MSc, Stephen D. Vaughan MD, Michelle C. Lamarche MD MSc

■ Cite as: *CMAJ* 2024 April 2;196:E410-4. doi: 10.1503/cmaj.230490

An 18-year-old man, born in Pakistan, presented to the emergency department with a 4-day history of fever (self-reported 38.5°C), chills, abdominal pain, anorexia, and 2 days of emesis. He was previously healthy and had returned to Canada 3 weeks previously from Pakistan. He took no prescribed medications, but had taken 8 extra-strength acetaminophen tablets daily over the preceding 4 days. His temperature was 36.7°C, blood pressure 89/56 mm Hg, heart rate 89 beats/min, and respiratory rate 18 breaths/min. He appeared dehydrated and jaundiced, and had tenderness in the right upper quadrant.

The patient had not received pre-travel vaccinations or medical counselling, nor had he taken malaria chemoprophylaxis. He ate street food and drank bottled water while traveling. He reported many mosquito bites and 1 day of mild diarrhea during his trip. He denied sick contacts, recreational drug use, or alcohol use.

Blood work revealed an alanine transaminase (ALT) level more than 7000 (normal range ≤ 69) U/L and an international normalized ratio (INR) of 1.6 (normal range 0.9–1.1) (Table 1). We initially ordered an acetaminophen level, autoimmune and viral liver panels, stool sample testing and cultures for viruses and bacteria, blood cultures, and testing for SARS-CoV-2 antigen. We administered intravenous fluids, antiemetics, and empiric *N*-acetylcysteine (NAC) until the patient's INR was less than <1.5. Given his travel history, we tested for malaria, dengue, Zika, chikungunya, and hepatitis A (HAV), B (HBV), C (HCV), and E (HEV).

The patient's INR increased to 2.1 within 24 hours of presentation and he had grade II hepatic encephalopathy in the absence of medications whose effects might have mimicked symptoms of encephalopathy, consistent with evolving acute liver failure. Abdominal ultrasonography showed gallbladder thickening and mild splenomegaly, but no liver or biliary tree abnormalities. Because his serological workup had not returned and his liver failure appeared to be worsening without a clear cause, we consulted a hepatologist, who performed a liver biopsy. Results from pathology showed subacute hepatitis, consistent with a viral cause, and no confluent necrosis or viral inclusions, thereby decreasing the likelihood of herpes.

The next day, the patient's serological tests returned positive results for HAV immunoglobulin (Ig) M, chikungunya IgM,

Key points

- The potential causes of acute hepatitis with transaminitis (> 1000 U/L) include viruses (e.g., hepatitis viruses [A, B, C, E] Epstein–Barr virus, herpes simplex virus, cytomegalovirus), drugs or toxins (most commonly acetaminophen), ischemia or congestion, choledocholithiasis, and autoimmune conditions.
- Hepatitis A infection is generally self-limiting and requires supportive management; fewer than 1% of infections lead to fulminant liver failure, with highest risk of progression among patients older than 40 years with pre-existing liver disease.
- Early consultation with a hepatologist is advised for any patient with worsening liver injury; clinical deterioration with extrahepatic involvement, especially encephalopathy, should prompt critical care assessment and discussion with a transplant centre.
- In Canada, immunization against hepatitis A is encouraged for patients older than 6 months with risk factors, such as those travelling to a hepatitis A–endemic region and older patients with pre-existing chronic liver disease.

Epstein–Barr virus IgM and IgG, and cytomegalovirus IgM, and his stool was positive for norovirus RNA. The positive result for HAV IgM was confirmed by polymerase chain reaction (PCR) stool testing. Serum PCR testing for chikungunya, Epstein–Barr virus, and cytomegalovirus were negative (Table 2).

We discharged the patient 8 days after admission; his ALT level and INR had decreased (652 U/L and 1.4, respectively) but his bilirubin level had increased to 192 (normal range 0–24) $\mu\text{mol/L}$ (Table 1). We assumed that his jaundice at discharge reflected the cholestatic phase of severe, acute HAV infection. We prescribed ursodeoxycholic acid (500–750 mg/d) for 1 month to decrease pruritus (off-label use). Three weeks later, his jaundice had improved (Table 1). Repeat testing for chikungunya and cytomegalovirus IgM were negative at 5 weeks after admission, without seroconversion to IgG antibodies, suggesting that the initial results were false positives (Table 2). Repeat testing for Epstein–Barr virus IgM remained falsely positive.

Table 1: Laboratory results for an 18-year-old man with acute hepatitis on admission (day 0), discharge (day 8), and follow-up (day 30)

Laboratory test	Normal reference range	Admission (day 0)	Discharge (day 8)	Follow-up (day 30)
Alanine transaminase, U/L	≤ 69	> 7000	652	52
Alkaline phosphatase, U/L	40–120	158	194	128
γ-Glutamyltransferase, U/L	≤ 79	225	NA	59
Lactate dehydrogenase, U/L	100–235	> 2500	NA	NA
Bilirubin, μmol/L	0–24	72	192	32
Platelets, × 10 ⁹ /L	150–400	93	170	228
INR	0.9–1.1	1.6	1.4	1.2

Note: INR = international normalized ratio, NA = not applicable.

Table 2: Infectious serology in an 18-year-old man with acute hepatitis

Virus	Test	Admission*	2 weeks	5 weeks
Hepatitis A	IgM	+		
	IgG	+		
	DNA	+		
Chikungunya	IgM	+	+	-
	IgG	-	-	-
	RNA	-		
Epstein–Barr virus	IgM	+		+
	IgG	+		+
	DNA	-		
Cytomegalovirus	IgM	+		-
	IgG	-		-
	DNA	-		
Dengue	IgM	-	+	-
	IgG	-	-	-
	RNA	-		
Norovirus	RNA	+		

Note: Ig = immunoglobulin.
 *Testing on admission was also negative for hepatitis B surface antigen and hepatitis B core antibody, hepatitis C antibody, hepatitis E antibody and RNA, HIV, herpes simplex virus DNA, varicella zoster virus DNA, parvovirus B19 IgM, SARS-CoV-2, Zika virus RNA, and malaria blood smear.

Discussion

Acute hepatitis is characterized by liver inflammation or hepatocellular injury lasting less than 6 months with subsequent normalization of liver tests.¹ Globally, viral infection is the most common cause of acute hepatitis, but nonviral causes — including drugs, toxins, autoimmune, and ischemic conditions — are common causes in Canada. Infections with the 5 hepatotropic viruses (HAV through HEV) are usually self-limited; however, HBV and HCV sometimes evolve into chronic hepatitis.¹ Hepatotropic viruses are common in Africa and Asia, with HAV and HEV particularly common in resource-poor areas, primarily transmitted by a fecal–oral route and with risk of widespread contamination after flooding events.¹ The work-up for acute hepatitis is shown in Figure 1.

Given our patient's recent travel to Pakistan, coupled with his nausea, abdominal pain, fever, and severe transaminitis, we investigated for viral hepatitis, SARS-CoV-2 infection, malaria, dengue, Zika, and chikungunya. Testing for Epstein–Barr virus, cytomegalovirus, and herpes simplex virus could have been deferred, given that he was immunocompetent and had no evidence of herpes lesions. He did not have headache, eye pain, rash, or diffuse arthralgias, typical of dengue, nor did he have arthralgias, splenomegaly, or anemia, typical of malaria. Hepatitis D virus acquisition needs HBV to have completed its life-cycle, and since the patient did not have chronic HBV infection, we did not test for HDV.¹

Liver biopsies are not usually performed in patients with suspected viral hepatitis. We performed a liver biopsy in our patient

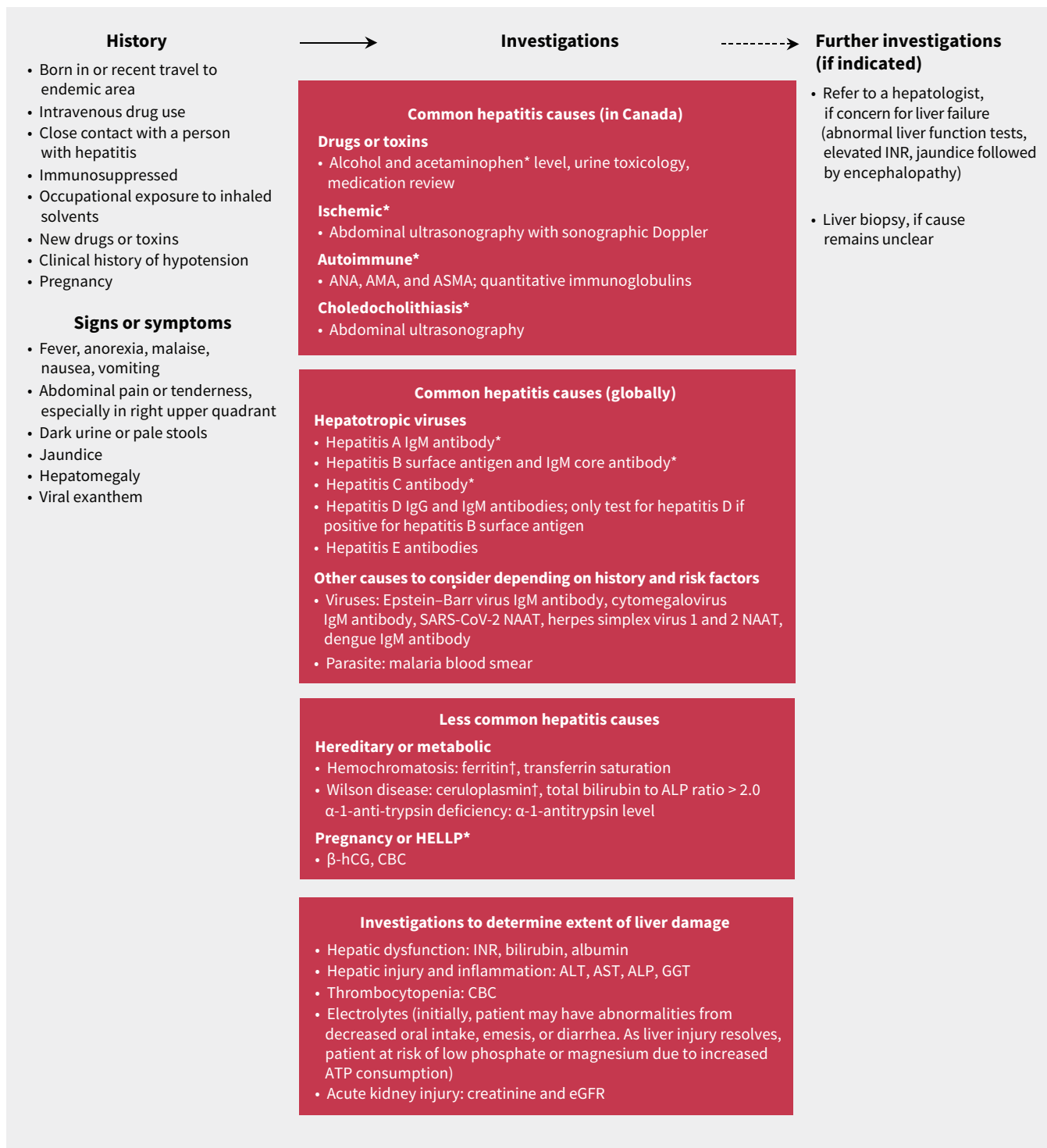


Figure 1: History, physical examination, and investigations for the workup of acute hepatitis. *Typical causes of alanine transaminase (ALT) or aspartate transaminase (AST) elevation greater than 1000 U/L. †Results may be abnormal in patients with acute inflammation, potentially confounding diagnosis. Note: ALP = alkaline phosphatase; AMA = antimitochondrial antibody; ANA = antinuclear antibody; ASMA = anti-smooth muscle antibody; ATP = adenosine triphosphate; CBC = complete blood count; eGFR = estimated glomerular filtration rate; hCG = human chorionic gonadotropin; GGT = γ -glutamyltransferase; HELLP = hemolysis, elevated liver enzymes, and low platelets; Ig = immunoglobulin; INR = international normalized ratio; NAAT = nucleic acid amplification test.

because the results of serology testing had not yet returned and we were concerned about progression to severe liver injury and acute liver failure, which is defined by impaired liver function with elevated transaminases, INR greater than 1.5, and jaundice

preceding clinical encephalopathy.² Alterations in mental status are often subtle and should be actively sought. Early consultation with a hepatologist is advised for any patient with worsening liver injury and signs of liver dysfunction; clinical deterioration

with extrahepatic involvement, especially encephalopathy, should prompt discussions with a transplant centre.

Although many viral infections are managed supportively, management of acute hepatitis has important exceptions. Acute HBV and HCV infections can become chronic, which could result in cirrhosis or liver cancer.¹ Antiviral therapies influence the natural history of chronic HBV infection by decreasing viral replication and hepatic inflammation,¹ and are more than 95% effective at curing chronic HCV infection. For patients with hepatitis caused by herpes simplex virus, clinicians should start empiric treatment with acyclovir, and, in immunocompromised patients, antiviral treatments such as ganciclovir are beneficial for severe hepatitis caused by Epstein–Barr virus. For malarial hepatitis, antimalarial medications such as artesunate are indicated.

N-acetylcysteine is a thiol-containing agent with antioxidant and antiviral properties. The 2017 European Association for the Study of the Liver guideline suggested that use of NAC in the treatment of non-acetaminophen-induced liver failure may decrease hepatic encephalopathy.² One large meta-analysis, including 883 patients with non-acetaminophen-related acute liver failure, showed NAC significantly improved transplant-free, post-transplant, and overall survival.³ As such, pending updated guidelines, expert opinion encourages its use in both acetaminophen- and non-acetaminophen-induced liver failure until an INR of less than 1.5 is achieved.³

In our patient, we ultimately diagnosed severe HAV and norovirus; however, establishing the main cause of his acute hepatitis was confounded by immunoglobulin cross-reactivity. Our patient had false-positive IgM serology for chikungunya and cytomegalovirus, as no seroconversion from IgM to IgG occurred, and his initial serum PCR was negative for both viruses. Because IgM antibodies bind to their targets with less specificity than IgG antibodies, a positive IgM result may be owing to nonspecific serologic activation.⁴

The risk of HAV-induced fulminant hepatitis increases when patients are coinfecting with HIV, dengue, HBV, HCV, or multiple HAV phenotypes.⁵ A recent review identified 17 patients with norovirus-induced hepatitis, nearly 90% of whom were younger than 18 years; infections resolved in two-thirds of patients with supportive treatment.⁶ Although HAV was the primary driver of liver injury in our patient, concurrent norovirus infection likely contributed to the severity of infection.

Hepatitis A is a positive-sense, single-stranded RNA virus with an incubation period of 15–50 days.⁷ Acute infection can cause hepatitis with a clinical prodrome of nausea, vomiting, abdominal pain, fatigue, malaise, and fever, followed by jaundice and pruritus days to weeks later. Notable transaminitis occurs about 1 month after infection, with a subsequent increase in bilirubin. Serum IgM anti-HAV antibodies have a sensitivity and specificity greater than 95% for acute HAV infection.⁷ Hepatitis A IgM is detectable within 5–10 days of infection and undetectable 4–6 months after resolution of acute hepatitis; HAV IgG becomes detectable during the convalescent stage of infection (or after immunization) and remains so permanently. Acute HAV infection usually requires only supportive management; it typically resolves within 6 months, although a

relapsing variant may persist for as long as 1 year. Jaundice generally resolves within 3 months. Liver tests should be monitored every 2–3 weeks until all liver tests are improving and INR has normalized, with follow-up at 3 months to ensure normalization of all liver tests. Infrequently, acute HAV may cause substantial morbidity and require hospital admission. Fulminant hepatic failure occurs in fewer than 1% of patients, with the main risk factors being age older than 40 years at infection and pre-existing chronic liver disease.⁷

Rates of HAV have decreased in high-income countries since the introduction of a vaccine in 1995. However, recent HAV outbreaks in North America, especially in the homeless population, and consistently high rates in Africa, Asia, and South America have led to reinvigorated vaccination efforts.⁸ Inactivated (HepA-I) and live attenuated (HepA-L) vaccines for HAV are available worldwide, usually in a 2-dose schedule administered at least 6 months apart, with the first dose given at least 2 weeks before travel or exposure.⁸ Immune protection persists for more than 20 years. Both preparations have shown efficacy of more than 90%, with excellent safety.⁸ Current Canadian guidance supports vaccination (such as HAVRIX HepA-I) for patients at increased risk of infection or HAV-related complications, such as those travelling to HAV-endemic countries or those with pre-existing chronic liver disease.⁹ The province of Quebec immunization program recommends HAV vaccination at 18 months in all children.¹⁰

In a returning traveller with fever, gastrointestinal symptoms and severe transaminitis, acute hepatitis is most often caused by HAV; however, investigations for other causes may affect management decisions and coinfections may synergistically influence the infection's severity. Immunization against HAV is safe and effective and should be given to patients travelling to an HAV-endemic region, and older patients with pre-existing liver disease. A hepatologist should be consulted early for patients with worsening liver dysfunction, especially those with altered mental status.

References

1. Lanini S, Ustianowski A, Pisapia R, et al. Viral hepatitis: etiology, epidemiology, transmission, diagnostics, treatment, and prevention. *Infect Dis Clin North Am* 2019;33:1045-62.
2. European Association for the Study of the Liver. easl clinical practice guidelines on the management of acute (fulminant) liver failure. *J Hepatol* 2017;66:1047-81.
3. Walayat S, Shoaib H, Asghar M, et al. Role of N-acetylcysteine in non-acetaminophen-related acute liver failure: an updated meta-analysis and systematic review. *Ann Gastroenterol* 2021;34:235-40.
4. Post JJ, Chan MK, Whybin R, et al. Positive Epstein-Barr virus and cytomegalovirus IgM assays in primary HIV infection. *J Med Virol* 2011;83:1406-9.
5. Maki Y, Kimizuka Y, Sasaki H, et al. Hepatitis A virus-associated fulminant hepatitis with human immunodeficiency virus coinfection. *J Infect Chemother* 2020;26:282-5.
6. Ho CL, Oligbu C, Asaid O, et al. Does norovirus induce acute hepatitis? *AIMS Public Health* 2020;7:148-57.
7. Matheny S, Kingery J. Hepatitis A. *Am Fam Physician* 2012;86:1027-34.
8. Zhang L. Hepatitis A vaccination. *Hum Vaccin Immunother* 2020;16:1565-73.
9. Hepatitis A vaccines: Canadian Immunization Guide. Ottawa: Government of Canada; 2018. Available: <https://www.canada.ca/en/public-health/services/publications/healthy-living/canadian-immunization-guide-part-4-active-vaccines/page-6-hepatitis-a-vaccine.html#rf> (accessed 2023 Oct. 28).
10. Quebec Immunization Program. Hepatitis A, B and C. Government of Quebec; 2024. Available: <https://www.quebec.ca/en/health/health-issues/stbbis/hepatitis-a-b-and-c> (accessed 2024 Feb. 28).

Competing interests: Carla Coffin reports research support from GSK. No other competing interests were declared.

This article has been peer reviewed.

The authors have obtained patient consent.

Affiliations: Postgraduate Medical Education, Division of Psychiatry (Jawad), Cumming School of Medicine; Division of Gastroenterology and Hepatology (Coffin), of Infectious Diseases (Vaughan), and of Internal Medicine (Lamarche), Department of Medicine, Cumming School of Medicine, University of Calgary, Calgary, Alta.

Contributors: Sana Jawad, Carla Coffin, and Michelle Lamarche provided medical care for the patient while he was admitted to hospital, and Carla Coffin and Stephen Vaughan provided outpatient follow-up care. All authors were involved in the conception and design of the work. Sana Jawad and Michelle Lamarche drafted the manuscript. All authors revised it critically for important intellectual content, gave final approval of the version to be published, and agreed to be accountable for all aspects of the work.

Content licence: This is an Open Access article distributed in accordance with the terms

of the Creative Commons Attribution (CC BY-NC-ND 4.0) licence, which permits use, distribution and reproduction in any medium, provided that the original publication is properly cited, the use is noncommercial (i.e., research or educational use), and no modifications or adaptations are made. See: <https://creativecommons.org/licenses/by-nc-nd/4.0/>

Correspondence to: Michelle Lamarche, michelle.lamarche@albertahealthservices.ca