

## Vaginal polypoid endometriosis

Monique Marguerie MSc MD, Jenika Howell MD, Liane Belland MD

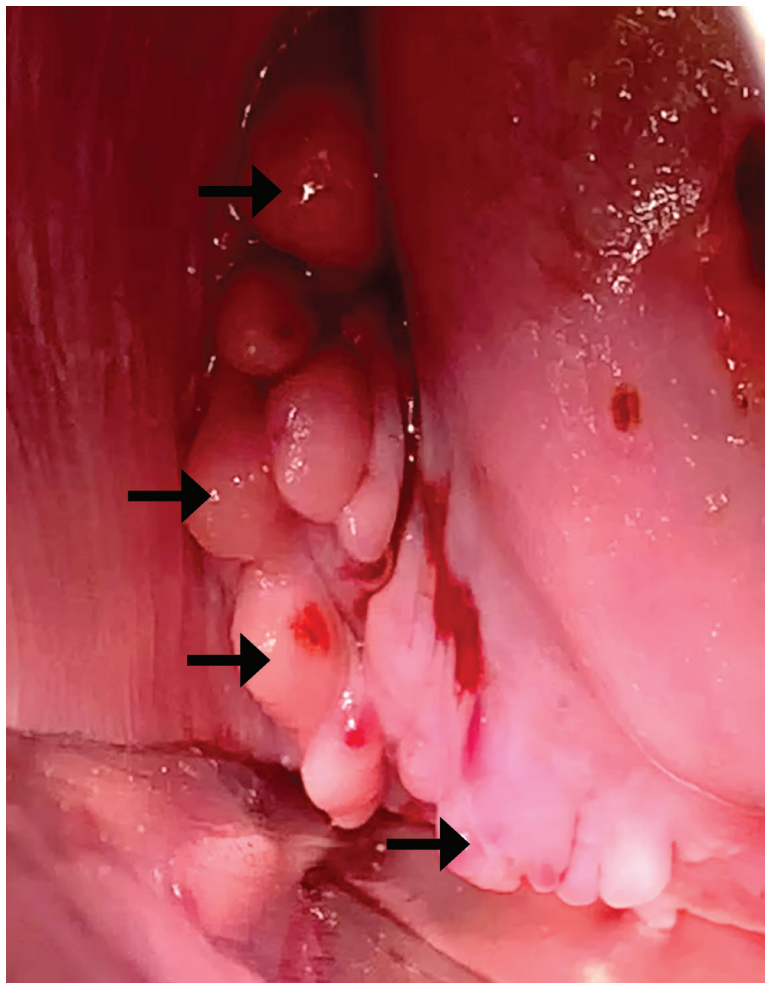
■ Cite as: *CMAJ* 2023 May 1;195:E620-1. doi: 10.1503/cmaj.220466

A healthy 34-year-old woman presented to our gynecology clinic for treatment of a cervical polyp. Medications included a combined oral contraceptive pill (OCP) and ibuprofen for heavy menstrual bleeding and longstanding dysmenorrhea. She had occasional dyschezia and was not sexually active. Her previous Pap tests were normal. Speculum examination revealed numerous polypoid growths in the right posterior vaginal fornix that did not involve the cervix (Figure 1). We undertook a wide local excision in the operating room, and pathology confirmed vaginal polypoid endometriosis (Appendix 1, available at [www.cmaj.ca/lookup/doi/10.1503/cmaj.220466/tab-related-content](http://www.cmaj.ca/lookup/doi/10.1503/cmaj.220466/tab-related-content)).

Focused ultrasonography confirmed an anteverted, anteflexed uterus with diffuse global adenomyosis. The patient's ovaries were normal but relocated to the posterior cervix in the midline as “kissing ovaries,” a sonographic finding associated with severe endometriosis. The rectosigmoid colon was adherent to the right posterior vagina, the site of polypoid growths. We reviewed medical management options for endometriosis with the patient. She opted to transition from a combined OCP of levonorgestrel and 30 µg ethinyl estradiol to one of norethindrone acetate and a lower dose of ethinyl estradiol (10 µg) for targeted endometriosis suppression. Her symptoms improved considerably.

Endometriosis is the presence of endometrial-like glands and stroma outside of the uterine cavity. It is associated with pelvic pain and infertility and occurs in 10%–15% of patients of reproductive age.<sup>1</sup> Polypoid endometriosis is an uncommon variant of endometriosis. It usually presents on the colon and ovaries, and occasionally in the vagina, appearing as large polypoid masses; cancer is often suspected before histologic examination.<sup>2</sup> The most common manifestation of vaginal polypoid endometriosis is postcoital spotting, occasionally leading to hemorrhage.<sup>3</sup>

Treatment options for vaginal polypoid endometriosis are similar to those for pelvic endometriosis, with emphasis on symptom control using progestin- or estrogen-suppressive therapies. For instance, we used norethindrone acetate, a relatively



**Figure 1:** Photograph of vaginal polypoid endometriosis (arrows) visualized during a speculum examination of a 34-year-old woman.

androgenic estrane progestin with proven effectiveness at controlling endometriosis-associated pain.<sup>1</sup> Low-dose ethinyl estradiol with norethindrone acetate, as used in this case, is ideal to reduce stimulation of estrogen-rich endometriotic lesions.<sup>1</sup> Vaginal polypoid lesions can be associated with deep endometriosis involving pelvic structures, the bowel and the vagina. Patients with deep involvement should be referred to a surgeon with expertise in endometriosis when medical management has failed.

## References

1. Dunselman GA, Vermeulen N, Becker C, et al. ESHRE guideline: management of woman with endometriosis. *Hum Reprod* 2014;29:400-12.
2. Parker RL, Dadmanesh F, Young RH, et al. Polypoid endometriosis: a clinicopathologic analysis of 24 cases and a review of the literature. *Am J Surg Pathol* 2004;28:285-97.
3. Ling R, Hontau J, Yang Y, et al. Polypoid endometriosis of the rectum and vagina in an adolescent. *J Pediatr Adolesc Gynecol* 2020;33:581-5.

**Competing interests:** Liane Belland reports honoraria from AbbVie, Olympus, Pfizer and Seaford Pharmaceuticals, and advisory board participation with AbbVie. She is the president of CanSAGE and a member with EndoACT. No other competing interests were declared.

This article has been peer reviewed.

The authors have obtained patient consent.

**Affiliations:** Department of Obstetrics and Gynecology (Marguerie), University of Calgary; Department of Pathology and Laboratory Medicine (Howell), Alberta Precision Labs/Alberta Health Services; Division of Minimally Invasive Gynecologic Surgery, Department of Obstetrics and Gynecology (Belland), University of Calgary, Calgary, Alta.

**Content licence:** This is an Open Access article distributed in accordance with the terms of the Creative Commons Attribution (CC BY-NC-ND 4.0) licence, which permits use, distribution and reproduction in any medium, provided that the original publication is properly cited, the use is noncommercial (i.e., research or educational use), and no modifications or adaptations are made. See: <https://creativecommons.org/licenses/by-nc-nd/4.0/>

**Correspondence to:** Monique Marguerie,  
[monique.marguerie@albertahealthservices.ca](mailto:monique.marguerie@albertahealthservices.ca)

Clinical images are chosen because they are particularly intriguing, classic or dramatic. Submissions of clear, appropriately labelled high-resolution images must be accompanied by a figure caption. A brief explanation (300 words maximum) of the educational importance of the images with minimal references is required. The patient's written consent for publication must be obtained before submission.