

Miliary pattern on chest imaging caused by adenocarcinoma

Yuto Hamada MD PhD, Maki Iwata MD, Kiyoshi Sekiya MD PhD

■ Cite as: *CMAJ* 2022 February 22;194:E259-60. doi: 10.1503/cmaj.211410

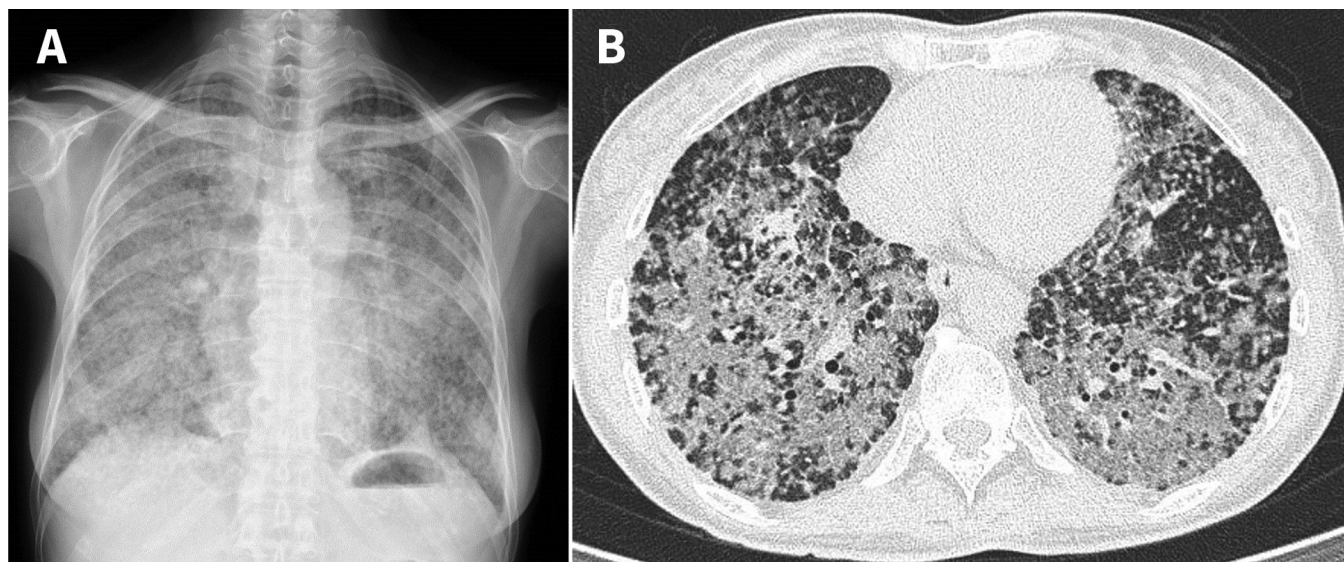


Figure 1: (A) Chest radiograph and (B) computed tomography scan of a 55-year-old woman with lung adenocarcinoma. Both images show a miliary pattern with diffusely distributed, ground-glass opacities overlaying multiple small nodules throughout all lung fields.

A 55-year-old, nonsmoking woman without underlying disease presented to the emergency department with a 3-month history of productive cough, dyspnea, night sweats and 4 kg weight loss. On examination, her temperature was 36.8°C, heart rate was 75 beats per minute, blood pressure was 92/73 mmHg, and respiratory rate was 15 breaths per minute. Her peripheral oxygen saturation was 95% on 3 L/min of oxygen. We heard bilateral inspiratory crackles on chest auscultation and did not observe any clubbing of her digits. Her eosinophil count was 7.7% (normal 0%–6%) and her C-reactive protein level was normal. Chest radiography and computed tomography showed a miliary pattern of many small nodules throughout all lung fields (Figure 1 and video Appendix 1, available at www.cmaj.ca/lookup/doi/10.1503/cmaj.211410/tab-related-content) Real-time polymerase chain reaction (RT-PCR) testing for SARS-CoV-2 was negative.

Our differential diagnoses included tuberculosis, fungal infection and malignant disease. We suspected pulmonary tuberculosis, but 3 sputum smears were negative for acid-fast bacilli, and cultures of sputum and bronchoalveolar lavage fluid were nega-

tive for *Mycobacterium tuberculosis* and fungi. Bronchoscopic biopsy of the right upper lung showed highly differentiated primary lung adenocarcinoma. Whole-body computed tomography and magnetic resonance imaging of the brain did not find any evidence of metastasis outside the lung. Testing with RT-PCR revealed exon 19 deletion in the epidermal growth factor receptor (*EGFR*). The patient was treated with osimertinib, an *EGFR* tyrosine kinase inhibitor. One month later, her resting oxygen requirement had decreased to 1 L/min and the size of the pulmonary nodules had decreased.

Adenocarcinoma with mutations of *EGFR* is observed in 10%–20% of non-Asian patients with non-small cell lung cancer. It is more frequent in women, nonsmokers or light smokers, and in people of Asian descent.¹ The presence of *EGFR* mutations in lung adenocarcinoma is associated with miliary metastases.^{2,3} Compared with chemotherapy, *EGFR* tyrosine kinase inhibitors dramatically improve the response rates and overall survival of patients with advanced non-small cell lung cancer and *EGFR* mutations.^{1,4} Thus, molecular screening after diagnos-

ing lung adenocarcinoma is necessary to identify targetable oncogenic alterations.

References

1. Hirsch FR, Scagliotti GV, Mulshine JL, et al. Lung cancer: current therapies and new targeted treatments. *Lancet* 2017;389:299-311.
2. Hsu F, Nichol A, Toriumi T, et al. Miliary metastases are associated with epidermal growth factor receptor mutations in non-small cell lung cancer: a population-based study. *Acta Oncol* 2017;56:1175-80.
3. Kawata N, Inoue M, Horita N, et al. Multiple nodular pulmonary metastases of lung adenocarcinoma with epidermal growth factor receptor mutation. *Respir Investig* 2016;54:133-5.

Competing interests: None declared.

This article has been peer reviewed.

The authors have obtained patient consent.

Affiliation: Clinical Research Center for Allergy and Rheumatology, National Hospital Organization Sagamihara National Hospital, Kanagawa, Japan

Content licence: This is an Open Access article distributed in accordance with the terms of the Creative Commons Attribution (CC BY-NC-ND 4.0) licence, which permits use, distribution and reproduction in any medium, provided that the original publication is properly cited, the use is noncommercial (i.e., research or educational use), and no modifications or adaptations are made. See: <https://creativecommons.org/licenses/by-nc-nd/4.0/>

Acknowledgement: The authors thank Yuma Fukutomi for helpful comments on the manuscript.

Correspondence to: Yuto Hamada, yutohamada1983@gmail.com



A video of the chest computed tomography of a 55-year-old woman, showing the miliary pattern caused by lung adenocarcinoma with an *EGFR* mutation, is in Appendix 1, available at www.cmaj.ca/lookup/doi/10.1503/cmaj.211410/tab-related-content

4. Ramalingam SS, Vansteenkiste J, Planchard D, et al. Overall survival with

Clinical images are chosen because they are particularly intriguing, classic or dramatic. Submissions of clear, appropriately labelled high-resolution images must be accompanied by a figure caption. A brief explanation (300 words maximum) of the educational importance of the images with minimal references is required. The patient's written consent for publication must be obtained before submission.

osimertinib in untreated, EGFR-mutated advanced NSCLC. *N Engl J Med* 2020; 382:41-50.