

Foramen magnum stenosis in a 5-month-old boy with achondroplasia

Armaan K. Malhotra MD, Whitney Parker MD PhD, Peter B. Dirks MD PhD

■ Cite as: *CMAJ* 2022 September 6;194:E1172. doi: 10.1503/cmaj.220007

A 5-month-old boy was referred by a community pediatrician to clinical genetics at our facility for short stature and macrocephaly. His delivery had been normal, although his parents had noticed snoring from the age of 4 months. He had shortened proximal limb lengths (humerus and femur), bifrontal bossing and a large, flat fontanelle suspicious for achondroplasia. Neurologic examination was normal.

The patient had moderate central sleep apnea diagnosed on polysomnography. Genetic testing confirmed fibroblast growth factor 3 (*FGFR3*) gene mutation and we diagnosed achondroplasia. When he was 10 months old, we performed craniospinal imaging, which showed severe foramen magnum stenosis with cervico-medullary compression (Figure 1). Because of the severe compression with signal change and central sleep apnea, we performed a suboccipital craniectomy and C1 laminectomy. At 2 months' follow-up, the patient's neurologic examination was still normal and developmental milestones were progressing appropriately.

Achondroplasia, a form of skeletal dysplasia, is inherited in an autosomal dominant manner. Most cases occur as a result of pathogenic missense mutations of the *FGFR3* gene (i.e., both parents unaffected).¹ It is the most common cause of short-limb dwarfism, with an incidence of 1 in 10 000 to 30 000.² Patients may have signs of foramen magnum compression, including central sleep apnea, myelopathy, hypotonia, paralysis and motor milestone regression.^{1,2} As a result of shortened Eustachian tube dysfunction and malar hypoplasia, recurrent otitis media and conductive hearing loss may be encountered commonly. Rarely, foramen magnum compression can lead to sudden unexpected death. Children with achondroplasia have a near-normal life expectancy, although they are at increased risk of developing cardiac complications in adulthood.

A national guideline recommends that children with achondroplasia should be screened for craniocervical junction pathology at the time of diagnosis, through a detailed neurologic history, physical examination and request for polysomnography.³ Although rates are improving, recent data suggest only 13.9% of children receive full and appropriate screening for foramen magnum stenosis.⁴ Symptoms such as choking or gagging with feeding, prolonged apnea while sleeping, cyanosis, abnormal limb movements or tone, or central sleep apnea on polysomnography should prompt further evaluation with neuroimaging.³

References

1. Savarirayan R, Ireland P, Irving M, et al. International Consensus Statement on the diagnosis, multidisciplinary management and lifelong care of individuals with achondroplasia. *Nat Rev Endocrinol* 2022;18:173-89.

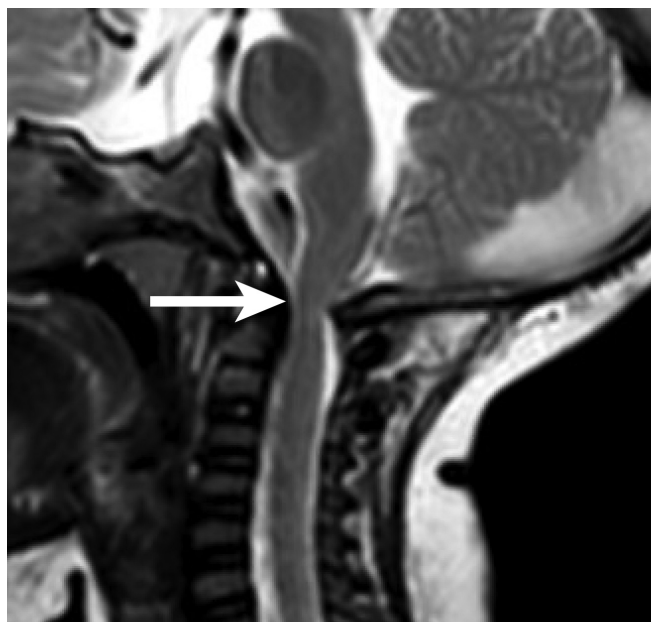


Figure 1: Sagittal T_2 -weighted magnetic resonance image of the neck of our patient at 10 months, showing opisthion hypertrophy with resultant severe compression at the craniocervical junction (white arrow).

2. Horton WA, Hall JG, Hecht JT. Achondroplasia. *Lancet* 2007;370:162-72.
3. Hoover-Fong J, Scott CI, Jones MC; Committee on Genetics. Health supervision for people with achondroplasia. *Pediatrics* 2020;145:e20201010.
4. Nadel JL, Wilkinson DA, Garton HJL, et al. Screening and surgery for foramen magnum stenosis in children with achondroplasia: a large, national database analysis. *J Neurosurg Pediatr* 2018;23:374-80.

Competing interests: None declared.

This article has been peer reviewed.

The authors have obtained patient consent.

Affiliation: Division of Neurosurgery, Hospital for Sick Children, Toronto, Ont.

Content licence: This is an Open Access article distributed in accordance with the terms of the Creative Commons Attribution (CC BY-NC-ND 4.0) licence, which permits use, distribution and reproduction in any medium, provided that the original publication is properly cited, the use is noncommercial (i.e., research or educational use), and no modifications or adaptations are made. See: <https://creativecommons.org/licenses/by-nc-nd/4.0/>

Correspondence to: Armaan Malhotra, ak.malhotra@mail.utoronto.ca