

# Occupational hypersensitivity pneumonitis after polyurethane adhesive exposure

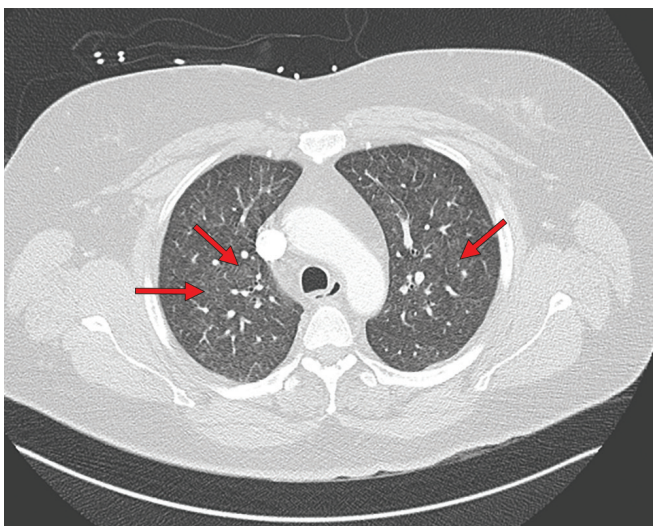
Arbaaz Patel MD, Aasim Hasany MD, Susan M. Tarlo MBBS

■ Cite as: *CMAJ* 2022 August 2;194:E1027-30. doi: 10.1503/cmaj.220052

A 47-year-old woman presented to hospital with a 3-month history of dry cough, wheeze, dyspnea and intermittent fever. She had been briefly admitted 2 months earlier to treat a presumed lower respiratory tract infection or bronchitis; she had been prescribed inhalers (salbutamol, ipratropium) and antibiotics (ceftriaxone and azithromycin initially and then amoxicillin–clavulanic acid).

The patient had smoked 7 cigarettes per day for 12 years, but had stopped smoking 3 months earlier. She was not on any regular medications and her medical history was notable only for obstructive sleep apnea, which was treated with continuous positive airway pressure. She had no history of asthma, no pets and no exposures to hot tubs, birds or moulds at home. She had recently started working at a horticultural company where she made plug sets for plants, in which soil, adhesives, oil and water were combined to create stable moulds for seedlings.

The patient's chest radiograph was normal on presentation and unchanged from her previous admission 2 months earlier. She was referred to the inpatient respirology service. When assessed, her respiratory rate was 22 breaths/min, oxygen saturation was 96% on room air, temperature was 35.9°C, heart rate was 104 beats/min and blood pressure was 129/86 mmHg. She had wheezes bilaterally



**Figure 1:** Computed tomography scan (with contrast) of the chest of a 47-year-old woman with hypersensitivity pneumonitis at the time of hospital admission, showing diffuse, centrilobular ground glass opacities bilaterally.

## Key points

- Hypersensitivity pneumonitis is a type of interstitial lung disease that requires early diagnosis and treatment as it may lead to progressive pulmonary fibrosis.
- An occupational history is essential when evaluating patients with respiratory symptoms.
- Causes of hypersensitivity pneumonitis include infectious agents; enzymes; animal, insect and plant proteins; low-molecular-weight chemicals and metals.
- Patients with respiratory symptoms who have had exposure to isocyanates should avoid the exposure and be assessed for asthma and hypersensitivity pneumonitis.

and normal heart sounds. On examination, she had no evidence of finger clubbing, leg edema, rashes or features to suggest a connective tissue disorder. The emergency department physician ordered a computed tomography (CT) scan of the chest with contrast (pulmonary embolus protocol) to rule out pulmonary embolism.

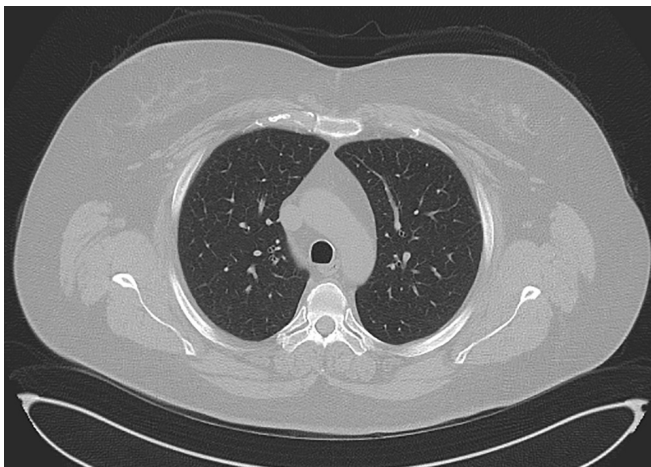
Figure 1 is a representative chest CT image from the time of hospital admission, showing diffuse centrilobular ground glass nodules in both lungs without any zonal predominance. There were no pulmonary emboli. The patient had substantial leukocytosis with neutrophilia (leukocytes 15.6 [normal 4.0–11.0]  $\times 10^9/L$ , neutrophils 12.0 [normal 2.0–7.5]  $\times 10^9/L$ ), a normal eosinophil count (0.2 [normal 0.0–0.5]  $\times 10^9/L$ ) and an elevated C-reactive protein (49 [normal < 8 mg/L]). Because interstitial lung disease was suspected, rheumatoid factor, antinuclear antibody, and cytoplasmic and perinuclear antineutrophil cytoplasmic antibody levels were ordered and were all negative. Brain natriuretic peptide and troponin levels, ordered by an emergency department physician, were within normal limits on both visits to hospital. Spirometry showed proportionate reduction in forced expiratory volume at 1 second (FEV1) and forced vital capacity (FVC), with no evidence of obstruction. Her FVC was 2.13 L (59% predicted), her FEV1 was 1.54 L (53% predicted) and her FEV1:FVC ratio was 72.3%.

A bronchoscopy with bronchoalveolar lavage and transbronchial biopsy was performed. The fluid from bronchoalveolar

lavage of the right upper lobe was negative for malignant cells with few lymphocytes, eosinophils and hemosiderin-laden macrophages. Insufficient leukocytes were present to allow an accurate cell count. Cultures from fluid samples were negative for bacteria, fungi and mycobacteria. A transbronchial biopsy of the right middle lobe showed chronic inflammation, diffuse fibrosis and reactive epithelial proliferation.

Because of the clinical, radiographic and bronchoscopic findings, the working diagnosis was hypersensitivity pneumonitis, most likely from the patient's occupational exposure to adhesives. She was started on intravenous solumedrol, felt immediate relief in her dyspnea and cough, and was discharged on prednisone (30 mg/d) with a tapering script for 2 months. She was advised to avoid exposure to adhesives. She was followed up after a few weeks in the outpatient clinic, with near resolution of symptoms.

The patient was seen at our occupational lung clinic 3 months after discharge from hospital and we confirmed the occupational history. The patient had taken pictures with her mobile phone of



**Figure 2:** High-resolution computed tomography scan of the chest of a 47-year-old woman with hypersensitivity pneumonitis after treatment and avoidance of the antigen, showing complete resolution of centrilobular ground glass opacities.

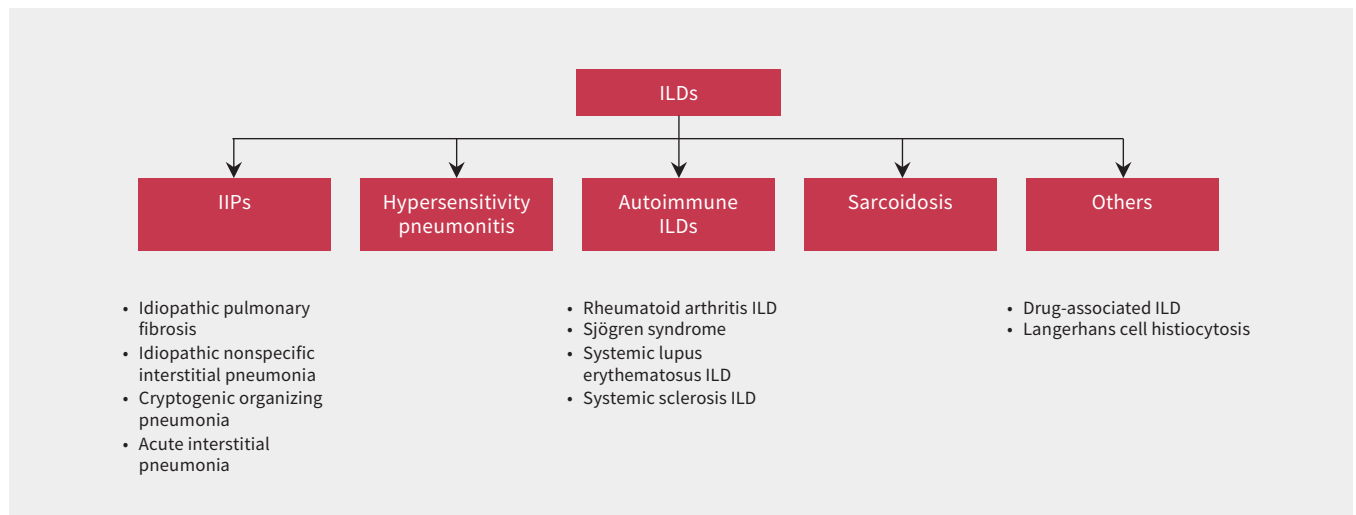
the labels of the products she was using at work, which confirmed that she was exposed to toluene di-isocyanate (TDI), a compound found in polyurethane-based adhesives that can be highly immunogenic to the lungs. She said that, when producing the plug sets, the heated polyurethane adhesive would often bubble and aerosolize as it was poured into the soil mix. Despite using surgical masks and high-quality respirators, she continued to have respiratory symptoms.

Because the patient had been advised to stop exposure to TDI, her employer found other work for her in a building without any exposures to isocyanates. Prednisone therapy for 1 month led to marked improvement in symptoms and on objective tests. Compared with values at time of hospital admission, her pulmonary function test at 4 weeks after discharge showed more than 25% improvement in FVC and FEV1. Her FVC was 2.86 L (79% predicted) and FEV1 was 2.38 L (82% predicted). In addition, her total lung capacity was 4.61 L (89% predicted) and diffusion capacity was 16.6 mL/min/mm Hg (78% predicted). The follow-up CT of her chest 1 month after starting treatment with prednisone showed complete clearing of the ground glass nodules in the lungs (Figure 2). Outpatient allergy testing was negative to mould and other common environmental allergens.

## Discussion

Occupational lung diseases are a common group of respiratory disorders. Although some of these diseases, such as asbestosis and silicosis, are almost always caused by work exposures, conditions such as asthma, chronic obstructive pulmonary disease and interstitial lung disease are caused or exacerbated by occupational exposures in about 25% of cases.<sup>1</sup> A classification of interstitial lung disease is provided in Figure 3.

Hypersensitivity pneumonitis, formerly known as extrinsic allergic alveolitis, is a type of interstitial lung disease caused by inhalation of antigens that induce nonimmunoglobulin (Ig) E-mediated immune dysfunction in the lungs. If untreated, hypersensitivity pneumonitis can lead to progressive lung



**Figure 3:** Classification of select types of interstitial lung diseases (ILDs). Note: IIP = idiopathic interstitial pneumonia. Adapted from Cottin and colleagues<sup>2</sup> and published with permission from the European Respiratory Society.

fibrosis with associated morbidity and death.<sup>3</sup> About 20% of cases of hypersensitivity pneumonitis are caused by an occupational exposure. Therefore, any patient suspected to have hypersensitivity pneumonitis based on either history or imaging should be asked for a detailed occupational history.<sup>4</sup> More than 200 antigens have been reported to cause hypersensitivity pneu-

monitis. Although it is frequently associated with farming, bird and mould exposures, many cases of hypersensitivity pneumonitis have no clearly identified antigen.<sup>5</sup> Exposure to di-isocyanate, used in polyurethanes in our patient's case, is commonly associated with asthma, but is also one of many agents known to cause occupational hypersensitivity pneumonitis (Table 1).<sup>5-7</sup>

**Table 1: Select list of important agents known to cause occupational hypersensitivity pneumonitis\***

Type	Agent	Exposure examples
Bacteria	<i>Thermophilic actinomycetes</i>	Farmers, bagasse workers, mushroom workers, potato riddlers, compost workers, ventilation systems
	<i>Lichtheimia corymbifera</i>	Farmers
	<i>Acinetobacter, Ochrobactrum</i>	Metal working fluids
	<i>Streptomyces albus</i>	Compost workers
	<i>Klebsiella oxytoca</i>	Humidifiers
	<i>Bacillus subtilis</i> enzymes	Detergent industry
	<i>Mycobacterium avium</i> complex and other nontuberculous mycobacteria	Spa workers
	<i>Mycobacterium immunogenum</i>	Metal working fluids, machine operators
Fungi	<i>Alternaria alternata</i>	Humidifiers, wood workers
	<i>Aspergillus spp.</i>	Stucco workers, tobacco growers, malt workers
	<i>Trichosporon cutaneum</i>	Seasonal mold contamination in homes
	<i>Penicillium species</i>	Cork workers, cheese workers, food processors, peat moss processors
	<i>Cryptostroma corticale</i>	Maple bark strippers, florists
	<i>Botrytis cinerea</i>	Wine makers
	<i>Mucor stolonifer</i>	Paprika slicers
	<i>Rhodotorula</i>	Humidifiers
	Various mushrooms ( <i>Shiitaki, Bunashimeji, Pleurotus, Pholiota, Shimeji, Agaricus</i> )	Mushroom workers
Enzymes	Phytase, subtilisin	Animal feeding, cleaners
Animal & insect proteins	Avian serum and feather proteins	Bird breeders
	Rat serum proteins	Laboratory workers
	Pearl	Pearl industry
	Mollusk shell	Nacre industry
	Silk	Textile workers
	Carmine	Food and cosmetic industry
	<i>Sitophilus granarius</i>	Farmers
Plant proteins	Tiger nuts, legumes (e.g., soy), malt	Food processors
	Alginate	Seaweed workers
	Woods (ramin, pine)	Wood workers
	Esparto dust	Stucco workers
Low-molecular-weight chemicals	Di-isocyanates	Chemical and polyurethane industry, painters
	Acid anhydrides	Plastic workers, aircraft industry
	Acrylate compounds	Dental technicians
	Triglycidyl isocyanurate	Painters (powder paint)
	Pharmaceutical agents (penicillins, cephalosporins)	Pharmaceutical industry
	Dimethyl phthalate and styrene	Yacht manufacturing
Metals	Cobalt	Hard-metal workers
	Zinc	Smelters
	Zirconium	Ceramic workers

\*Adapted from Quirce and colleagues<sup>6</sup> and published with permission from John Wiley and Sons.

Isocyanates are low-molecular-weight compounds classified as either mono-, di- or polyisocyanates. Methylene diphenyl diisocyanate and TDI represent 95% of the di-isocyanates used to create polyurethane polymers, with TDI being important for production of paint coating, adhesives and insulating foam.<sup>8</sup> Given its association with lung disease, patients with respiratory symptoms and history of exposure to di-isocyanate-containing polyurethanes should be investigated with pulmonary function testing and chest imaging (preferably high resolution CT) to rule out asthma and hypersensitivity pneumonitis when other diagnoses are less likely.

The diagnosis of hypersensitivity pneumonitis can be relatively challenging given a lack of standardized and validated diagnostic criteria. Recent consensus guidelines highlight important factors that support the diagnosis, including exposure history, supportive CT imaging, bronchoalveolar lavage indicating lymphocytosis, histopathological findings (e.g., poorly formed granulomas, cellular interstitial pneumonia, bronchiolitis) and specific serum IgG testing to exposed antigens.<sup>9,10</sup> According to expert panels, when findings on high-resolution CT are suggestive of hypersensitivity pneumonitis and there is a known antigen exposure (either through history or laboratory findings), lymphocytosis on bronchoalveolar lavage is sufficient to be highly confident in the diagnosis. In its absence, however, a lung biopsy should be obtained to accurately diagnose hypersensitivity pneumonitis.<sup>9</sup>

In our patient, the combination of history, imaging and biopsy findings supported the diagnosis of hypersensitivity pneumonitis. The lack of lymphocytosis on bronchoalveolar lavage could be because of the early fibrosis noted on biopsy, as well as the patient's smoking history. The onset of symptoms soon after starting work, and the dramatic improvement of symptoms with prednisone treatment and avoidance of TDI further supported the diagnosis. We did not assess specific serum IgG to TDI, but the results would not have changed our diagnostic certainty, since positive tests can occur from exposure without disease and negative tests do not exclude the diagnosis when exposure has been removed.

We considered alternate diagnoses, such as asthma and respiratory bronchiolitis, as part of the differential diagnosis but we rejected these given bloodwork, findings on imaging and bronchoscopy, lack of airflow obstruction on pulmonary function testing and the fact that the patient's symptoms worsened after smoking cessation. Furthermore, given the timing of our patient's symptoms, the conclusion that this was an occupational exposure rather than exposure to an environmental allergen outside of the workplace was quite clear.

## Conclusion

Our case highlights the importance of obtaining an occupational history when assessing patients with respiratory symptoms. In particular, it is important to ask about specific exposures to agents such as birds, moulds and polyurethanes, given their known associations with lung disease. Hypersensitivity pneumonitis is a type of interstitial lung disease that is often caused by occupational exposures. Early detection is crucial since it can progress to lung fibrosis, which is associated with substantial morbidity and death.

## References

1. Tarlo SM, Lemiere C. Occupational asthma. *N Engl J Med* 2014;370:640-9.
2. Cottin V, Hirani NA, Hotchkiss DL, et al. Presentation, diagnosis and clinical course of the spectrum of progressive-fibrosing interstitial lung diseases. *Eur Respir Rev* 2018;27:180076. doi: 10.1183/16000617.0076-2018.
3. Wild LG, Lopez M. Hypersensitivity pneumonitis: a comprehensive review. *J Invest Allergol Clin Immunol* 2001;11:3-15.
4. Blanc PD, Annesi-Maesano I, Balmes JR, et al. The occupational burden of non-malignant respiratory diseases. An official American Thoracic Society and European Respiratory Society statement. *Am J Respir Crit Care Med* 2019;199:1312-34.
5. Barnes H, Lu J, Glaspole I, et al. Exposures and associations with clinical phenotypes in hypersensitivity pneumonitis: a scoping review. *Respir Med* 2021;184:106444. doi: 10.1016/j.rmed.2021.106444.
6. Quirce S, Vandenplas O, Campo P, et al. Occupational hypersensitivity pneumonitis: an EAACI position paper. *Allergy* 2016;71:765-79.
7. Tarlo SM, Liss GM. Diisocyanate-induced asthma: diagnosis, prognosis, and effects of medical surveillance measures. *Appl Occup Environ Hyg* 2002;17:902-8.
8. Lhoumeau A, Pernot J, Georges M, et al. Hypersensitivity pneumonitis due to isocyanate exposure in an airbag "welder". *Eur Respir Rev* 2012;21:168-9.
9. Pérez ER, Travis WD, Lynch DA, et al. Diagnosis and evaluation of hypersensitivity pneumonitis: CHEST guideline and expert panel report. *Chest* 2021;160:e97-e156.
10. Raghu G, Remy-Jardin M, Ryerson CJ, et al. Diagnosis of hypersensitivity pneumonitis in adults. An official ATS/JRS/ALAT clinical practice guideline. *Am J Respir Crit Care Med* 2020;202:e36-69.

**Competing interests:** Aasim Hasany reports speaker fees from Sanofi and payment from Allergy Research Canada for being a subinvestigator in an asthma research study. Susan Tarlo reports grants from the Ontario Workplace Safety and Insurance Board (WSIB) and from the Centre for Research Excellence in Occupational Diseases (supported by the Ontario Ministry of Labour and Development), royalties (*Asthma in the Workplace*, 5th edition), consulting fees from the WSIB and an honorarium from the Occupational Medicine Society of Canada. She also reports committee membership with the American Academy of Allergy, Asthma and Clinical Immunology, and with the European Academy of Allergy Asthma and Clinical Immunology. She is co-editor with *Current Opinion in Allergy and Clinical Immunology*. No other competing interests were declared.

This article has been peer reviewed.

The authors have obtained patient consent.

**Affiliations:** Michael G. DeGroot School of Medicine (Patel), McMaster University, Hamilton, Ont.; Michael G. DeGroot School of Medicine (Hasany), Niagara Regional Campus, McMaster University, St. Catharines, Ont.; University Health Network (Tarlo), University of Toronto, Toronto, Ont.

**Contributors:** All of the authors contributed to the conception and design of the work, drafted the manuscript, revised it critically for important intellectual content, gave final approval of the version to be published and agreed to be accountable for all aspects of the work.

**Content licence:** This is an Open Access article distributed in accordance with the terms of the Creative Commons Attribution (CC BY-NC-ND 4.0) licence, which permits use, distribution and reproduction in any medium, provided that the original publication is properly cited, the use is noncommercial (i.e., research or educational use), and no modifications or adaptations are made. See: <https://creativecommons.org/licenses/by-nc-nd/4.0/>

**Correspondence to:** Aasim Hasany, [aasim.hasany@niagarahealth.on.ca](mailto:aasim.hasany@niagarahealth.on.ca)