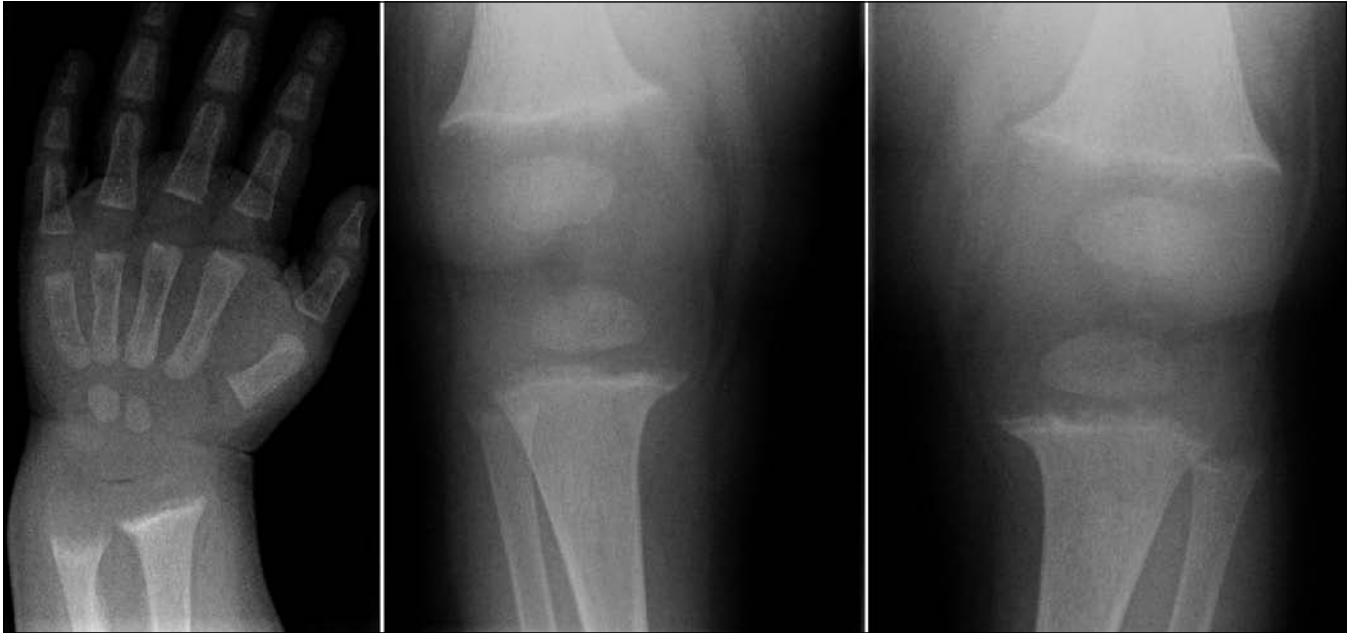

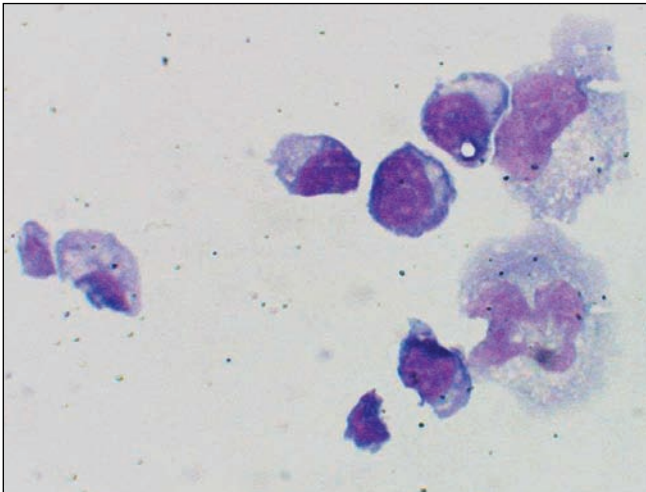
PRACTICE

CLINICAL VISTAS BRIEFS

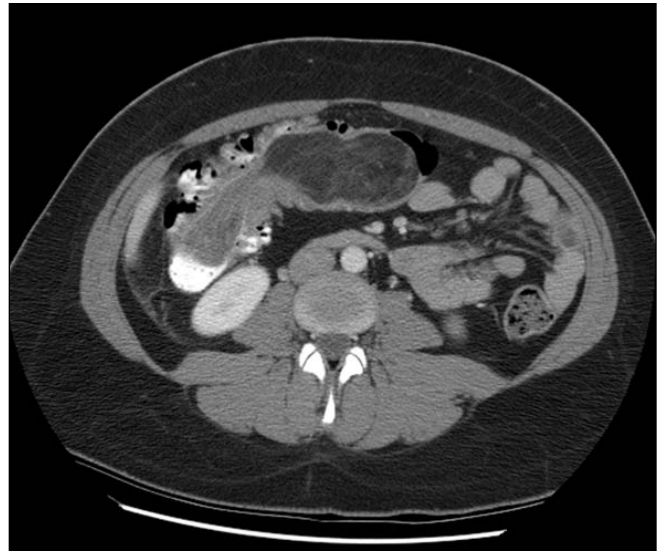
What's your call?



Plain radiographs of a 13-month-old boy of African descent.



Slide of a sample of cerebrospinal fluid (CSF) from a 41-year-old woman with headache, fever and nuchal rigidity. She reported that she'd had benign aseptic meningitis 15 years ago and recurrent headaches since 2 years ago, associated with herpetic lesions on her buttocks and lower back.



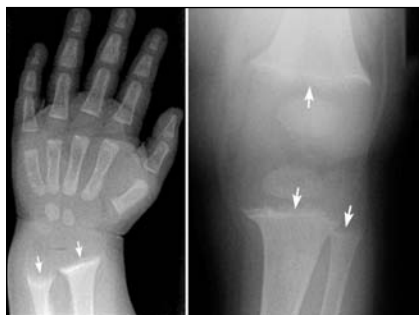Axial contrast-enhanced CT scan of the abdomen of a 31-year-old woman. At the time, she had experienced "crampy" right-sided abdominal pain and vomiting for 5 days.

See page 1712 for diagnoses.

CLINICAL VISTAS BRIEFS

Rickets

When enlargement of this boy's costo-chondral junctions was noted incidentally on a chest radiograph, additional skeletal images were ordered. They revealed widening, fraying, cupping and irregularity of the metaphyseal border of his distal radius and ulna (Fig. 1), with osteomalacia of his long bones.



Findings from the child's history, his physical examination and specific laboratory tests confirmed a diagnosis of a nutritional deficiency of vitamin D. His treatment included a high dose of oral vitamin D₃ and calcium gluconate until the biochemical abnormalities resolved. Radiographically, the metaphyseal abnormalities disappeared after 3 months of treatment (Appendix; available: www.cmaj.ca/cgi/content/full/174/12/1710/DC1).

Rickets results from inadequate vitamin D supplementation among infants fed exclusively on breast milk. Dark-pigmented skin and the relative insufficiency of sun exposure in the Canadian climate are additional risk factors.

To prevent rickets, all breast-fed infants should receive at least 400 IU of vitamin D₃ daily (in northern communities, 800 IU) until they reach 1 year of age or their daily diet includes at least 400 IU (10 µg) of vitamin D from other dietary sources (*Paediatr Child Health* 2002;7:464-5, available at www.cps.ca/english/statements/II/ii02-02.htm).

Maria Otilia Dobrescu, Ana Carceller Garcia, Monique Robert
Department of Pediatrics, CHU Sainte-Justine, University of Montreal, Montréal, Que.

DOI:10.1503/cmaj.051414

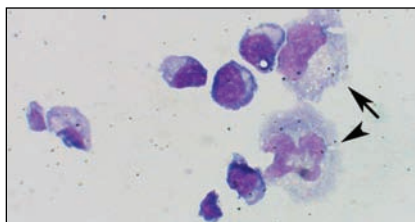
Mollaret's meningitis

May-Grunwald-Giemsa staining of CSF revealed large monocytes with blunt pseudopods and bean-shaped (arrow, in Fig. 1) and bilobed nuclei (arrowhead). Further examination disclosed 114 leukocytes (all mononuclear cells), 0.75 mg protein, 2.8 µmol glucose and 3.1 µmol lactate per millilitre of CSF.

The cells were identified as Mollaret cells. The CSF sample tested positive by polymerase chain reaction for herpes simplex virus type 2. Acyclovir was prescribed for the patient, who recovered completely.

Recurrent benign aseptic meningitis was described in 1944 by Pierre Mollaret. Episodes usually resolve without clinical intervention; they persist from a few days to a few weeks, but may recur weekly or monthly for up to 5 years. The virus most commonly isolated is herpes simplex type 2 (*Ann Intern Med* 1994; 121:334-8), but during an episode herpetic lesions may nonetheless be absent.

Hypercellularity and prominent pleocytosis is almost always present. The monocytes usually occur singly or in small aggregates and show atypical cell morphology (deeply lobated or cleft nuclei), but the cytomorphology can vary (*Diagn Cytopathol* 2003;28:227-31). Mollaret cells have also been described in reports of various other diseases, such as West Nile virus infection, sarcoidosis and Behçet's disease.



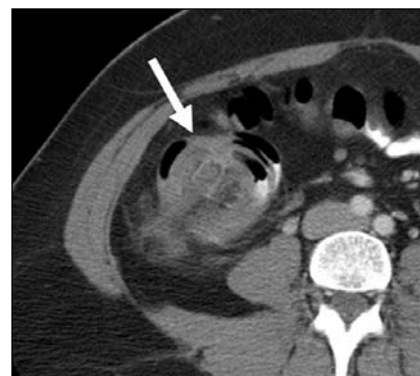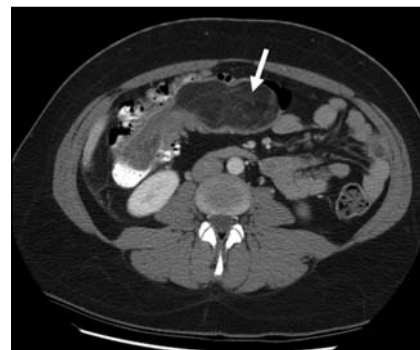Because it may resolve spontaneously, the role of antiviral therapy in Mollaret's meningitis is often questioned. In selected cases, acyclovir may be useful.

Parham Sendi, Peter Graber
Unit of Infectious Diseases, Basel University Medical Clinic, Liestal, Switzerland

DOI:10.1503/cmaj.051688

Colonic intussusception

Depending on its orientation relative to the image plane, this type of intestinal process appears as a sausage-like (Fig. 1) or target-like mass (Fig. 2). The lead-point lesion in this case was found at pathology to be an intraluminal lipoma.



Lipoma is a benign large-bowel tumour, the second most common after colonic adenoma. Autopsy series have reported incidences of lipoma of up to 5.8% (*Radiol Clin North Am* 2003;41: 1137-51).

Mark S. Landis
Faculty of Medicine, University of Toronto, Toronto, Ont.
Jean-Pierre A. Martel, Michael C. Ott
Departments of Diagnostic Radiology and Nuclear Medicine (Martel) and Surgery (Ott), University of Western Ontario, London, Ont.

DOI:10.1503/cmaj.051445