

# New advances in the management of acute coronary syndromes:

## 2. Fibrinolytic therapy for acute ST-segment elevation myocardial infarction

Paul W. Armstrong

### The case

Mrs. C, an 81-year-old woman, arrives at the emergency department of a community hospital 4 hours after the onset of crushing retrosternal chest pain. The pain radiates to her back, shoulders and arms and is associated with diaphoresis. Earlier in the ambulance she experienced a ventricular fibrillation cardiac arrest, and after brief cardiopulmonary resuscitation and 2 counter shocks, sinus rhythm was restored. In the emergency department she is alert and conscious. Examination reveals a small woman weighing 60 kg. Her heart rate is 90 beats/min, the blood pressure is 155/95 mm Hg, and the jugular venous pressure is 3 cm elevated above the sternal angle at 45° with a normal respiratory pattern. There are bilateral rales one-quarter of the way up the lung bases posteriorly, an S<sub>4</sub> gallop and a 2/6 midsystolic murmur at the apex. An electrocardiogram reveals sinus rhythm, a P-R interval of 0.20 seconds and a 2-mm ST-segment elevation in leads II, III and aVF without anterior ST-segment depression. Mrs. C has been given oxygen nasally, nitroglycerin sublingually, 160 mg of ASA orally and 2.5 mg of morphine intravenously. The emergency physician is consulted by the nurse about the indications for, and choice of, a fibrinolytic agent.

**T**imely, effective and sustained reperfusion of the culprit coronary artery thrombosis mediating acute ST-segment elevation myocardial infarction has been the most important therapeutic advance in the care of such patients in the modern era.<sup>1</sup> In this article, I will review the following aspects of fibrinolytic therapy: pharmacologic characteristics, clinical application, the importance of concomitant therapy, and current investigations that are likely to have future therapeutic implications. (An information sheet for patients appears in Appendix 1.)

### Pharmacologic characteristics

A diagram of the endogenous fibrinolytic system is depicted in Fig. 1. The most venerable fibrinolytic agent in clinical use, and the most commonly used world wide, is streptokinase (SK).<sup>2</sup> The properties and method of administration of SK, as well as those of other fibrinolytic agents generally available or soon to be released, are summarized in Table 1. Because of SK's streptococcal origin, it is associated with a rapid rise in neutralizing antibodies, which makes repeat administration impractical except very early after the initial dose.<sup>3</sup> SK administration is associated with conversion of plasminogen to plasmin and a marked decline in circulating fibrinogen and other coagulation factors, which thereby promotes a systemic lytic state. This effect circumvents the need for concomitant heparin therapy and may enhance coronary reperfusion at the cost of a modest increase in systemic bleeding complications. Systemic hypotension or bradycardia, or both, especially in patients with inferior myocardial infarction, are well-recognized side effects and may be avoided with the administration of intravenous fluids and atropine as well as careful monitoring regarding concomitant nitroglycerin therapy.

Tissue plasminogen activator (tPA) is a more fibrin-selective, shorter-acting proteolytic enzyme that is a natural product of the vascular endothelium. It is also pro-

*Review*

*Synthèse*

**Dr. Armstrong is Professor of Medicine (Cardiology) at the University of Alberta, Edmonton, Alta.**

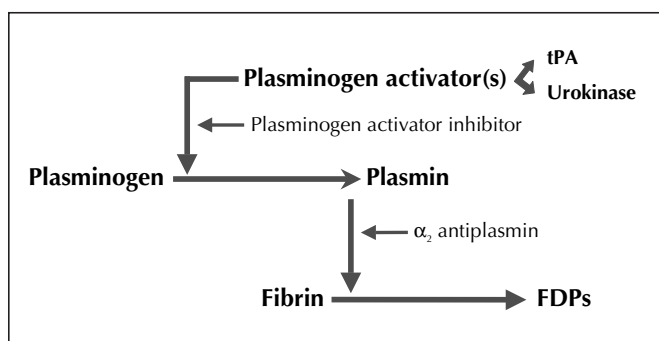
*This article has been peer reviewed.*

CMAJ 2001;165(6):791-7

**Series editor:** Dr. Paul W. Armstrong, Professor of Medicine (Cardiology), University of Alberta, Edmonton, Alta.

*An information sheet for patients appears at the end of the article.*

duced by recombinant technology (rtPA), and when given as a bolus and step-down weight-adjusted infusion over 90 minutes, it produces greater early patency of the coronary artery and a 14% relative, 1% absolute reduction in mortality as compared with SK.<sup>4,5</sup> Although associated with less systemic bleeding than SK, rtPA has the disadvantage of requiring concomitant intravenous heparin therapy to reduce the frequency of reocclusion. Compared with SK, rtPA is also associated with an approximate 0.5% excess in intracranial hemorrhage, especially in low-weight, elderly patients, and is about 9 times more expensive. Several mutants of rtPA have been developed for potential clinical application, but for the purposes of this discussion, only 2 will be considered here. The first of these is reteplase, a deletion mutant with a longer plasma half-life than rtPA; it is administered as a double bolus of 10 units each, given 30 minutes apart. When tested in a large phase III study against rtPA, the 30-day death rates were similar (reteplase 7.47% and rtPA 7.24%), but formal equivalence between these agents was not established.<sup>6</sup>



**Fig. 1: Overview of endogenous fibrinolytic system, showing the important interaction between both natural plasminogen activators — tissue plasminogen activator (tPA) and urokinase — and their substrate plasminogen to form plasmin. Plasmin then degrades fibrin into fibrin degradation products (FDPs). Counteracting this system are 2 natural inhibitors — plasminogen activator inhibitor and  $\alpha_2$ -antiplasmin — which are extruded from activated platelets.**

The most recent rtPA derivative to become generally available is tenecteplase, a triple substitution mutant with enhanced fibrin-specificity and a longer half-life than rtPA, which permits single-bolus administration. When tested in a large phase III study it proved equally effective as rtPA and had the added advantage of a modest decrease in systemic bleeding and transfusion requirement.<sup>7</sup> Tenecteplase has been approved for general use in the United States and is expected to become available in Canada soon.

### Clinical application

Substantial evidence supports the use of fibrinolytic therapy for acute ST-segment elevation myocardial infarction. The clinician must be alert to appropriate indications, contraindications, the importance of timely decision-making, the evaluation of the success of therapy and contingency plans for alternative strategies if fibrinolysis fails or is contraindicated (Fig. 2). There is overwhelming evidence of benefit within the first 12 hours after symptom onset; however, the strength of this effect wanes over time, with the maximal benefit occurring within the first hour and a progressive lessening of the number of lives saved per 1000 patients treated (i.e., an approximate decline of benefit of 1.6 lives per 1000 patients treated per hour delay).<sup>8</sup> Hence, if ischemic symptoms within this 12-hour window suggest an acute myocardial infarction and there is ST-segment elevation of at least 1 mm in 2 contiguous ECG leads or a bundle-branch block that is presumed to be new, rapid reperfusion is indicated. Therapy should proceed immediately provided there are no absolute contraindications (active bleeding or a known bleeding diathesis, major recent trauma or surgery, prior stroke or intracranial disease, or suspicion of aortic dissection) or relative contraindications (severe uncontrolled hypertension [greater than 180/110 mm Hg], elevated international normalized ratio in association with oral anticoagulant therapy or other factors, pregnancy, a recent noncompressible vascular puncture or recent laser therapy of the retina).

Patients most likely to benefit are those who present

**Table 1: Doses and properties of fibrinolytic regimens for acute ST-segment elevation myocardial infarction**

Variable	Streptokinase	rtPA	Reteplase	Tenecteplase
Dose	1.5 million U over 30–60 min	15-mg bolus plus infusion of 0.75 mg/kg over 30 min and 0.5 mg/kg over 60 min (total dose $\leq$ 100 mg)	Two 10-mg boluses given 30 min apart	Single bolus of 0.5 mg/kg (range 30–50 mg)
Plasma half-life, min	23–29	4–8	15	20
Fibrin specificity	–	++	+	+++
90-min patency	++	+++	++++	+++
Mortality reduction	+	++	++	++
Hemorrhagic stroke	+	++	++	++
Systemic bleeding	+++	++	++	+
Heparin required?	No	Yes	Yes	Yes

Note: rtPA = recombinant tissue plasminogen activator, rPA = reteplase, – = absent, + = slight, ++ = moderate, +++ = substantial, ++++ = superior.

early after symptom onset, exhibit substantial territory at risk (i.e., major anterior ST-segment elevation) and are elderly. Although some controversy exists regarding fibrinolytic therapy in patients over the age of 75 years, recent data from the Fibrinolytic Therapy Trialists' overview of about 60 000 patients confirms a 3.4% absolute mortality risk reduction at 30 days in this age group (29.4 to 26.0;  $p = 0.03$ ).<sup>9,10</sup> This benefit occurs despite a substantial rise in the risk of hemorrhagic stroke in elderly patients, especially with the use of more fibrin-specific agents such as rtPA.

The clinical evaluation of the efficacy of fibrinolytic therapy is an important but imperfect process (Fig. 2). Although relief of pain, resolution of the initial ST-segment elevation (by at least 50%) and clinical stability are favourable indicators, they are by no means highly reliable. Failure to achieve these goals, however, may be an indication for early invasive study and rescue angioplasty. Recurrent symptoms and re-elevation of the ST segment may respond to repeat fibrinolysis, but they are ideally managed with urgent angiography and appropriate mechanical intervention.<sup>11</sup> SK should not be readministered (because of immunizing antibody formation) except within the first 3 to 4 days after its initial administration.<sup>3</sup>

If fibrinolytic therapy is contraindicated, direct reperfusion with percutaneous coronary intervention is an important alternative. Recent advances in the concomitant use of intracoronary stents and pharmacologic therapy with glycoprotein IIb/IIIa platelet inhibitors have enhanced the efficacy and safety of this approach.<sup>12,13</sup> Selected institutions with the facilities, experience and available staff are using direct mechanical intervention in lieu of fibrinolysis. Given the feasibility and costs of this approach, it is unlikely to be applicable to the broad cross-section of patients with acute ST-segment elevation myocardial infarction.<sup>14</sup> It is the preferred approach in patients with cardiogenic shock; however, if timely mechanical intervention is not feasible, intravenous SK therapy is a reasonable initial treatment (sometimes with associ-

ated vasopressor support) while arrangements for transfer to a tertiary care centre are being made.<sup>1</sup>

The advent of bolus fibrinolytic therapy and the continuing problem of delays to treatment delivery have led to a resurgence of interest in pre-hospital fibrinolysis to enhance patient outcome.<sup>15,16</sup> Notwithstanding the associated logistical challenges, the advent of new technologies to facilitate high-quality wireless ECG transmission coupled with simple algorithms to ensure optimal patient selection and reduce risk are likely to contribute substantially to patient care.<sup>17</sup> Under-treatment in appropriate candidates and delay in timely administration of therapy are key aspects of the process of care that require continuous monitoring and internal audit to ensure their recognition and avoidance.<sup>1</sup>

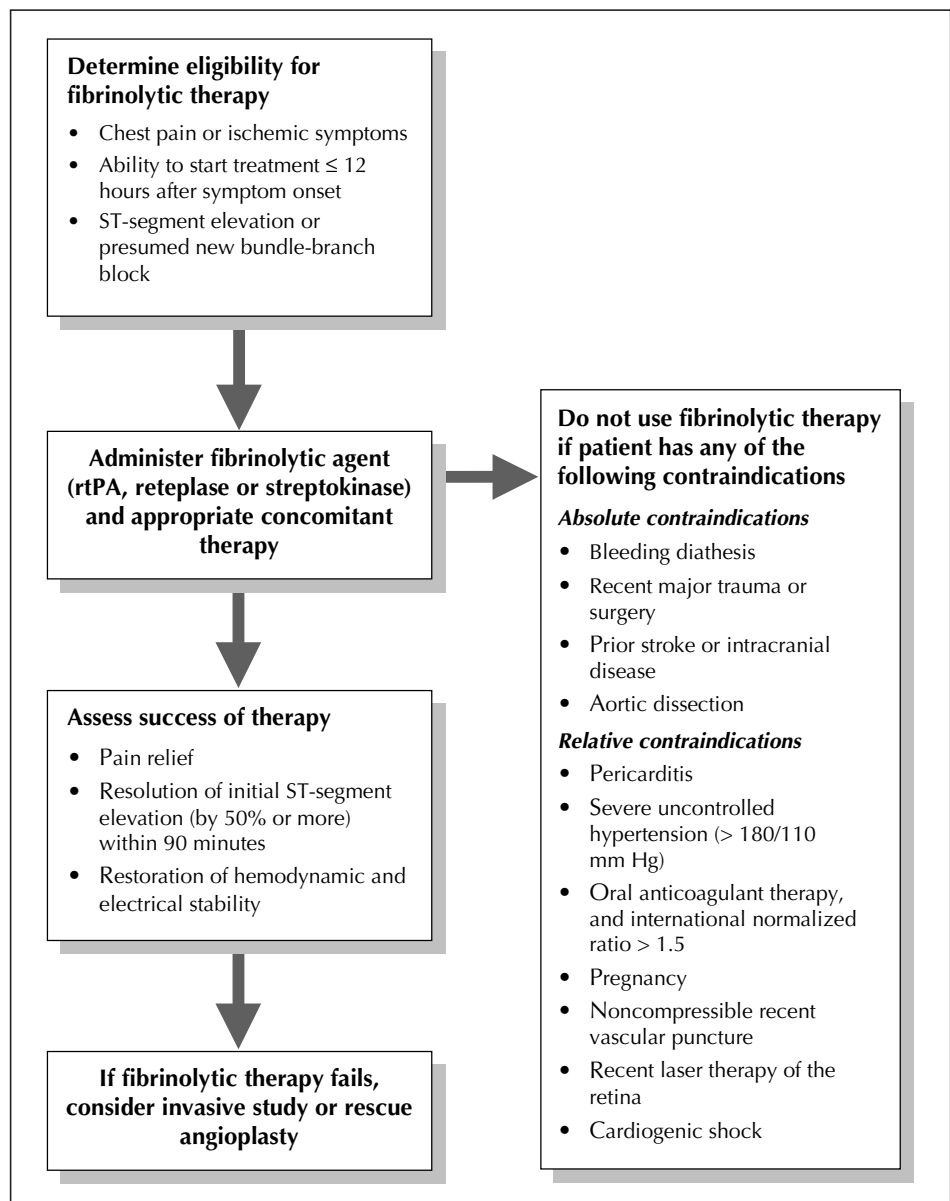


Fig. 2: Summary of steps in the treatment of acute ST-segment elevation myocardial infarction with fibrinolytic therapy. rtPA = recombinant tissue plasminogen activator.

Although a recent meta-analysis has suggested that bolus fibrinolysis may be associated with excess intracranial hemorrhage,<sup>18</sup> there are substantial limitations with this thesis, and a meta-analysis of the 2 bolus agents available for general use (reteplase and tenecteplase) in over 30 000 patients showed no increase in the incidence of intracranial hemorrhage when compared with accelerated rtPA therapy.<sup>19</sup>

## Concomitant therapy

It is useful to classify concomitant therapy into 2 main categories: *adjunctive* (designed to minimize the effects of myocardial ischemia on the myocardium as well as the effects of myocardial injury associated with reperfusion) and *conjunctive* (designed to improve and preserve coronary perfusion at both the macro- and micro-circulatory level). Intravenous  $\beta$ -blocker therapy, especially in patients with tachycardia and hypertension in the absence of advanced congestive heart failure, followed by oral  $\beta$ -blocker therapy on the first day may reduce the myocardial oxygen consumption and enhance long-term survival.<sup>20</sup> Oral angiotensin-converting enzyme (ACE) inhibitor therapy begun within the first 12–24 hours after symptom onset promotes infarct healing and favourable ventricular remodelling when left ventricular dysfunction is present. If ACE inhibitors are contraindicated, nitrates are a useful alternative and may also help to ameliorate ischemia or congestive heart failure.

Because fibrinolytic agents are paradoxically procoagulant and ineffective on the platelet-rich component of the thrombus, all patients should receive ASA immediately upon admission.<sup>21,22</sup> Intravenous heparin therapy, using a weight-adjusted bolus and infusion, coupled with early (within 3 hours) determination of the activated partial thromboplastin time (aPTT), is valuable in conjunction with all fibrinolytic therapy except SK therapy. Recent guidelines from the American College of Cardiology/American Heart Association Task Force on Practice Guidelines call for a bolus of unfractionated heparin of 60 U/kg (maximum 4000 U) followed by an infusion of 12 U/kg per hour (maximum 1000 U/h), with a target aPTT of 50–70 seconds during the initial 48 hours and provision for down-titration at 3 hours if the aPTT is greater than 70 seconds.<sup>20</sup>

## Current research and future directions

Substitution of unfractionated heparin with low-molecular-weight heparin is currently being investigated. Other antithrombin strategies using direct antithrombins are also being studied.

Important data from phase II clinical trials have emerged to support the possibility that half-dose fibrinolytic therapy in conjunction with intravenous glycoprotein IIb/IIIa platelet inhibition may enhance coronary artery reperfusion at both the macro- and microcirculatory level.<sup>23,24</sup> It has recently been appreciated that, despite improved epicardial coronary artery patency determined by conventional angio-

graphic studies, up to 25% of patients who have had coronary artery reperfusion actually have impairment of their microcirculatory flow (no reflow), which is possibly related to endothelial injury or dysfunction and microembolization.<sup>25</sup> It has also been suggested that reducing the dose of the fibrinolytic agent may lower the risk of intracranial hemorrhage, which continues to attenuate a portion of the survival benefit of fibrinolytic therapy. Recently 2 studies have addressed this subject and provided evidence that combination therapy with abciximab and either reteplase or tenecteplase may reduce the risk of reinfarction and the need for urgent coronary intervention.<sup>26,27</sup> This benefit, however, comes with an increased risk of hemorrhage, especially in patients over the age of 75, in whom it should not be used. The combination of enoxaparin and tenecteplase in the ASSENT 3 study proved to be an attractive alternative to conventional unfractionated heparin and tenecteplase in terms of reduced rates of death, reinfarction and refractory ischemia, and the combination of this efficacy measure plus safety end points of in-hospital major bleeding and intracranial hemorrhage.<sup>27</sup>

Substantial investigation is also underway in the area of myocardial protective agents that could enhance blood flow, reduce myocardial injury and attenuate the inflammatory process associated with the ultimate infarct size that is so pivotal to left ventricular function and survival. These advances coupled with enhanced noninvasive assessment of patients at greatest risk, continued monitoring of the success of pharmacologic reperfusion and triage of appropriate patients who require a more aggressive intervention will undoubtedly further advance the care of these patients.

## Treatment for Mrs. C

Mrs. C's presentation is fairly typical of an acute inferior myocardial infarction. Rarely does it coexist with aortic dissection; however, her history of hypertension and radiation of pain to the back should at least raise this possibility and prompt careful examination of the peripheral pulses and confirmation that the blood pressure is equal in both arms and that there is no evidence of pericarditis or aortic regurgitation.

Although Mrs. C had cardiopulmonary resuscitation in the ambulance, it was brief and was performed without evidence of major fracture or other problems. Therefore, prompt fibrinolysis is appropriate. The territory at risk is modest, with changes only in the inferior ECG leads, and given her age and low body weight, Mrs. C is felt to be at increased risk of intracranial hemorrhage if a fibrin-specific agent is used. Therefore, SK is chosen. An ECG should be obtained again 60–90 minutes after SK administration and, coupled with her clinical response, will be a useful measure of her outcome. If reperfusion is not successful, consideration should be given to urgent and prompt invasive study to examine the advisability of mechanical reperfusion.

Intravenous heparin therapy is not required, but subcu-

taneous heparin therapy started 12–24 hours after the SK therapy may be prudent if a history of deep-vein thrombosis, congestive heart failure and atrial fibrillation is present. Evidence of left ventricular congestion corroborated by portable chest film would suggest the need for a small dose of diuretic given intravenously. Judicious use of small-dose intravenous nitroglycerin therapy could be considered depending on the blood pressure response to the SK therapy. Mrs. C is a candidate for the early administration of ACE inhibitors within the next 12 to 24 hours. Although  $\beta$ -blockers are useful in the secondary prevention of myocardial infarction and recurrent ischemia, her P–R interval of 0.20 seconds suggests that she may be at risk of further atrioventricular block in the setting of her inferior myocardial infarction, and thus caution is advised.

If Mrs. C's clinical progress is satisfactory, low-level exercise testing could be considered, depending on her premonitory status, in order to establish provokable ischemia and the need for invasive study. A noninvasive evaluation of her left ventricular function using 2-dimensional echocardiography would also be reasonable before hospital discharge

*Competing interests:* Dr. Armstrong is a member of the Scientific Advisory Board, Roche Canada. He has received research grants from Boehringer–Ingelheim, Thrombogenics and Eli Lilly, and he has received speaker fees and educational grants from Crystaal Corporation, Roche Canada and Boehringer–Ingelheim.

*Acknowledgement:* It is a pleasure to acknowledge the editorial assistance of Lynne Calder.

## References

- White H, Van de Werf F. Thrombolysis for acute myocardial infarction. *Circulation* 1998;97:1632–46.
- Effectiveness of intravenous thrombolytic treatment in acute myocardial infarction. Gruppo Italiano per lo Studio della Streptochinasi nell'Infarto Miocardico (GISSI). *Lancet* 1986;1:397–401.
- White HD, Cross DB, Williams BF, Norris RM. Safety and efficacy of repeat thrombolytic treatment after acute myocardial infarction. *Br Heart J* 1990; 64:177–81.
- An international randomized trial comparing four thrombolytic strategies for acute myocardial infarction. The GUSTO investigators. *N Engl J Med* 1993; 329:673–82.
- The effects of tissue plasminogen activator, streptokinase, or both on coronary-artery patency, ventricular function, and survival after acute myocardial infarction. The GUSTO Angiographic Investigators. *N Engl J Med* 1993; 329:1615–22.
- A comparison of reteplase with alteplase for acute myocardial infarction. The Global Use of Strategies to Open Occluded Coronary Arteries (GUSTO III) Investigators. *N Engl J Med* 1997;337:1118–23.
- Single-bolus tenecteplase compared with front-loaded alteplase in acute myocardial infarction: the ASSENT-2 double-blind randomised trial. Assessment of the Safety and Efficacy of a New Thrombolytic Investigators. *Lancet* 1999;354:716–22.
- Indications for fibrinolytic therapy in suspected acute myocardial infarction: collaborative overview of early mortality and major morbidity results from all randomised trials of more than 1000 patients. Fibrinolytic Therapy Trialists' (FTT) Collaborative Group. *Lancet* 1994;343:311–22.
- Thiemann DR, Coresh J, Schulman SP, Gerstenblith G, Oetgen WJ, Powe NR. Lack of benefit for intravenous thrombolysis in patients with myocardial infarction who are older than 75 years. *Circulation* 2000;101:2239–46.
- White HD. Thrombolytic therapy in the elderly [editorial]. *Lancet* 2000; 356:2028–30.
- Barbash GI, Hod H, Roth A, Faibel HE, Mandel Y, Miller HI, et al. Repeat infusion of recombinant tissue-type plasminogen activator in patients with acute myocardial infarction and early recurrent myocardial ischemia. *J Am Coll Cardiol* 1990;16:779–83.
- Gibson CM. Primary angioplasty compared with thrombolysis: new issues in the era of glycoprotein IIb/IIIa inhibition and intracoronary stenting. *Ann Intern Med* 1999;130:841–7.
- Schömig A, Kastrati A, Dirschinger J, Mehilli J, Schricke U, Pache J, et al. Coronary stenting plus platelet glycoprotein IIb/IIIa blockade compared with tissue plasminogen activator in acute myocardial infarction. Stent versus Thrombolysis for Occluded Coronary Arteries in Patients with Acute Myocardial Infarction Study Investigators. *N Engl J Med* 2000;343:385–91.
- Danchin N, Vaur L, Genes N, Étienne S, Angioi M, Ferrieres J, et al. Treatment of acute myocardial infarction by primary coronary angioplasty or intravenous thrombolysis in the "real world". *Circulation* 1999;99:2639–44.
- Luepker RV, Raczynski JM, Osganian S, Goldberg RJ, Finnegan JR Jr, Hedges JR, et al. Effect of a community intervention on patient delay and emergency medical service use in acute coronary heart disease: The Rapid Early Action for Coronary Treatment (REACT) Trial. *JAMA* 2000;284:60–7.
- Acute myocardial infarction: pre-hospital and in-hospital management. The Task Force on the Management of Acute Myocardial Infarction of the European Society of Cardiology. *Eur Heart J* 1996;17:43–63.
- Aufderheide TP, Rowlandson I, Lawrence SW, Kuhn EM, Selker HP. Test of the acute cardiac ischemia time-insensitive predictive instrument (ACI-TIPI) for prehospital use. *Ann Emerg Med* 1996;27(2):193–8.
- Mehta SR, Eikelboom JW, Yusuf S. Risk of intracranial hemorrhage with bolus versus infusion thrombolytic therapy: a meta-analysis. *Lancet* 2000;356: 449–54.
- Armstrong PW, Granger C, Van de Werf F. Bolus fibrinolysis: risk, benefit, and opportunities. *Circulation* 2001;103:1171–3.
- Ryan TJ, Antman EM, Brooks NH, Califf RM, Hillis LD, Hiratzka LF, et al. 1999 update: ACC/AHA Guidelines for the Management of Patients With Acute Myocardial Infarction: Executive Summary and Recommendations: A report of the American College of Cardiology/American Heart Association Task Force on Practice Guidelines (Committee on Management of Acute Myocardial Infarction). *Circulation* 1999;100:1016–30.
- Coller BS. Platelets and thrombolytic therapy. *N Engl J Med* 1990;322:33–42.
- Randomised trial of intravenous streptokinase, oral aspirin, both, or neither among 17,187 cases of suspected acute myocardial infarction: ISIS-2 (Second International Study of Infarct Survival) Collaborative Group. *Lancet* 1988;2:349–60.
- Antman EM, Giugliano RP, Gibson CM, McCabe CH, Coussement P, Kleiman NS, et al. Abciximab facilitates the rate and extent of thrombolysis: results of the thrombolysis in myocardial infarction (TIMI) 14 trial. The TIMI 14 Investigators. *Circulation* 1999;99:2720–32.
- Trial of abciximab with and without low-dose reteplase for acute myocardial infarction. Strategies for Patency Enhancement in the Emergency Department (SPEED) Group. *Circulation* 2000;101:2788–94.
- Ito H, Okamura A, Iwakura K, Masuyama T, Hori M, Takiuchi S, et al. Myocardial perfusion patterns related to thrombolysis in myocardial infarction perfusion grades after coronary angioplasty in patients with acute anterior wall myocardial infarction. *Circulation* 1996;93:1993–9.
- Topol EJ. Reperfusion therapy for acute myocardial infarction with fibrinolytic therapy or combination reduced fibrinolytic therapy and platelet glycoprotein IIb/IIIa inhibition: the GUSTO V randomised trial. *Lancet* 2001; 357:1905–14.
- ASSENT 3 Investigators. Efficacy and safety of tenecteplase in combination with enoxaparin, abciximab or unfractionated heparin: the ASSENT 3 randomised trial in acute myocardial infarction. *Lancet* 2001;358:605–13.

**Correspondence to:** Dr. Paul W. Armstrong, 2-51 Medical Sciences Building, University of Alberta, Edmonton AB T6G 2H7; paul.armstrong@ualberta.ca

### Articles to date in this series

Armstrong PW. New advances in the management of acute coronary syndromes [editorial]. *CMAJ* 2001;164(9): 1303–4.

Fitchett D, Goodman S, Langer A. New advances in the management of acute coronary syndromes: 1. Matching treatment to risk. *CMAJ* 2001;164(9):1309–16.

A patient information sheet appears on the next page.

## Appendix 1

# Questions and answers on fibrinolytic (clot-dissolving) therapy for acute myocardial infarction (heart attack)

## An information sheet for patients

### What is acute myocardial infarction?

An acute myocardial infarction, or acute MI, is commonly called a heart attack. A heart attack occurs when an artery supplying the heart muscle with blood and oxygen becomes blocked with one or more clots. When the heart is deprived of oxygen because of this blockage, heart muscle cells begin to die (see figure).

### How is myocardial infarction treated?

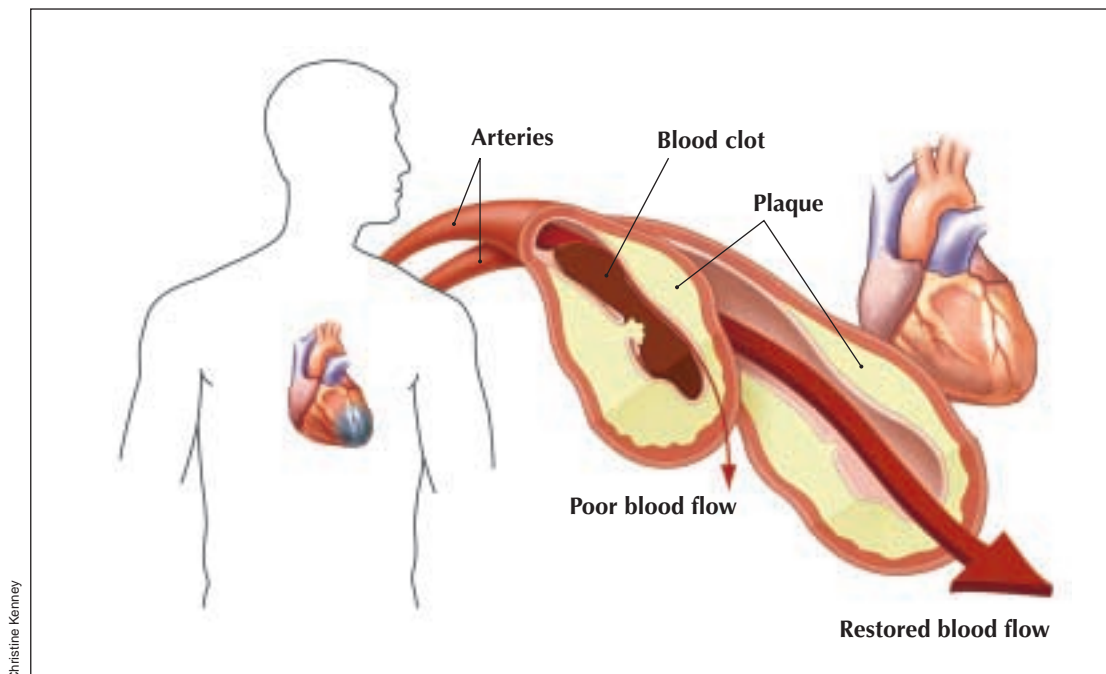
Myocardial infarction must be treated as quickly as possible to minimize damage to the heart and to preserve the heart's pumping function. The most important part of treatment involves restoring the flow of blood in the affected area. This is called *reperfusion*. Reperfusion can be achieved using tubes and other devices, or by giving clot-dissolving medications. These medications are referred to as *thrombolytic agents* because they work to dissolve the clot, or *thrombus*. Acetylsalicylic acid (ASA), often even in small doses, is also used, together with other therapies, to improve blood flow to the heart.

### What is fibrinolytic therapy?

Fibrinolytic therapy involves the use of drugs that dissolve clots by breaking down *fibrin* — a protein that connects with another sticky element of the blood known as *platelets* to form clots. The aim of the therapy is to achieve quick, effective and long-lasting return of blood flow by a process known as *fibrinolysis*, or "clot busting." One of the most commonly used fibrinolytic drugs is streptokinase. Two other fibrinolytic drugs in common use are recombinant tissue plasminogen activator (rtPA) and reteplase, a derivative of rtPA; these drugs are given with another anti-clotting drug called heparin. Another fibrinolytic drug soon to be released in Canada is tenecteplase; this is another derivative of rtPA and must also be given with heparin.

### Will my doctor offer me this therapy?

Your doctor will decide whether to offer fibrinolytic therapy to you after promptly considering a number of factors. For example, your doctor will want to determine whether you are at in-



In the left portion of the figure, blood flow to the heart muscle is blocked by a clot, whose formation was stimulated by a rupture in the lining of the blood vessel wall. When the heart is deprived of oxygen, heart muscle cells begin to die (blue section of the heart). On the right side of the figure, normal blood flow is restored (reperfusion) after effective treatment.

creased risk of stroke or bleeding and whether you have had recent major surgery. You are less likely to be offered this therapy if you are pregnant or have uncontrolled high blood pressure. You are most likely to be offered this therapy if you are free of these and other complicating conditions and arrive at the hospital soon after your symptoms begin. In addition, you are likely to be considered a suitable candidate for therapy if your electrocardiogram (ECG) — the graphic record of your heart's electrical activity — shows *ST-segment elevation*. This ECG change indicates that a heart attack is occurring as the result of a clot in a major heart artery.

### When am I likely to begin fibrinolytic therapy?

You can benefit from this therapy up to 12 hours after your symptoms begin. However, the sooner the therapy is started, the more likely you are to benefit from it. The greatest benefit appears to occur when fibrinolytic drugs are given in the first hour after symptoms appear. (It may soon be possible for paramedics to transmit information about a patient's condition and communicate with medical specialists so that therapy can begin before the patient reaches hospital.)

### Are there risks associated with fibrinolytic therapy?

Yes. Like many therapies, fibrinolytic therapy can lead to complications in some patients. The most common problem is bleeding. You and your doctor will need to discuss your med-


ical history and weigh the potential benefits against the risks of using fibrinolytic drugs.

### What if I can't take fibrinolytic drugs or if the drugs don't work?

If you can't take fibrinolytic drugs because of the risk of complications or if you take the drugs and they don't work, an effective alternative treatment is called *percutaneous transluminal coronary angioplasty*, or "balloon angioplasty." With angioplasty, a hollow, flexible tube called a *catheter* is inserted into an artery in the groin and is moved up to the blocked heart artery. A balloon at the end of the catheter is then inflated to flatten the clot against the artery wall. Often a wire mesh device called a *stent* is then inserted to keep the unclogged artery open. Often used in addition to stents are new drugs called *glycoprotein IIb/IIIa platelet inhibitors*, which are injected into the blood to reduce the stickiness of platelets.

### How might fibrinolytic therapy change in future?

Findings from recent studies could change the way fibrinolytic drugs are used. Researchers believe that reducing the amount of clot-dissolving drug or combining a clot-dissolving drug with glycoprotein IIb/IIIa platelet inhibitors or other agents may eliminate some of the complications associated with fibrinolytic therapy. This combination of medications may also prove to be more effective than using either drug alone.



ASSOCIATION  
MÉDICALE  
CANADIENNE



CANADIAN  
MEDICAL  
ASSOCIATION

2500 volunteer reviewers from across North America are the foundation for CMAJ's thorough, criterion-based review process. The editorial staff includes scientific consultants with expertise in statistics, experimental design and epidemiology.

#### CMA Member Service Centre

tel 888 855-2555 or 613 731-8610 x2307

fax 613 236-8864

cmamsc@cma.ca

www.cma.ca/cmaj