Radiation techniques for the 21st century

Brenda G. Clark, PhD; Michael R. McKenzie, MD

Technology: Precision radiotherapy

History: Precision radiotherapy has existed since the 1950s in the form of stereotactic radiosurgery (SRS), which is the accurate delivery of a single fraction of radiation to stereotactically defined intracranial targets. In the 1990s it became possible to administer stereotactic radiotherapy (SRT) over several weeks, an approach typical of conventional radiotherapy, and thus improve tumour control and reduce the risk of late side effects through fractionation.[1] However, existing stereotactic technologies have not allowed treatment of lesions below the base of the skull. With photons, which are in widespread use, it has been difficult to deliver stereotactic radiation to lesions greater than 40 mm in diameter and to irregularly shaped lesions adjacent to critical normal structures such as the brain stem. Although protons are useful in such situations, the high cost of cyclotrons required to produce them limit their availability.

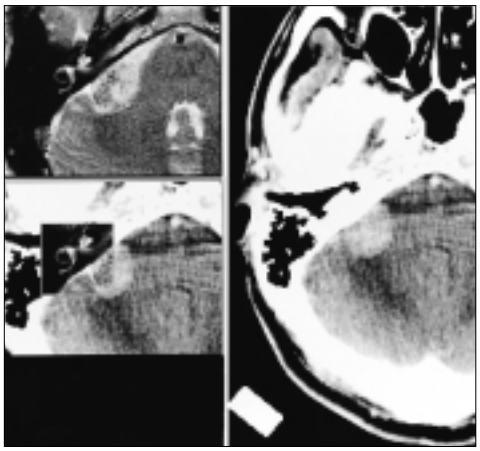

Fused 3-dimensional CT and MRI image data sets used for stereotactic radiosurgery. An acoustic neuroma is clearly visible in the axial MRI scan (top left). This target may be delineated in either the MRI scan or the corresponding CT image (right). At bottom left, a square of the MRI scan can be moved across the underlying CT image to identify the precise location of the tumour in each axial slice.

Use: The recent development of techniques to manipulate images and to shape small radiation fields has dramatically increased the complexity of radiotherapy. SRT of small intracranial lesions, once available in only a few centres worldwide, is now widely available, due in part to a concurrent dramatic rise in the functionality of treatment planning systems. Ten years ago a stereotactic treatment was commonly planned using axial CT images alone. Today 2 or 3 imaging modalities may be used, including MRI, angiography and CT, with the data sets for each accurately superimposed in 3 dimensions to optimize visualization of the lesion (Figure). Ten years ago radiation fields were circular, resulting in a spherical dose distribution. Today these fields may be shaped with a miniature multileaf collimator to spare normal tissue.[2] To extend the technique outside the cranium, various options are being developed. One such system uses planar infrared and video imaging registered with 3-dimensional CT, MRI and ultrasound images.

Promise: SRS is effective in selected cases of arteriovenous malformation, acoustic neuroma, brain metastasis and other intracranial lesions. Although less extensive than that with SRS, experience with SRT suggests that it, too, will find a role in intracranial treatment. The new technologies now becoming available should improve outcome for both SRS and SRT. For extracranial sites, the improved accuracy of localization and treatment delivery associated with precision radiotherapy are likely to improve tumour control and reduce late complications at conventional radiation doses. The escalation of radiation dose will also be possible, which may further improve tumour control when a radiation dose–response relationship exists.[3]

Problems: Much work remains in resolving a number of issues related to the planning of complex field shapes, including the presence of small lesion protuberances and adjacent air cavities, and the need to develop technology to perform 3-dimensional dose measurements. The modalities involved in precision radiotherapy must undergo careful clinical study to determine their role in cancer treatment.

Prospects: Over the next decade several Canadian cancer centres will probably implement these techniques, although significant challenges remain with respect to resource requirements. The costs of commercial systems are high, as are the costs of medical physics support because of the time involved in commissioning these systems, quality assurance and treatment planning. Many Canadian cancer centres have limited access to MRI, a frequently vital component of treatment planning. Precision radiotherapy requires more treatment unit time per case, an important factor in centres where waiting lists for radiotherapy pose problems.

Competing interests: None declared.

References

1. McKenzie MR, Souhami L, Caron JL, Olivier A, Villemure JG, Podgorsak EB. Early and late complications following dynamic stereotactic radiosurgery and fractionated stereotactic radiotherapy. *Can J Neurol Sci* 1993;20(4):279-85.
2. Cosgrove VP, Jahn U, Pfaender M, Bauer S, Budach V, Wurm RE. Commissioning of a micro multi-leaf collimator and planning system for stereotactic radiosurgery. *Radiother Oncol* 1999;50(3):325-36.
3. Suit H. Assessment of the impact of local control on clinical outcome. *Front Radiat Ther Oncol* 1996;29:17-23.

The authors are from the Radiation Therapy Program, British Columbia Cancer Agency, Vancouver Cancer Centre, Vancouver, BC.