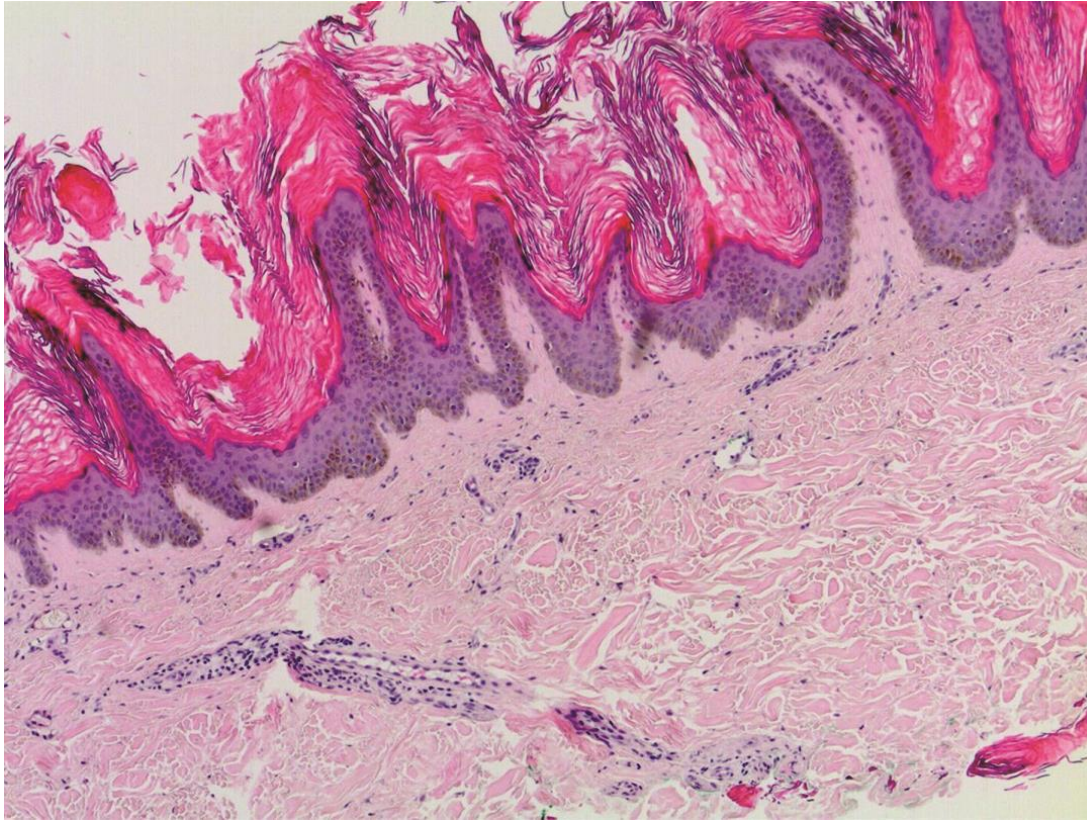


Appendix 1



Biopsy of a 69-year-old man showing marked compact hyperkeratosis, acanthosis and papillomatosis in the epidermis.