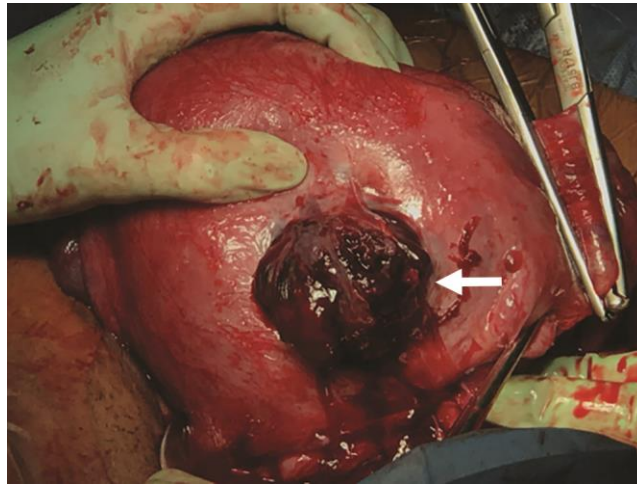


## Appendix 1



Uterus of a 37-year-old woman with the placenta invading through the anterior wall at the site of the previous classical cesarean delivery (arrow). The fetus had already been delivered through a standard lower segment incision, which was closed for hemostasis before the hysterectomy.