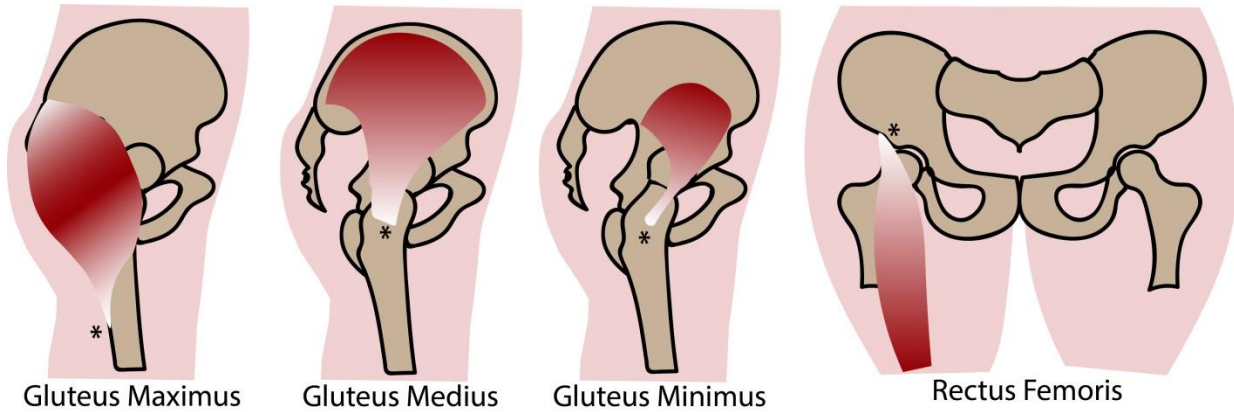


Appendix 1: Locations of calcific tendinitis of the muscles in the hip



Locations of calcific tendinitis (asterisks) of the muscles in the hip. Gluteus maximus inserts into the posterior aspect of the proximal femur. Gluteus medius and gluteus minimus insert onto the greater trochanter. The reflected tendon of rectus femoris originates from a groove above the rim of the acetabulum.