

CLINICAL IMAGES

Amyloid imaging in atypical dementia

Robert Laforce Jr MD PhD, Gil D. Rabinovici MD

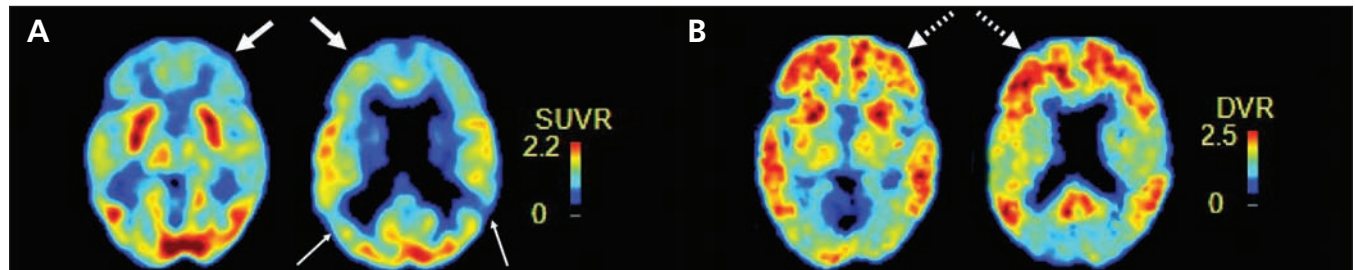


Figure 1: (A) Fluorine-18 deoxyglucose positron emission tomography (PET) of the brain of a 55-year-old man with dementia, showing bilateral frontal (thick arrows) and temporoparietal (thin arrows) hypometabolism, equivocal for Alzheimer disease or frontotemporal dementia. (B) Carbon 11-labelled Pittsburgh compound B PET showing diffuse amyloid binding (dashed arrows) compatible with Alzheimer pathology. DVR = distribution volume ratio, SUVR = standardized uptake value ratio.

A 55-year-old man presented with a nine-year history of profound behavioural changes, including socially inappropriate behaviour, disinhibition and impairment in executive skills. His score on the Mini-Mental State Examination was 16/30. A dementia work-up, including magnetic resonance imaging of the brain, was unremarkable. He was diagnosed clinically with the behavioural variant of frontotemporal dementia, a condition characterized by early behavioural changes and executive deficits with relative sparing of memory. However, deterioration in memory and visuospatial performances over time raised the possibility of a missed diagnosis of Alzheimer disease, which was supported by further investigations, including amyloid imaging (Figure 1). Following initiation of a cholinesterase inhibitor, the patient remained behaviourally and cognitively stable.

The differential diagnosis of dementia can prove complex, particularly in younger patients. In the past decade, Pittsburgh compound B positron emission tomography (PiB-PET) has enabled the in vivo detection of amyloid plaques, a core pathologic feature of Alzheimer disease. Although the short half-life of the carbon 11 radiolabel has thus far limited the use of PiB to research, a second generation of tracers labelled with fluorine-18 has recently made clinical use of amyloid PET possible. Studies indicate that PiB-PET is sensitive for Alzheimer disease pathology, can distinguish Alzheimer disease from other types of dementia and can help determine whether mild cognitive impairment is due to Alzheimer disease.¹

Fluorine-18 deoxyglucose (FDG) PET can aid in diagnosing complex or atypical cases,² but amyloid imaging has proven superior in differentiating Alzheimer disease from frontotemporal dementia, as in this patient. Moreover, among patients with known histopathology, classification accuracy is 97% for PiB-PET and 87% for FDG-PET.³ Amyloid imaging may help reduce misdiagnosis and promote earlier and more effective treatment. In 2012, fluorine-18 florbetapir became the first tracer approved by the US Food and Drug Administration for amyloid imaging. This has come with recommendations on uses of this technology that are appropriate (e.g., complex or atypical presentations in tertiary care memory clinics) and inappropriate (e.g., initial investigation of cognitive complaints).^{4,5} Future research should focus on diagnostic utility, and patient-centred and cost-effectiveness outcomes.

References

1. Rowe CC, Ellis KA, Rimajova M, et al. Amyloid imaging results from the Australian Imaging, Biomarkers and Lifestyle (AIBL) study of aging. *Neurobiol Aging* 2010;31:1275-83.
2. Laforce RJr, Buteau JP, Paquet N, et al. The value of PET in mild cognitive impairment, typical and atypical/unclear dementias: a retrospective memory clinic study. *Am J Alzheimers Dis Other Dement* 2010;25:324-32.
3. Rabinovici GD, Rosen HJ, Alkalay A, et al. Amyloid vs. FDG-PET in the differential diagnosis of AD and FTL. *Neurology* 2011;77:2034-42.
4. Johnson KA, Minoshima S, Bohnen NI, et al. Appropriate use criteria for amyloid PET: a report of the Amyloid Imaging Task Force, the Society of Nuclear Medicine and Molecular Imaging, and the Alzheimer's Association. *Alzheimers Dement* 2013;9:e1-16.
5. Booi J, Arbizu J, Darcourt J, et al. Appropriate use criteria for amyloid PET imaging cannot replace guidelines: on behalf of the European Association of Nuclear Medicine. *Eur J Nucl Med Mol Imaging* 2013;40:1122-5.

Competing interests: None declared.

This article has been peer reviewed.

The authors have obtained patient consent.

Correspondence to: Robert Laforce Jr, robert.laforce@fmed.ulaval.ca

Affiliations: Clinique Interdisciplinaire de Mémoire, Département des sciences neurologiques, Centre Hospitalier Universitaire de Québec; and Faculté de médecine, Université Laval, Laval, Que. (Laforce); UCSF Memory and Aging Center, Department of Neurology, (Rabinovici), University of California, San Francisco, Calif.

CMAJ 2014; DOI:10.1503/cmaj.131158