

a first-year radiology resident would not make this mistake!

John A. Clark MDCM
Radiologist
Rouge Valley Health System
Toronto, Ont.

REFERENCE

1. Weir E, Cohen M. A 48-year-old woman with lymphangioleiomyomatosis. *CMAJ* 2007;176:1271-2.

DOI:10.1503/cmaj.1070060

[The authors respond:]

We thank John Clark and other readers for drawing our attention to the error.¹ The correct image is provided here with the original caption.

Erica Weir MD MSc
Associate Medical Officer of Health,
York Region, Ont.
Marsha Cohen MD MHSc
Women's Health Research Institute
Women's College Hospital
Toronto, Ont.

REFERENCE

1. Weir E, Cohen M. A 48-year-old woman with lymphangioleiomyomatosis. *CMAJ* 2007;176:1271-2.

DOI:10.1503/cmaj.1070072

Apology

A recent news story on the HPV vaccine¹ was illustrated with a photograph of 2 young girls. In fact, that photo was taken by the Canadian Press for an article on juvenile arthritis, and, in accordance with the terms of *CMAJ*'s contract with Canadian Press, we were not authorized to use it for other purposes. We apologize to the children and their parents for this error and regret any inconvenience it may have caused.

REFERENCE

1. Comeau P. Debate begins over public funding for HPV vaccine. *CMAJ* 2007;176(7):913-4.

DOI:10.1503/cmaj.070747

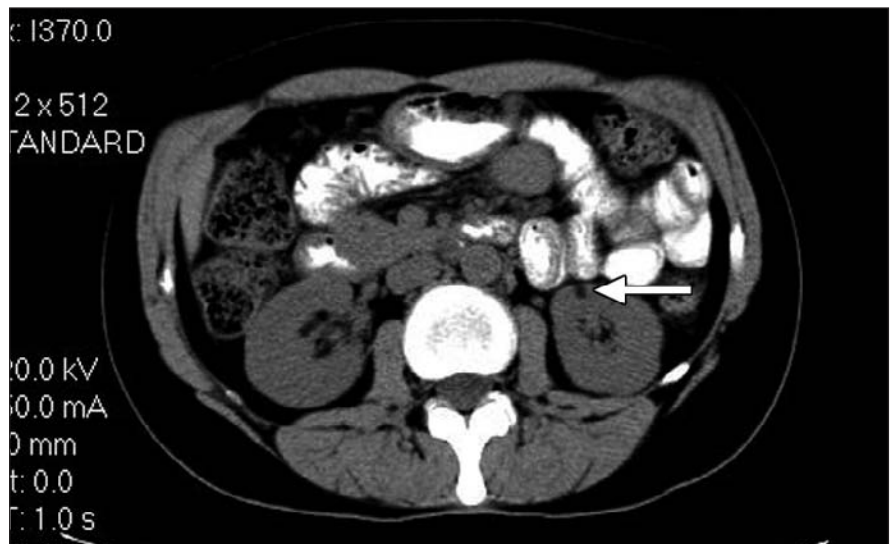


Fig. 2: CT scan of the abdomen showing renal angioliipoma (arrow).

As a CMA member,
you can enjoy free,
online clinical resources
on cma.ca!

Exclusive access to convenient,
comprehensive clinical tools
—24 hours a day, 7 days a week—
wherever and whenever you need them.

Watch for our
Clinical Resources Quick Guide
to be circulated with the July 17 issue
of *CMAJ*.

Made possible through an unrestricted education grant
from Merck Frosst www.univadis.ca