

# Defusing the intra-abdominal ticking bomb: intestinal malrotation in children

Ihab M. Kamal

## The case

A 6-month-old girl presents to her pediatrician with lethargy; she has been vomiting and the vomit is bile stained. She is admitted to hospital for tests. Plain radiographs of the abdomen and barium enema examination are normal. Results of an upper gastrointestinal (GI) study are suspicious for, but not diagnostic of, intestinal malrotation. The patient improves quickly and is discharged the following day. Over the next 2 months she continues to have similar short-lived episodes lasting a few hours, for which she is seen in the emergency department by on-call physicians. Her pediatrician initiates investigations to rule out an endocrine cause of the vomiting, when she has to be readmitted to hospital because of a severe episode. On this occasion, the girl's condition rapidly deteriorates and, despite active resuscitation during a barium enema examination to rule out intussusception, she dies. Post-mortem examination shows midgut infarction due to malrotation-associated volvulus with peritonitis.

## Definition

Intestinal malrotation is the term given to errors of rotation of the midgut around the superior mesenteric artery and the midgut's subsequent fixation in the peritoneal cavity. (See Fig. 1 for stages in normal intestinal rotation.) Many embryonic variants of the anomaly exist, ranging from nonrotation to reversed rotation.<sup>1-5</sup> In the most common type encountered in children, malrotation, the process of rotation is incomplete and the attachment of the mesentery of the midgut to the posterior abdominal wall is narrow and predisposes the midgut to volvulus (Fig. 2). Unless diagnosed promptly this condition can result in death or the short-bowel syndrome.

## Epidemiology

Nonrotation occurs in approximately 1 in 500 live births.<sup>6</sup> The true incidence of malrotation is unknown, however.<sup>5,7</sup> Either sex can be affected with the anomaly. Approximately 60% of cases present in the first month of life, about 20% of cases between 1 month and 1 year of age, and the remainder present after the first year of life. Thereafter, the anomaly continues to manifest itself throughout childhood with decreasing frequency; it can occur in adults and even in the elderly.<sup>8,9</sup>

Malrotation is an integral part of other major anomalies that do not allow for the return of the midgut to the peritoneal cavity (e.g., gastroschisis, omphaloceles and congenital diaphragmatic hernia)<sup>10</sup> and is frequently associated with other congenital and acquired lesions of the gastrointestinal tract including Hirschsprung's disease, intussusception and atresia of the jejunum, duodenum and esophagus.<sup>6,11-13</sup>

## Clinical features

Neonates with intestinal malrotation present with bilious (green) vomiting caused by duodenal obstruction by congenital bands or midgut volvulus.<sup>14,15</sup> Beyond the neonatal period, however, the clinical presentation of malrotation is variable and not as well defined.<sup>7,14-16</sup> Symptoms that may be encountered in children after 1 month of age are listed in Table 1. Unfortunately, a physical examination is often

## Review

## Synthèse

Dr. Kamal is Associate Professor of Surgery and Pediatrics, Department of Surgery, Queen's University, Kingston, Ont.

*This article has been peer reviewed.*

CMAJ 2000;162(9):1315-7

## Key points

- Volvulus due to malrotation should always be kept in mind when assessing a child with abdominal pain and vomiting, particularly if the vomit is green. It cannot be ruled out on the basis of a negative abdominal examination or normal plain radiographs.
- Midgut volvulus may be present with chronic or intermittent symptoms.
- The best aids in making the diagnosis of malrotation are a careful and detailed history and an awareness of the anomaly.
- An upper GI study is very accurate in confirming the diagnosis.
- All children diagnosed with malrotation should be referred for a pediatric surgery consultation.

unrewarding until late in the disease process when abdominal distention and other signs of peritonitis develop with the onset of ischemic necrosis of the volvulated bowel.<sup>17</sup>

## Diagnosis

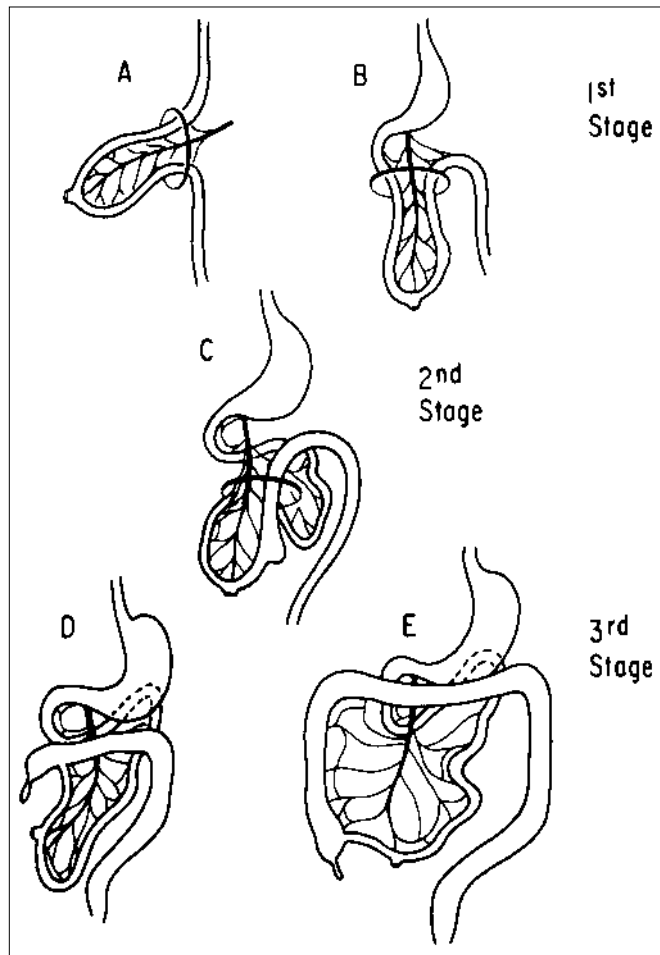
The upper GI study is key and very accurate for the diagnosis of intestinal malrotation.<sup>18,19</sup> The landmark in the upper GI series is the position of the duodenojejunal flexure, and various radiographic patterns of duodenal malrotation have been described in detail to aid physicians in their diagnoses.<sup>19</sup> Plain films of the abdomen, barium enema, abdominal ultrasound and CT scans are often not sufficiently reliable to rule out the diagnosis.<sup>7,11,20-24</sup> Rarely, laparotomy or laparoscopy may be required to make the diagnosis.<sup>7,25,26</sup>

## Management

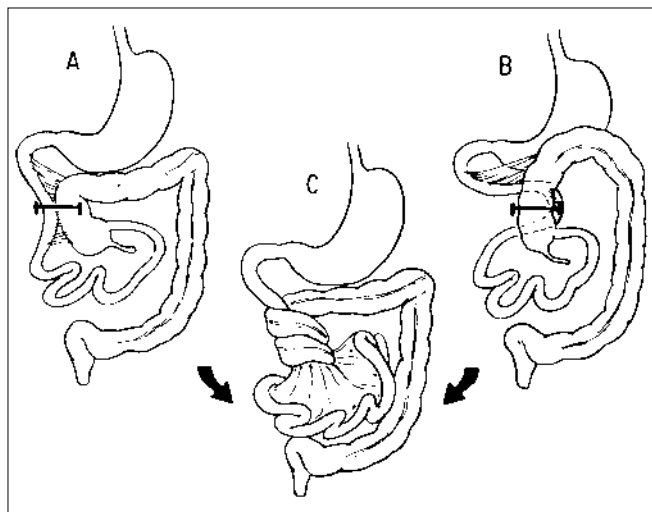
Patients who, on physical examination, present with a "surgical" abdomen and in whom the diagnosis of malrotation is suspected should be referred for immediate Ladd's

procedure surgery.<sup>27</sup> This consists of derotation of the midgut if volvulus exists and the division of the adhesions obstructing the duodenum and those that bind down and narrow the mesentery of the midgut. Gangrenous bowel, if encountered, is resected. The small bowel is placed in the right side of the abdomen and the colon in the left side. Appendectomy completes the procedure. If, however, the diagnosis is suspected on the basis of the patient's history and the physical examination is unremarkable, an upper GI study specifically designed to rule out malrotation should be arranged; if positive, urgent surgery should be planned. It is in these patients that the ticking bomb should be defused.

Thanks to Margaret Darling, Librarian, and Victoria Lemon, Library Technician, Kingston General Hospital, Kingston, Ont., for their valuable help.



**Fig. 1:** Stages in normal intestinal rotation. A, gestational age 6 weeks; B, 8 weeks; C, 9 weeks; D, 11 weeks and E, 12 weeks (from Filston and Kirks,<sup>11</sup> with permission).



**Fig. 2:** Pathophysiology of midgut volvulus with malrotation. A narrow mesenteric attachment may cause midgut volvulus (from Filston and Kirks,<sup>11</sup> with permission).

**Table 1: Possible presentations of malrotation beyond the neonatal period**

- Vomiting (acute or chronic) usually, but not necessarily, bile stained (green)
- Abdominal pain, usually severe, may be acute, recurrent or chronic with or without vomiting
- Chronic diarrhea
- Constipation
- Anorexia or nausea
- Irritability or lethargy
- Bloody stools
- Hematemesis
- Failure to thrive
- Symptoms suggestive of milk allergy, malabsorption or celiac disease
- Symptoms suggestive of "psychogenic abdominal pain" or "cyclic vomiting of childhood"

Competing interests: None declared.

## References

1. Frazer JF, Robbins RH. On the factors concerned in causing intestinal rotation in man. *J Anat Physiol* 1915;51:75-110.
2. Snyder WH Jr, Chaffin L. Embryology and pathology of the intestinal tract: presentation of 40 cases of malrotation. *Ann Surg* 1954;140:368-80.
3. Lister J. Malrotation and volvulus of the intestine. In: Lister J, Irving IM, editors. *Neonatal surgery*. 3rd ed. London: Butterworth; 1990. p. 442-5.
4. Touloukian RJ, Smith EI. Disorders of rotation and fixation. In: O'Neill JA, editor. *Pediatric surgery*. vol 2. 5th ed. Baltimore: Mosby; 1998. p. 1199-203.
5. Skandalakis JE, Gray SW, Ricketts R, Richardson DD. The small intestine. In: Skandalakis JE, Gray SW, editors. *Embryology for surgeons*. 2nd ed. Baltimore: Williams & Wilkins; 1994. p. 184-200.
6. Steward DR, Colodny AL, Daggett WC. Malrotation of the bowel in infants and children: a 15 year review. *Surgery* 1976;79:716-20.
7. Yanez R, Spitz L. Intestinal malrotation presenting outside the neonatal period. *Arch Dis Child* 1986;61:682-5.
8. Wang C, Welch CE. Anomalies of intestinal rotation in adults. *Surgery* 1963; 54:839-55.
9. Von Flüe M, Herzog U, Ackermann C, Tondelli P, Harder F. Acute and chronic presentation of intestinal nonrotation in adults. *Dis Colon Rectum* 1994;37:192-8.
10. Buyse ML, editor. *Birth defect encyclopedia*. Dover (MA): Center for Birth Defects Information/Blackwell Scientific/Yearbook Medical Pubs.; 1990. p. 987.
11. Filston HC, Kirks DR. Malrotation—the ubiquitous anomaly. *J Pediatr Surg* 1981;16(4 Suppl 1):614-20.
12. Kiesewetter WB, Smith JW. Malrotation of the midgut in infancy and childhood. *Arch Surg* 1958;77:483-91.
13. Brereton RJ, Taylor B, Hall CM. Intussusception and intestinal malrotation in infants: Waugh's syndrome. *Br J Surg* 1986;73:55-7.
14. Brandt ML, Pokorny WJ, McGill CW, Harberg FJ. Late presentation of midgut malrotation in children. *Am J Surg* 1985;150:767-71.
15. Sprigland N, Brandt ML, Yazbeck S. Malrotation presenting beyond the neonatal period. *J Pediatr Surg* 1990;25:1139-42.
16. El-Gohari MA, Cook RCM. Intestinal malrotation beyond the neonatal period. *Z Kinderchir* 1984;39:237-41.
17. Bonadio WA, Clarkson T, Naus J. The clinical features of children with malrotation of the intestine. *Pediatr Emerg Care* 1991;7:348-9.
18. Seashore JH, Touloukian RJ. Midgut volvulus. An ever-present threat. *Arch Pediatr Adolesc Med* 1994;148:43-6.
19. Long FR, Kramer SS, Markowitz RI, Taylor GE. Radiographic patterns of malrotation in children. *Radiographics* 1996;16:547-56.
20. Millar AJW, Rode H, Brown RA, Cywes S. The deadly vomit: malrotation and midgut volvulus. *Pediatr Surg Int* 1987;2:172-6.
21. Powell DM, Othersen HB, Smith CD. Malrotation of the intestines in children: the effect of age on presentation and therapy. *J Pediatr Surg* 1989;24: 777-80.
22. Simpson AJ, Leonidas JC, Krasna IH, Becker JM, Schneider KM. Roentgen diagnosis of midgut malrotation: value of upper gastrointestinal radiographic study. *J Pediatr Surg* 1972;7:243-52.
23. Zerin JM, DiPietro M. Superior mesenteric vascular anatomy at US in patients with surgically proved malrotation of the midgut. *Radiology* 1992;183: 693-4.
24. Zerin JM, DiPietro M. Mesenteric vascular anatomy at CT: Normal and abnormal appearances. *Radiology* 1991;179:739-42.
25. Waldhausen JH, Sawin RS. Laparoscopic Ladd's procedure and assessment of malrotation. *J Laparoendosc Surg* 1996;6(Suppl 1):S103-5.
26. Gross E, Chen MK, Lobe TE. Laparoscopic evaluation and treatment of intestinal malrotation in infants. *Surg Endosc* 1996;10(9):936-7.
27. Ladd WE. Surgical diseases of the alimentary tract in infants. *N Engl J Med* 1936;215:705-8.

**Reprint requests to:** Dr. Ihab M. Kamal, Department of Surgery, Kingston General Hospital, 76 Stuart St., Kingston ON K7L 2V7; fax 613 545-3203; [IMK@queensu.ca](mailto:IMK@queensu.ca)

