



Stent-graft repair for abdominal aortic aneurysm

Peter G. Kalman, MD

Technology: Endovascular abdominal aortic aneurysm repair
Use: The tremendous enthusiasm within the international vascular community for endovascular aneurysm repair is evidenced by widespread clinical investigations and numerous reports in the literature.¹⁻⁵ The device used for the procedure consists of a balloon-expandable metal stent covered with a dacron graft. The stent is introduced through the femoral artery within a delivery system and is passed up the iliac artery into the aorta. It is then deployed and fixed in position within the aneurysm by balloon expansion of the stent, thus excluding the abdominal aortic aneurysm from circulation.

History: Endovascular grafting of abdominal aneurysms, first reported clinically in 1991,¹ has evolved from simple tubular endografts to more complex bifurcated designs. Prerequisite requirements for the device included a small, flexible delivery system to allow retrograde insertion through the femoral artery, secure attachment to normal arterial walls and a strong and durable fabric. There have been gradual improvements in the delivery systems, grafts and device attachment systems (stents), and progress has been made in solving technical problems. In addition to being used for abdominal aortic aneurysm repair, stent grafts have been used to repair isolated iliac aneurysms, thoracic aneurysms and traumatic arterial injuries.

The safety, efficacy and utility of this technology are in various stages of clinical testing around the world. The EUROSTAR registry comprises 38 European institutions that are collaborating in a multicentre registry to conduct short- to medium-term follow-up on 899 patients who underwent abdominal aortic aneurysm stent-graft repair between May 1994 and March 1998.⁵ The freedom from a persistent endoleak 6 and 18 months postoperatively was 93% and 90%, respectively.

Promise: Endovascular grafting has largely been driven by the desire to reduce the morbidity and mortality associated with open-surgical repair. It is minimally invasive and can be performed with local anesthesia plus sedation.² This has had an impact on patient acceptance and hospital resources.³

Problems: Endovascular aneurysm repair has been found to be technically not feasible in 40% to 80% of cases.³ Reasons for this include an inadequate proximal aneurysm neck for secure attachment of the endograft, aneurysm proximity to the renal arteries with risk of occlusion after graft deployment, excessive

tortuosity or angulation of the aorta and an inability to pass the delivery system through narrowed or occluded iliac arteries.

A recent report summarizing the outcome of 303 patients who had endoluminal abdominal aortic aneurysm repair found no significant difference in perioperative mortality between operative and endovascular groups.³ This study suggests that endografting is safe; the cumulative 3-year graft success was estimated to be 70%. However, the rate of graft failure (loss of graft function, a graft endoleak or conversion to open repair) was significantly higher in the endovascular group.

One of the challenges facing vascular surgeons and interventional radiologists is to resolve the "turf" battles over this emerging technology. This may be accomplished with the development of professional partnerships and centres of excellence to improve the functioning of both specialists and to facilitate cross-training.

Prospects: Conventional open-surgical repair remains the safest and most reliable method for managing significant abdominal aneurysms. Endovascular repair is appealing because of shorter hospital stays, less blood loss and significantly reduced intensive care or step-down-unit stays. However, at present it

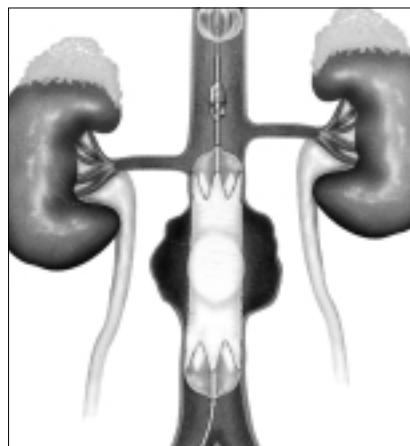
should be considered experimental, to be performed within the confines of clinical trials or in selected patients on compassionate grounds only after they are made aware of the higher failure rate.

Competing interests: None declared.

References

1. Parodi JC, Palmaz JC, Barone HD. Transfemoral intraluminal graft implantation for abdominal aortic aneurysms. *Ann Vasc Surg* 1991;5:491-9.
2. Henretta JP, Hodgson KJ, Mattos MA, Karch LA, Hurlbert SN, Sternbach Y, et al. Feasibility of endovascular repair of abdominal aortic aneurysms with local anesthesia with intravenous sedation. *J Vasc Surg* 1999;29:793-8.
3. May J, White GH, Yu W, Ly CN, Waugh R, Stephen MS, et al. Concurrent comparison of endoluminal versus open repair in the treatment of abdominal aortic aneurysms: analysis of 303 patients by life table method. *J Vasc Surg* 1998;27:213-21.
4. Veith FJ, Abbott WM, Yao JST, Goldstone J, White RA, Abel D, et al. Guidelines for development and use of transluminally placed endovascular prosthetic grafts in the arterial system. *J Vasc Surg* 1995;21:670-85.
5. Cuyper P, Buth J, Harris PL, Gevers E, Lahey R. Realistic expectations for patients with stent-graft treatment of abdominal aortic aneurysms. Results of a European multicentre registry. *Eur J Vasc Endovasc Surg* 1999;17:507-16.

Dr. Kalman is Director at The Toronto General Hospital Vascular Centre and Associate Professor of Surgery at the University of Toronto, Toronto, Ont.



After retrograde passage through the femoral artery the ends of the aortic graft are fixed in position by balloon expansion of the stents.