

# Clinical diagnosis of benign paroxysmal positional vertigo and vestibular neuritis

Peter Johns MD, James Quinn MD

■ Cite as: *CMAJ* 2020 February 24;192:E182-6. doi: 10.1503/cmaj.190334

## Case 1: benign paroxysmal positional vertigo

At 4:00 am, a 71-year-old man turned over in bed onto his left side and experienced a sudden onset of dizziness, described as if the bed was moving. Although lasting only 10–15 seconds, he became sweaty afterwards without nausea or vomiting. He came to the emergency department an hour later. The intense vertigo resolved if he stayed still, but similar brief episodes recurred several times when he laid supine in the hospital. He did not have a headache, neck pain, decreased hearing, paresthesia in his face or limbs, visual field loss, dysarthria, dysphagia, diplopia or dysphonia.

On physical examination, we found no focal weakness, sensory deficit or dysmetria. In the sitting position, he did not have nystagmus while looking straight ahead (spontaneous nystagmus) or when asked to gaze left and then right (gaze-evoked nystagmus). His gait was normal. Because his vertigo was started by head movements and lasted less than a minute and he had no nystagmus, he was a good candidate for positional testing. The patient's right-sided Dix–Hallpike test was normal, without vertigo or nystagmus. However, during testing of the left side and after a brief latency of 2 or 3 seconds, he had vertigo and nystagmus that lasted 15 seconds. The nystagmus was mostly rotatory, with the upper poles of his eyes beating toward his downward left ear. It became more vertical upward when his gaze was directed toward his upward right ear. This was consistent with a diagnosis of left posterior canal benign paroxysmal positional vertigo (BPPV), which can be best managed using the Epley maneuver (an author video showing this patient's Dix–Hallpike test and a demonstration of the Epley maneuver is available at <https://youtu.be/kvVnEsGVLUY>).

Fifteen minutes after completion of the Epley maneuver, repeat Dix–Hallpike testing of the patient's left ear found no vertigo or nystagmus. Given his clinical presentation and his favourable response to the Epley maneuver, we discharged the patient home with no medication. A follow-up telephone interview 2 weeks after the patient presented to the emergency department determined that he had not had any further dizzy episodes.

## KEY POINTS

- Assess patients with vertigo for focal neurologic signs and symptoms, sustained substantial headache or neck pain, inability to stand and spontaneous vertical nystagmus.
- Perform the Dix–Hallpike test only for patients with episodes of vertigo less than 2 minutes and no nystagmus at rest.
- Perform the head impulse, nystagmus and test of skew (HINTS) plus (plus refers to a test of recent hearing loss) examination only for patients with hours or days of constant, ongoing vertigo and nystagmus at rest.

## Case 2: vestibular neuritis

A 49-year-old man presented to the emergency department with an ongoing, constant spinning sensation for 12 hours that was accompanied by multiple bouts of vomiting. The vertigo persisted to a substantial degree even when the patient remained still, and it worsened with movements such as going from lying down to upright or rapid head turning. He was able to walk unaided but felt unsteady. It was difficult for him to perform tandem gait. He reported that he did not have headache, neck pain or ear symptoms. He also reported that he did not have face or limb paresthesia, focal weakness, dysarthria, dysphagia, diplopia or dysphonia.

On physical examination, we found no motor weakness or dysmetria. We did not observe any vertical nystagmus. Our differential diagnosis was a posterior circulation stroke versus vestibular neuritis, and to differentiate them, we used a clinical examination known as “HINTS plus” (head impulse, nystagmus and test of skew. The term plus refers to a test of recent hearing loss.)

The HINTS plus examination is a series of 4 bedside tests: the type of nystagmus seen, test of skew, head impulse test and a test of hearing.<sup>1</sup> Each component of this examination can point to a peripheral or central cause for vertigo. If all 4 results point to a peripheral cause, the overall HINTS plus examination is deemed “HINTS plus peripheral,” and suggests the patient likely has vestibular neuritis. If any of the results are central, the overall result for HINTS plus is deemed “HINTS plus central,” and further

workup for stroke is warranted. Based on a study involving 190 patients who presented for emergency medical care with vertigo and nystagmus, the sensitivity and specificity of the HINTS plus examination for identifying a central cause of vertigo was reported as 99% and 97%, respectively.<sup>2</sup> The HINTS plus examination should only be conducted for patients with constant ongoing vertigo and spontaneous or gaze-evoked nystagmus. It should not be conducted for patients with transient, brief episodes of vertigo, such as in Case 1, or in patients who do not have spontaneous or gaze-evoked nystagmus.<sup>2</sup>

The patient in Case 2 had spontaneous left horizontal and slightly rotational nystagmus toward the left ear. The nystagmus increased in amplitude when he looked left. When he looked right, it decreased in intensity but with the fast component still beating toward the left. This type of nystagmus is typical for right vestibular neuritis.<sup>3</sup> It is also called unidirectional nystagmus. Results for the patient's test of skew showed that he had no vertical skew deviation. The result for his head impulse test was normal when his head was turned rapidly to the left, but there was a distinct catch-up saccade seen when his head was quickly turned to the right (an author video showing how to perform and interpret the HINTS plus examination and findings for the patient in Case 2 is available at <https://youtu.be/dy6FsKS0LHY>).

The patient was able to detect the sound of fingers rubbing beside both his ears, suggesting there was no gross hearing loss.

Taken together, the clinical findings for this patient were consistent with a diagnosis of vestibular neuritis. We advised that he use dimenhydrinate (an over-the-counter antiemetic medication) for the next 3 days as needed for nausea or vomiting. His vertigo improved substantially over the next 2 days, and he recovered completely in 1 week.

## Discussion

Vertigo is defined as a false or distorted sensation of movement.<sup>4</sup> Box 1 presents a comparison of BPPV, vestibular neuritis and cerebellar stroke using important clinical features of each diagnosis, and shows which bedside testing is appropriate, and the characteristic diagnostic findings of bedside testing in these conditions.

Posterior circulation stroke syndromes include transient ischemic attack (TIA), ischemic and hemorrhagic stroke, and vertebral artery dissection. Hemorrhagic cerebellar stroke and vertebral artery dissection commonly present with substantial new and sustained headache or neck pain, respectively.

There are 2 common presentations of peripheral vertigo that can often be diagnosed using bedside testing.

### Box 1: Clinical presentation and guide to bedside testing for benign paroxysmal positional vertigo, vestibular neuritis and cerebellar stroke

Symptom	BPPV	Vestibular neuritis	Cerebellar stroke
Vertigo when patient is still	No	Yes	Yes
Patient is able to stand unaided	Yes	Yes	May not be able to
Spontaneous and/or gaze-evoked nystagmus	No	Yes	Yes
Typical spontaneous or gaze-evoked nystagmus observed	Not present	Unidirectional horizontal/rotatory Not purely vertical	Various, including bidirectional horizontal/rotatory; sometimes vertical
Worse when patient moves their head	Yes	Yes	Yes
Other neurologic symptoms or findings	No	No	Often but not always present
New hearing loss	No	No	Can occur
Appropriate to perform Dix–Hallpike test	Yes	No	No
Nystagmus produced during Dix–Hallpike test	Vertical upward and rotatory	Do not perform Dix–Hallpike test	Do not perform Dix–Hallpike test
Appropriate to perform HINTS plus examination	No	Yes	Yes
Results from HINTS plus examination	Do not perform HINTS plus testing	All 4 findings: Unidirectional nystagmus No vertical skew Abnormal HIT No hearing loss HINTS plus = peripheral	Any of: Bidirectional nystagmus Vertical skew present Normal HIT New hearing loss HINTS plus = central
Imaging indicated	No	No	Yes
Primary treatment	Epley maneuver	Supportive treatment	Treatment for stroke

Note: BPPV = benign paroxysmal positional vertigo, HINTS = head impulse, nystagmus and test of skew, with plus referring to a test of recent hearing loss, HIT = head impulse test. With permission from Tintinalli JE, Ma OJ, Yealy DM, et al. *Tintinalli's emergency medicine: a comprehensive study guide, 9th edition*. New York: McGraw Hill; 2020.

## Benign paroxysmal positional vertigo

Benign paroxysmal positional vertigo is the most common cause of vertigo.<sup>5</sup> It is characterized by brief (typically 20–30 s and < 2 min) episodes of vertigo started by changes in head position such as getting in or out of bed, turning over in bed, bending forward or tilting the head backward. If the patient remains still, the intense vertigo sensation ceases. Although older adults are most frequently affected, it can occur in all ages including the pediatric population. Most commonly, it occurs spontaneously but can also be seen after a head injury or shortly after an episode of vestibular neuritis. Particles normally found in the utricle find their way into the semicircular canals and, with head movement, move within the canals producing vertigo. Benign paroxysmal positional vertigo is easily treated using particle-repositioning maneuvers such as the Epley maneuver.<sup>5,6</sup>

A patient with BPPV has no spontaneous or gaze-evoked nystagmus. The Dix–Hallpike test is considered the gold standard for confirming a diagnosis of the most common type of this condition, posterior canal BPPV.<sup>5–7</sup> Additional testing is not required in patients with the typical presentation and nystagmus diagnostic of BPPV.<sup>6,8</sup>

Emergency physicians have been interviewed about the challenges they face with patients who have BPPV.<sup>9</sup> Factors that they identified as barriers were forgetting how to perform the Dix–Hallpike test and Epley maneuver, and misattributing vertical upward and rotatory nystagmus as found in BPPV using the Dix–Hallpike test as indicating a central cause of vertigo. Vertical nystagmus is only suggestive of a central cause when it occurs spontaneously and not during positional testing such as the Dix–Hallpike test.<sup>3</sup>

## Vestibular neuritis

The most commonly seen cause of substantial continuous dizziness or vertigo and spontaneous nystagmus is vestibular neuritis. Vestibular neuritis and cerebellar stroke can both present with hours to days of ongoing, constant vertigo, spontaneous or gaze-evoked nystagmus, nausea or vomiting and difficulty walking. Head movement will briefly exacerbate the patient's symptoms in both vestibular neuritis and cerebellar stroke. This clinical presentation should be distinguished from the 20–30 second episodes of vertigo started by getting in or out or rolling over in bed, which are typical of BPPV.

Vestibular neuritis is usually a benign, self-limited condition, whereas a cerebellar stroke presenting as vertigo with only subtle neurologic findings is a feared cause of vertigo. If it is not recognized, the patient may be sent home only to deteriorate in the next few days leading to poor outcomes or even death. The fear of this uncommon occurrence may contribute to excess imaging performed for patients with a benign cause of vertigo.<sup>10</sup>

Vestibular neuritis is more common than cerebellar stroke and can be reliably identified using the HINTS plus examination.<sup>1</sup>

Thus, vestibular neuritis, cerebellar stroke and BPPV can often be diagnosed by combining a clinical history with bedside testing.<sup>5</sup> By ruling in a benign cause of vertigo such as BPPV or vestibular neuritis, dangerous causes of vertigo are effectively ruled out.<sup>3</sup> This may decrease the use of diagnostic imaging as well as time spent by the patient being evaluated.

The most appropriate bedside testing for a patient will depend on the patient's clinical presentation. The HINTS plus examination should only be conducted for patients with ongoing vertigo and spontaneous nystagmus. The Dix–Hallpike test should be conducted only for patients with short episodes of vertigo who do not have spontaneous or gaze-evoked nystagmus.<sup>2,4</sup>

## Screening for central features

Using the central portion of Figure 1, clinicians can screen for neurologic symptoms and deficits from stroke syndromes such as cerebellar stroke, TIA, cerebellar hemorrhage and vertebral artery dissection. If a patient screens positive for any of these findings, they should undergo neuroimaging and referral to specialist care.

If a patient screens negative for central features, clinicians should perform additional bedside testing based on the left or right arm of the flow chart (Figure 1).

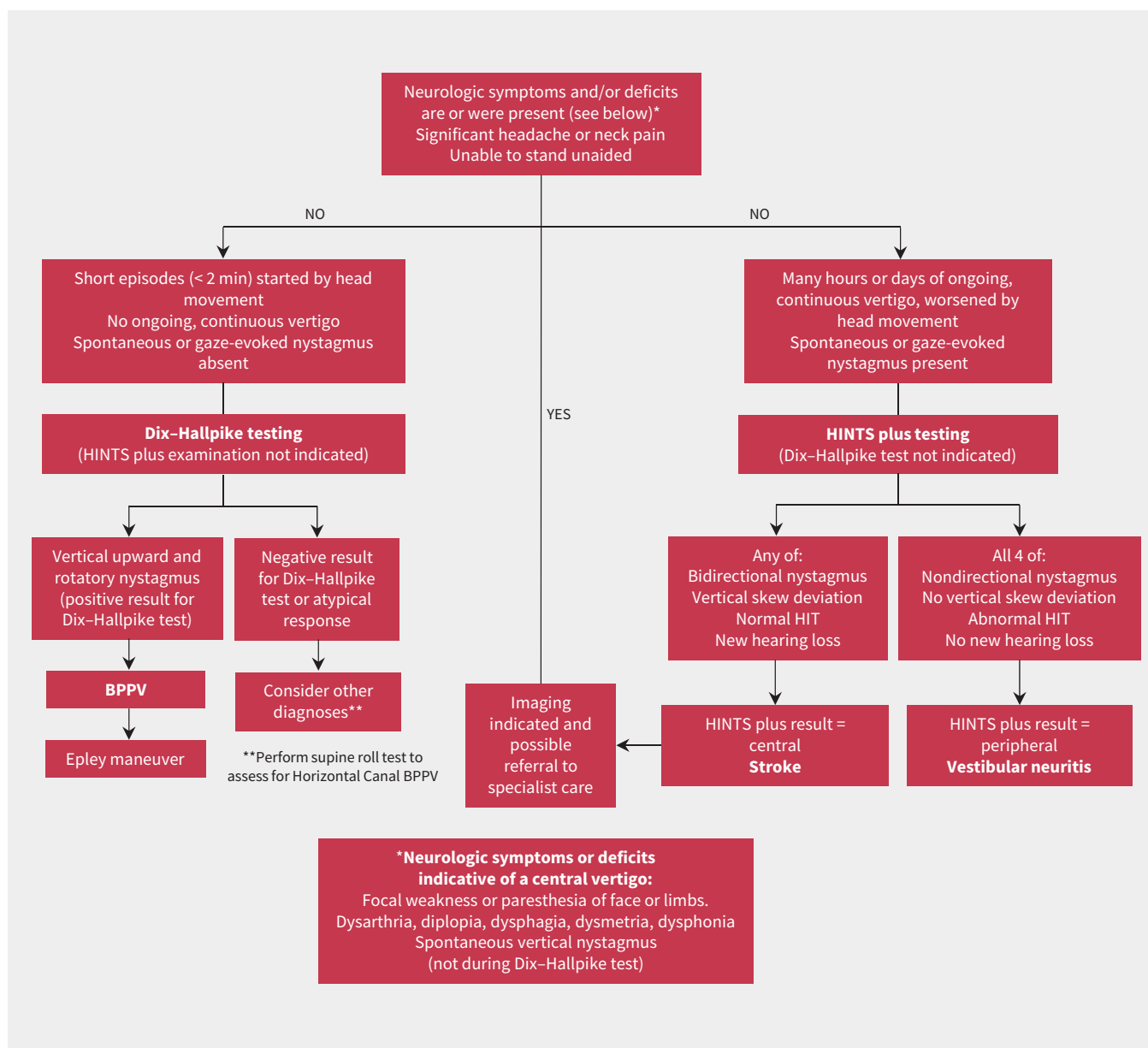
## Short episodes of vertigo started by head movement and no spontaneous nystagmus

The left arm of the flow chart in Figure 1 is used for patients who have episodes of vertigo that are less than 2 minutes long and started by head movement, and who are not having substantial constant vertigo or spontaneous or gaze-evoked nystagmus. These patients should have the Dix–Hallpike test. If the patient has a positive Dix–Hallpike test with vertical upward or rotatory nystagmus, the diagnosis of posterior canal BPPV is supported, and the Epley maneuver can be performed to resolve the patient's symptoms within minutes.<sup>5</sup> As seen in the author video, the nystagmus during the Dix–Hallpike test becomes more rotatory when the patient looks toward their downward ear and more vertical upward when they look toward their upward ear.<sup>8</sup> Posterior canal BPPV is the most common and easily treated type of BPPV. Although contraindicated in patients with known neck instability, the Dix–Hallpike test and Epley maneuver are safe and effective.<sup>7</sup>

Should the presentation be consistent with BPPV but with negative results on both sides for the Dix–Hallpike test or purely horizontal nystagmus is seen during this test, then the supine roll test should be performed to determine if the patient has horizontal canal BPPV (an author video explaining how to diagnose and treat horizontal canal BPPV is available at <https://youtu.be/VRjRTnlw9YE>).<sup>7</sup> Horizontal canal BPPV spontaneously resolves more quickly than the posterior canal type and may be present in up to a third of patients with BPPV.<sup>6,11</sup> Horizontal canal BPPV will not respond to the Epley maneuver, but other maneuvers can be used to successfully treat this condition.<sup>5</sup>

## Constant episodes of vertigo and spontaneous nystagmus

The right arm of the flow chart in Figure 1 is used for patients with hours or days of clinically significant ongoing and continuous vertigo that is worsened by head movement, whose examination shows spontaneous or gaze-evoked nystagmus. These patients should undergo HINTS plus examination. If any component of the HINTS plus examination points to a central result, the patient



**Figure 1:** Flow chart of the initial approach to the diagnosis of acute vertigo. With permission from Tintinalli JE, Ma OJ, Yealy DM, et al. *Tintinalli's emergency medicine: a comprehensive study guide, 9th edition*. New York: McGraw Hill; 2020. Note: BPPV = benign paroxysmal positional vertigo; HINTS plus = head impulse, nystagmus and test of skew, with plus referring to a test of recent hearing loss; HIT = head impulse test.

requires neuroimaging and possible treatment, which may include secondary prevention of posterior circulation stroke. If the patient shows peripheral results for all 4 components of the examination, as in Case 2, then the patient may be considered for discharge with a diagnosis of vestibular neuritis without imaging being performed. A 2011 Cochrane systematic review found that there was insufficient evidence to support the use of steroids for vestibular neuritis.<sup>12</sup> Shared decision-making with the patient may be the best approach to steroid treatment. Vestibular rehabilitation can be useful to assist in a patient's recovery from vestibular neuritis.

There are many other disorders that cause dizziness or vertigo that will not be identified by this approach. Serious but

### Box 2: Other causes of vertigo

#### Ménière disease

- Recurrent episodes, hearing loss, tinnitus, ear fullness

#### Vestibular migraine

- Recurrent episodes of vertigo lasting minutes to days. At least 50% of episodes have 1 of photophobia, phonophobia, migraine headache or visual aura.

#### Labyrinthitis

- Similar to vestibular neuritis but with decreased hearing or tinnitus

uncommon general medical conditions that can cause vertigo, such as encephalitis or Wernicke encephalopathy, usually present with other findings that mandate a broader differential and workup.<sup>13</sup>

Most other isolated vertigo disorders do not require emergent workup. Patients with acute hearing loss, if they are determined to have not had an anterior inferior cerebellar artery stroke, should be referred to otolaryngology or consideration of treatment with corticosteroids. Other patients not fitting into this diagnostic approach can be referred to vertigo specialists for further evaluation and treatment. Selected other causes of vertigo are identified in Box 2.

## Conclusion

With a typical clinical presentation, patients with BPPV can be diagnosed when the characteristic nystagmus on positional testing is seen. Patients with vestibular neuritis can be differentiated from those with cerebellar stroke with the HINTS plus examination. By reliably diagnosing patients with vertigo using history, physical and appropriately targeted bedside examination techniques, patients can often avoid unnecessary imaging.

## References

1. Newman-Toker DE, Kerber KA, Hsieh Y, et al. HINTS outperforms ABCD2 to screen for stroke in acute continuous vertigo and dizziness. *Acad Emerg Med* 2013;20:986-96.
2. Edlow JA, Newman-Toker DE. Using the physical examination to diagnose patients with acute dizziness and vertigo. *J Emerg Med* 2016;50:617-28.
3. Edlow JA, Gurley KL, Newman-Toker DE. A new diagnostic approach to the adult patient with acute dizziness. *J Emerg Med* 2018;54:469-83.
4. Tarnutzer AA, Berkowitz AL, Robinson KA, et al. Does my dizzy patient have a stroke? A systematic review of bedside diagnosis in acute vestibular syndrome. *CMAJ* 2011;183:E571-92.
5. Kim JS, Zee DS. Benign paroxysmal positional vertigo. *N Engl J Med* 2014;370:1138-47.
6. Parnes LS, Agrawal SK, Atlas J. Diagnosis and management of benign paroxysmal positional vertigo (BPPV). *CMAJ* 2003;169:681-93.
7. Bhattacharyya N, Gubbels SP, Schwartz SR, et al. Clinical practice guideline: benign paroxysmal positional vertigo (update). *Otolaryngol Head Neck Surg* 2017;156(3S):S1-47.
8. von Brevern M, Bertholon P, Brandt T. Benign paroxysmal positional vertigo: diagnostic criteria. *J Vestib Res* 2015;25:105-17.
9. Kerber KA, Forman J, Damschroder L, et al. Barriers and facilitators to ED physician use of the test and treatment of BPPV. *Neurol Clin Pract* 2017;7:214-24.
10. Grill E, Strupp M, Muller M, et al. Health services utilization of patients with vertigo in primary care: a retrospective cohort study. *J Neurol* 2014;261:1492-8.
11. Messina A, Casani AP, Manfrin M, et al. Italian survey of benign paroxysmal positional vertigo. *Acta Otorhinolaryngol Ital* 2017;37:328-35.
12. Fishman JM, Burgess C, Waddell A. Corticosteroids for the treatment of idiopathic acute vestibular dysfunction (vestibular neuritis). *Cochrane Database Syst Rev* 2011;(5):CD008607.
13. Edlow JA. Diagnosing patients with acute-onset persistent dizziness. *Ann Emerg Med* 2018;71:625-31.

**Competing interests:** None declared.

This article has been peer reviewed.

The authors have obtained patient consent.

**Affiliations:** Department of Emergency Medicine (Johns), University of Ottawa, Ottawa, Ont.; Department of Emergency Medicine (Quinn), Stanford University, Stanford, Calif.

**Contributors:** Both authors contributed to the conception and design of the work, drafted the work and revised it critically for important intellectual content, gave final approval of the version to be published and agreed to be accountable for all aspects of the work.

**Correspondence to:** Peter Johns, pjohns@toh.ca



Author videos showing the Dix-Hallpike test and the Epley maneuver, showing how to perform and interpret the HINTS plus examination, and explaining how to diagnose and treat horizontal canal benign paroxysmal positional vertigo are available at <https://youtu.be/kvVnEsGVLUY>, <https://youtu.be/dy6FsKS0LHY> and <https://youtu.be/VRjRTnlw9YE>, respectively

The section Cases presents brief case reports that convey clear, practical lessons. Preference is given to common presentations of important rare conditions, and important unusual presentations of common problems. Articles start with a case presentation (500 words maximum), and a discussion of the underlying condition follows (1000 words maximum). Visual elements (e.g., tables of the differential diagnosis, clinical features or diagnostic approach) are encouraged. Consent from patients for publication of their story is a necessity. See information for authors at [www.cmaj.ca](http://www.cmaj.ca).